



Je suis illustratrice spécialisée dans le domaine médical depuis 1997, année de l'obtention de mon Diplôme Supérieur d'Arts Appliqués en Illustration (École Estienne et Faculté de Médecine du CHU Pitié Salpêtrière).

Mon travail consiste à créer des images didactiques à partir de documents (croquis, photos, textes...) souvent complexes, dans les thèmes médicaux tels que l'anatomie, la chirurgie, les pathologies, la biologie cellulaire. Je dois avant tout bien comprendre et analyser la demande du client pour ensuite la traduire et la synthétiser sous une forme graphique juste et attrayante.

J'exerce en profession libérale et crée des illustrations pour des éditeurs, des médecins, des agences de communication santé et des laboratoires pharmaceutiques.

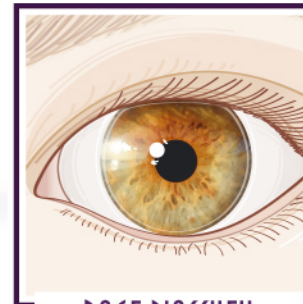


@CONTACT

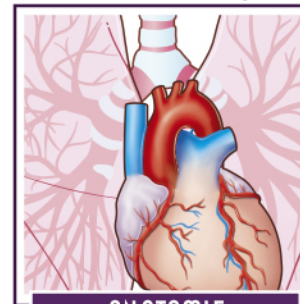
PLAQUETTE

BOOK EN LIGNE

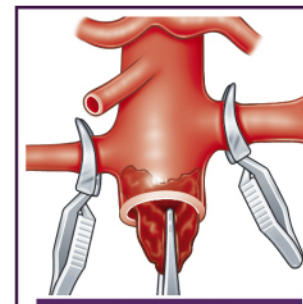
# ILLUSTRATION MÉDICALE & SCIENTIFIQUE



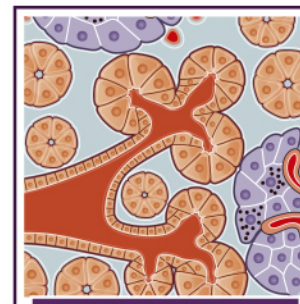
PAGE D'ACCUEIL



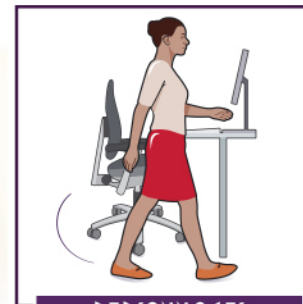
ANATOMIE



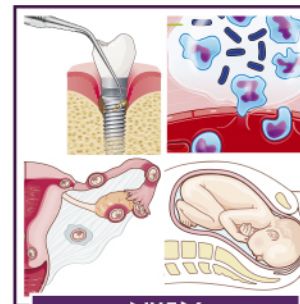
CHIRURGIE



MICROSCOPIE



PERSONNAGES



DIVERS

CAROLE FUMAT

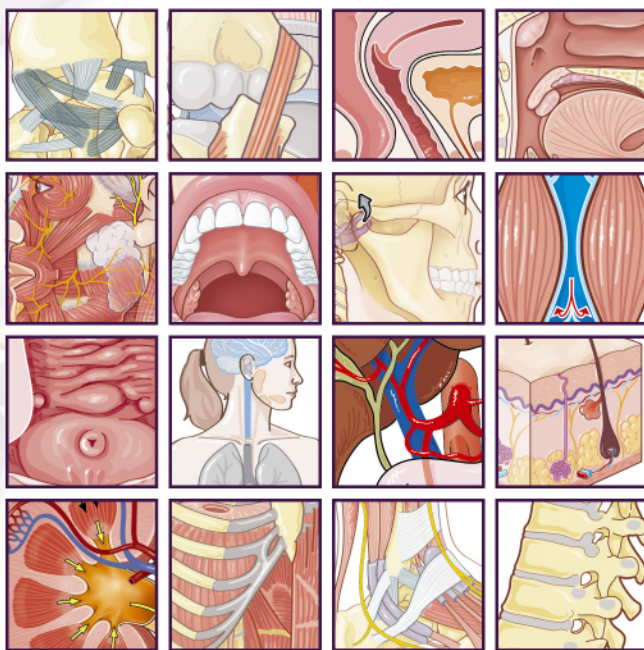
01.46.58.79.28

06.03.11.08.27

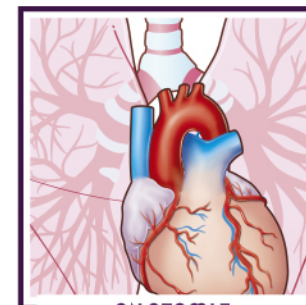
c.fumat@wanadoo.fr

Dernière révision du site en janvier 2023

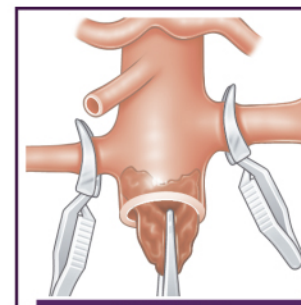
# ANATOMIE



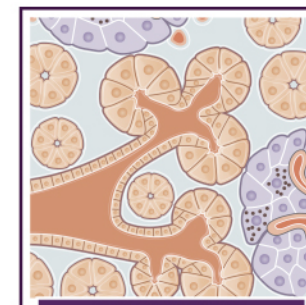
PAGE D'ACCUEIL



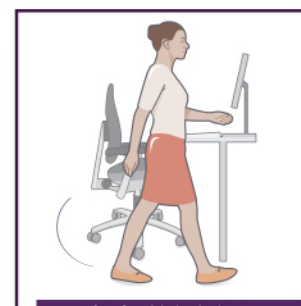
ANATOMIE



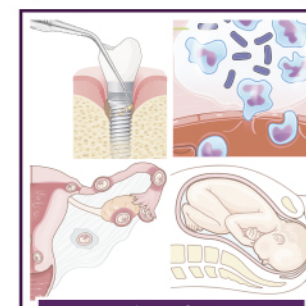
CHIRURGIE



MICROSCOPIE

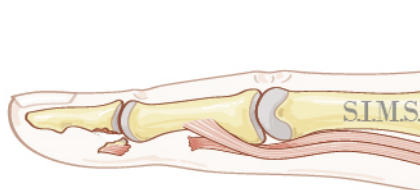
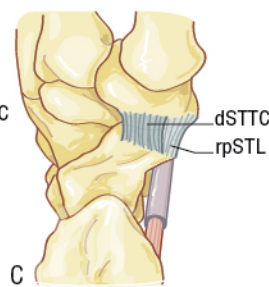
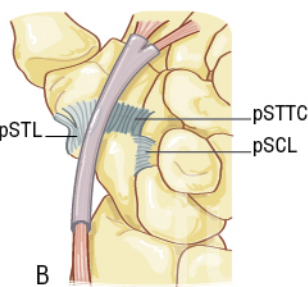
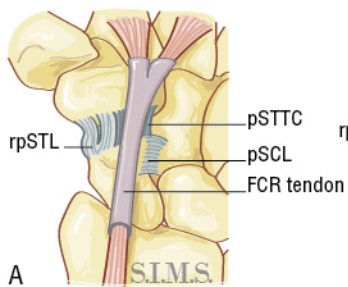
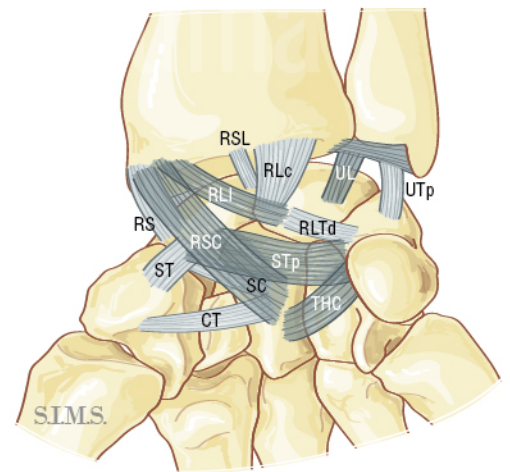
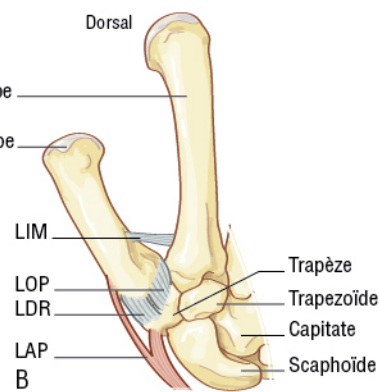
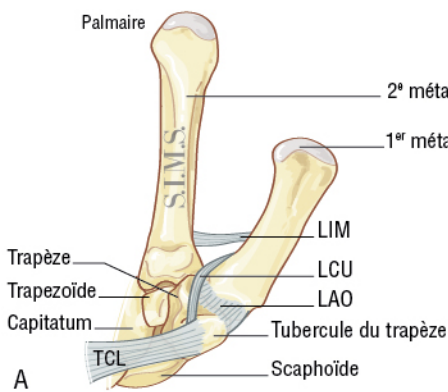
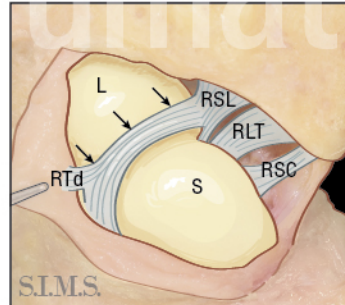
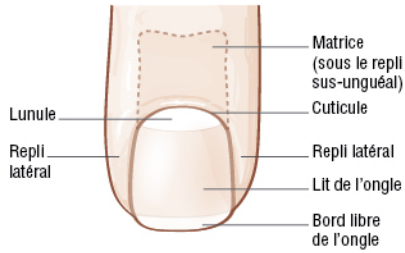
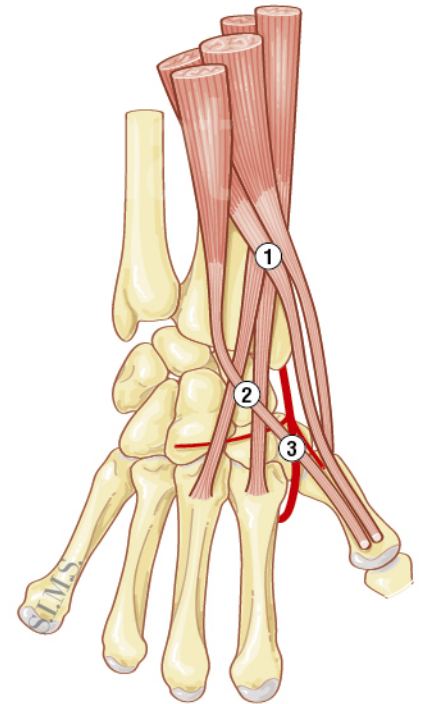
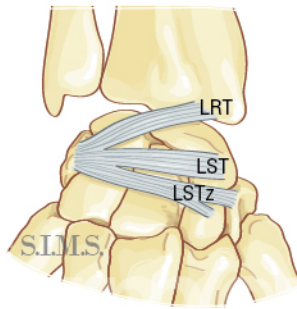
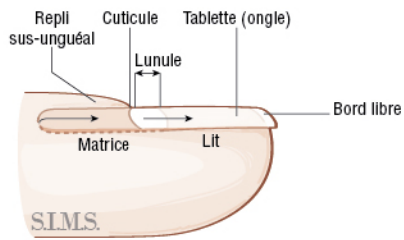


PERSONNAGES

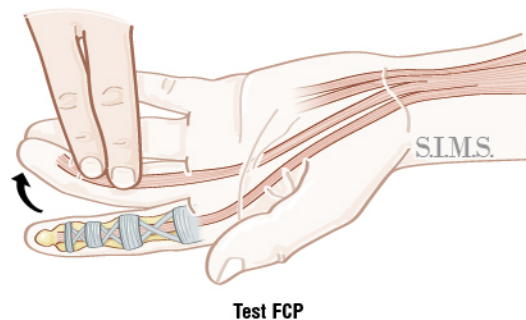


DIVERS

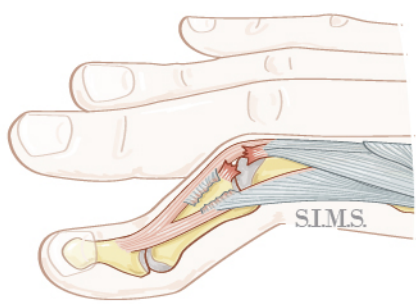




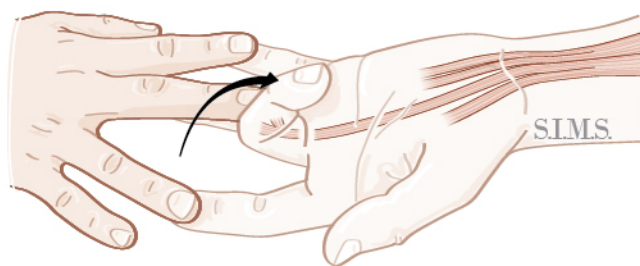
Jersey finger  
Type 4 (type 1 + type 2)



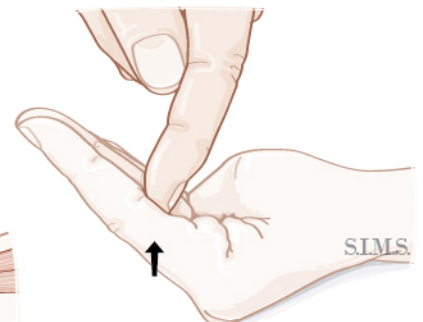
Test FCP



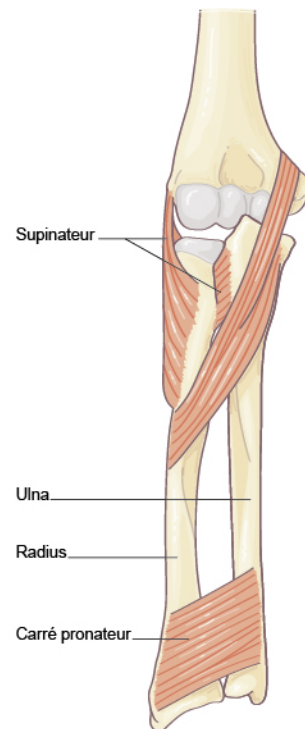
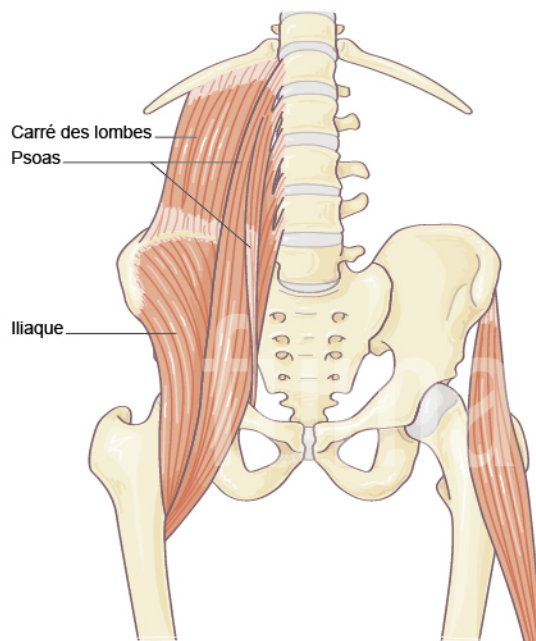
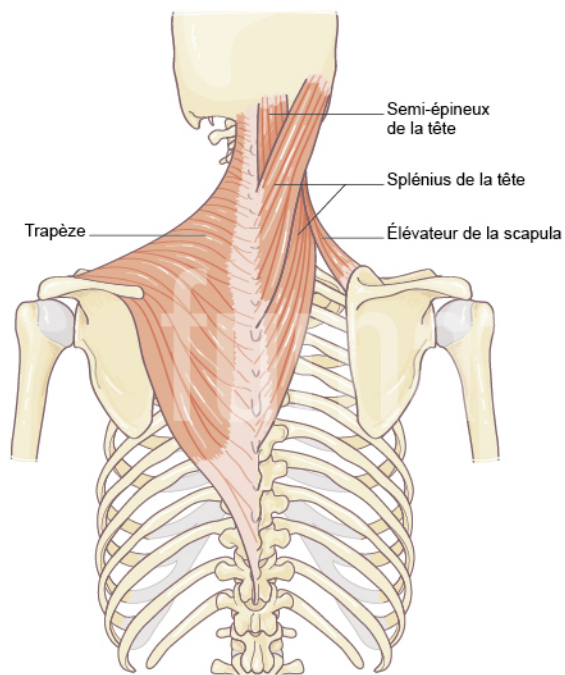
Boutonnière



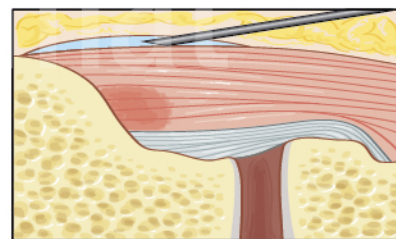
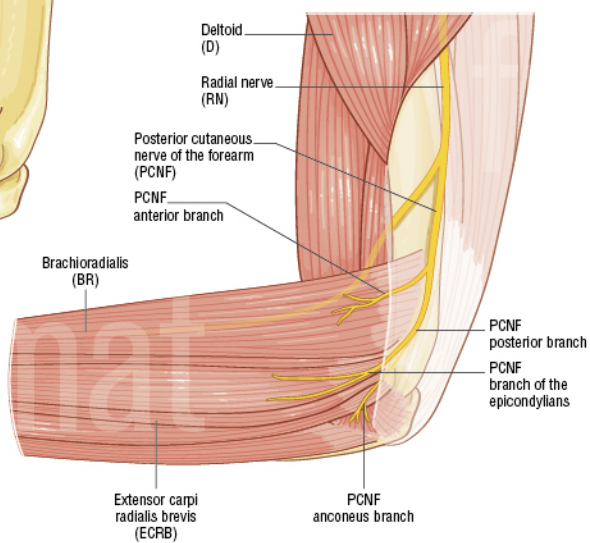
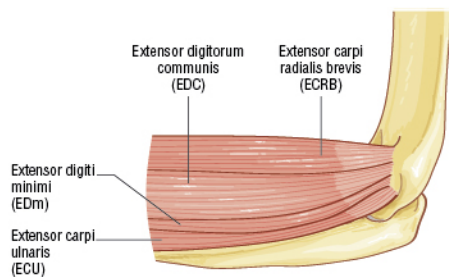
Test FCS



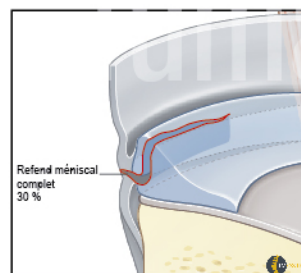
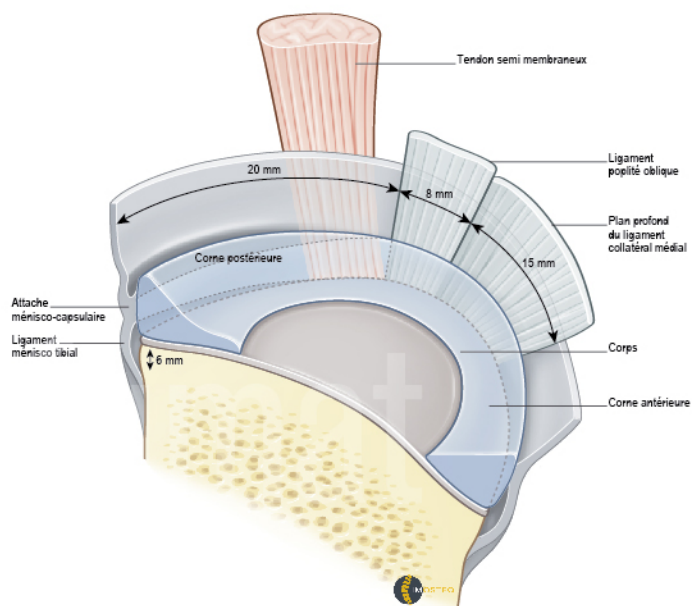
Testing des muscles lombricaux



INSEP

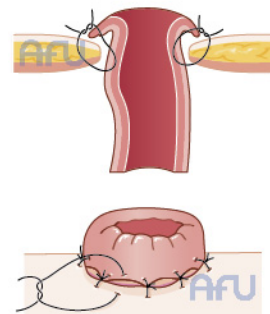
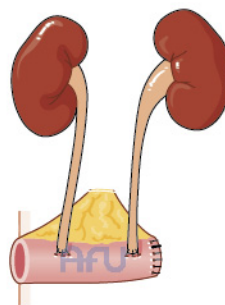
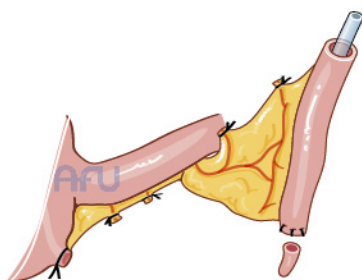
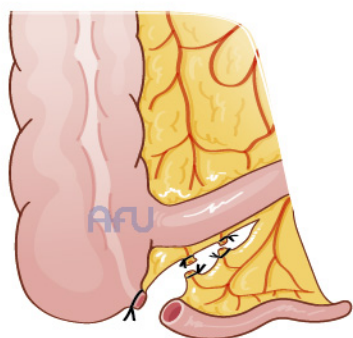
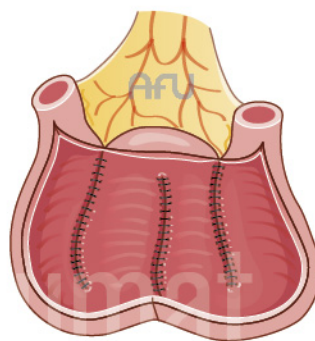
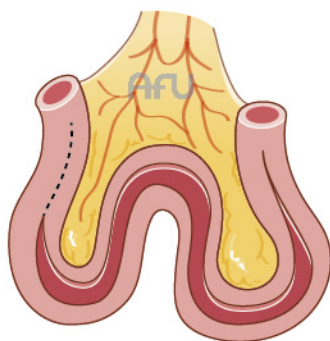
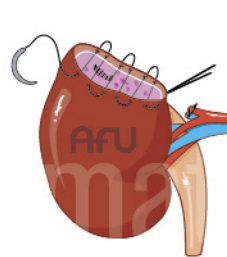
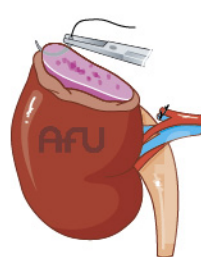
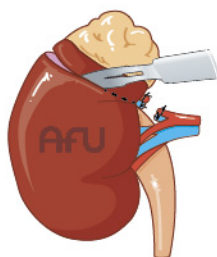
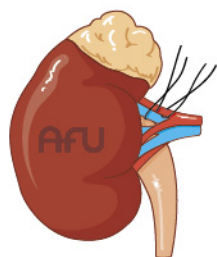
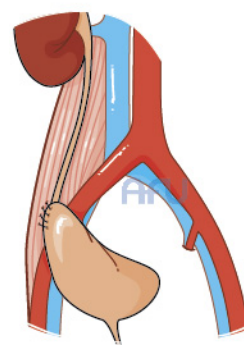
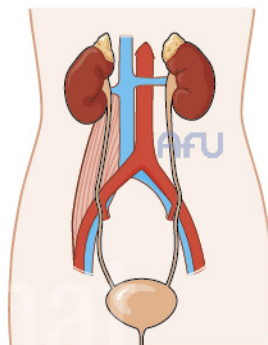
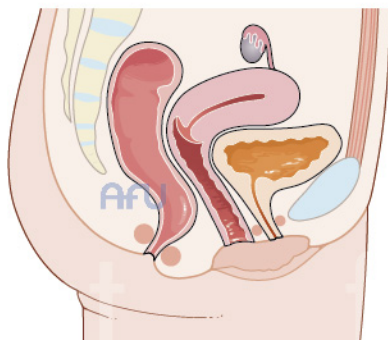
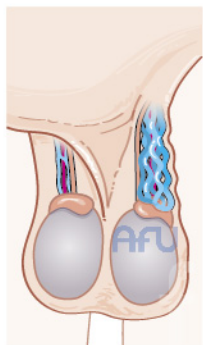
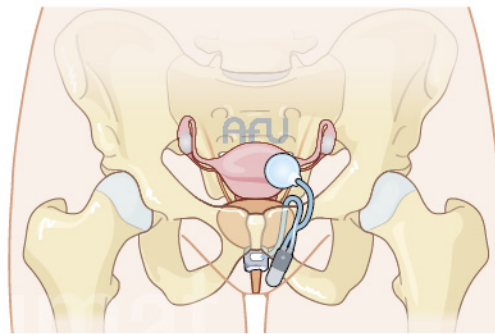
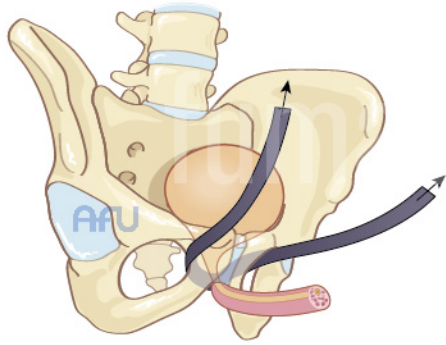
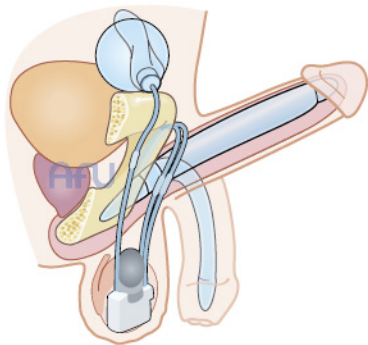


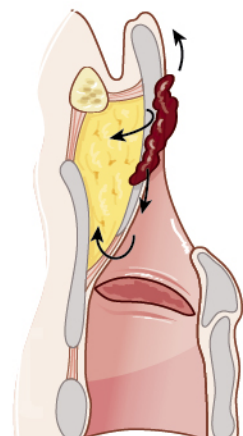
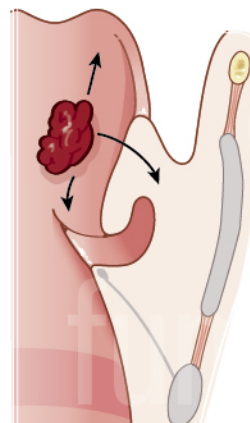
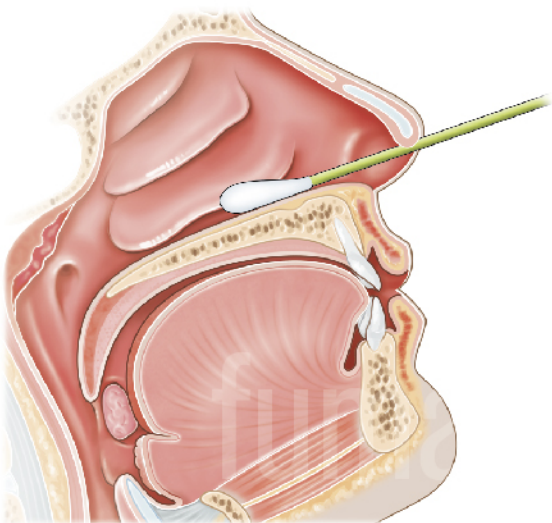
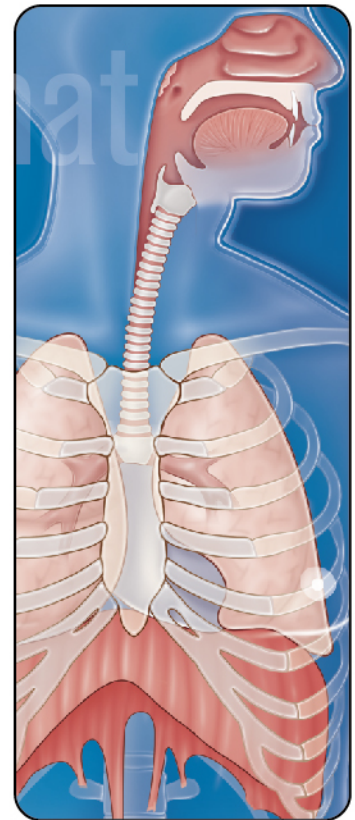
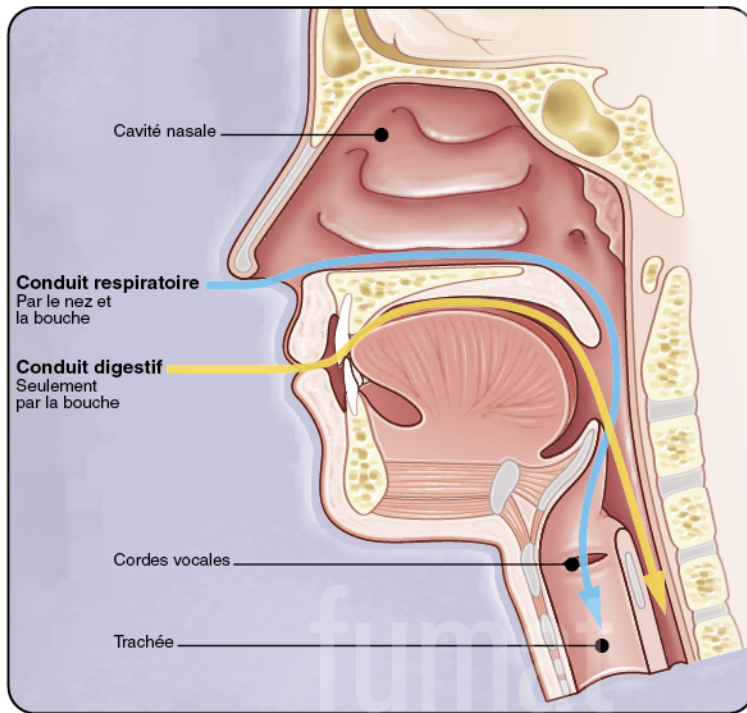
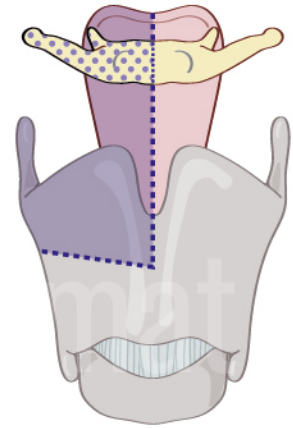
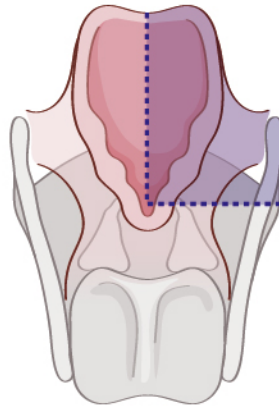
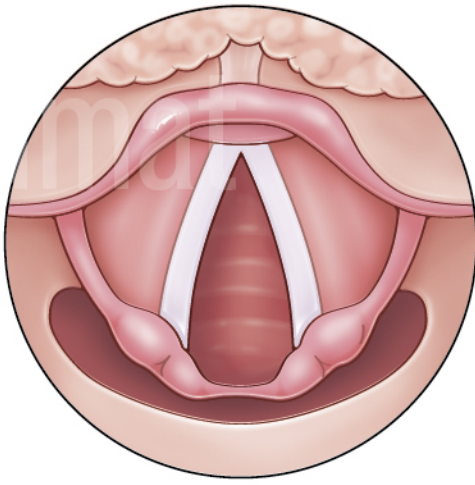
Dr Meyer



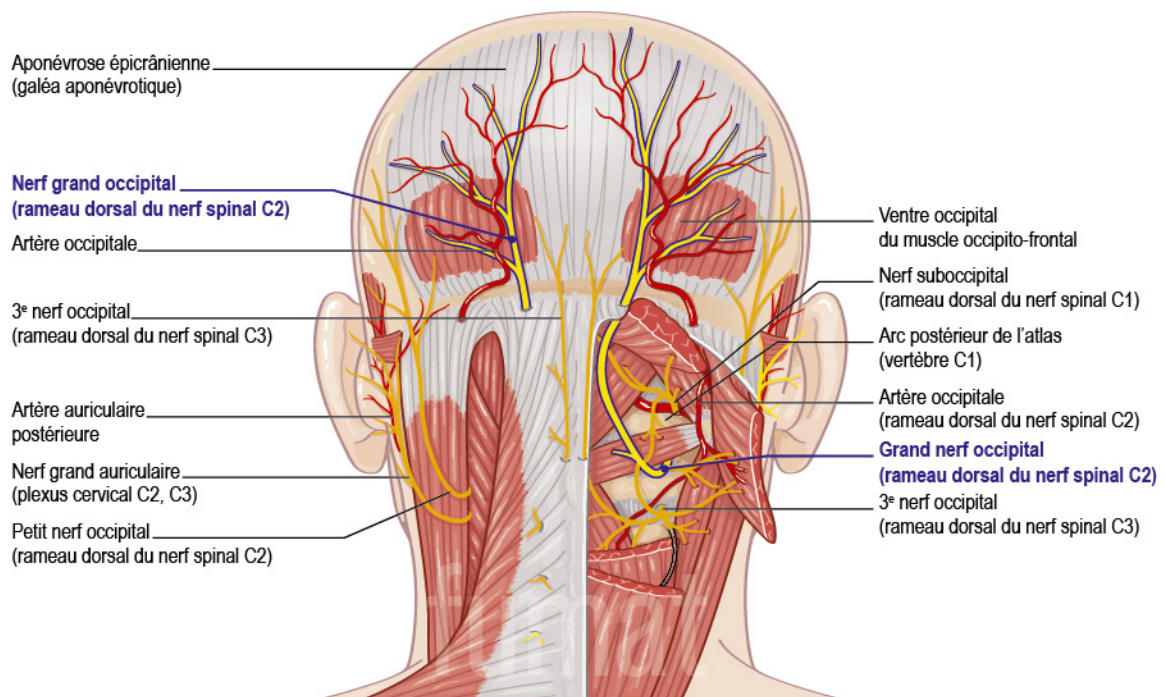
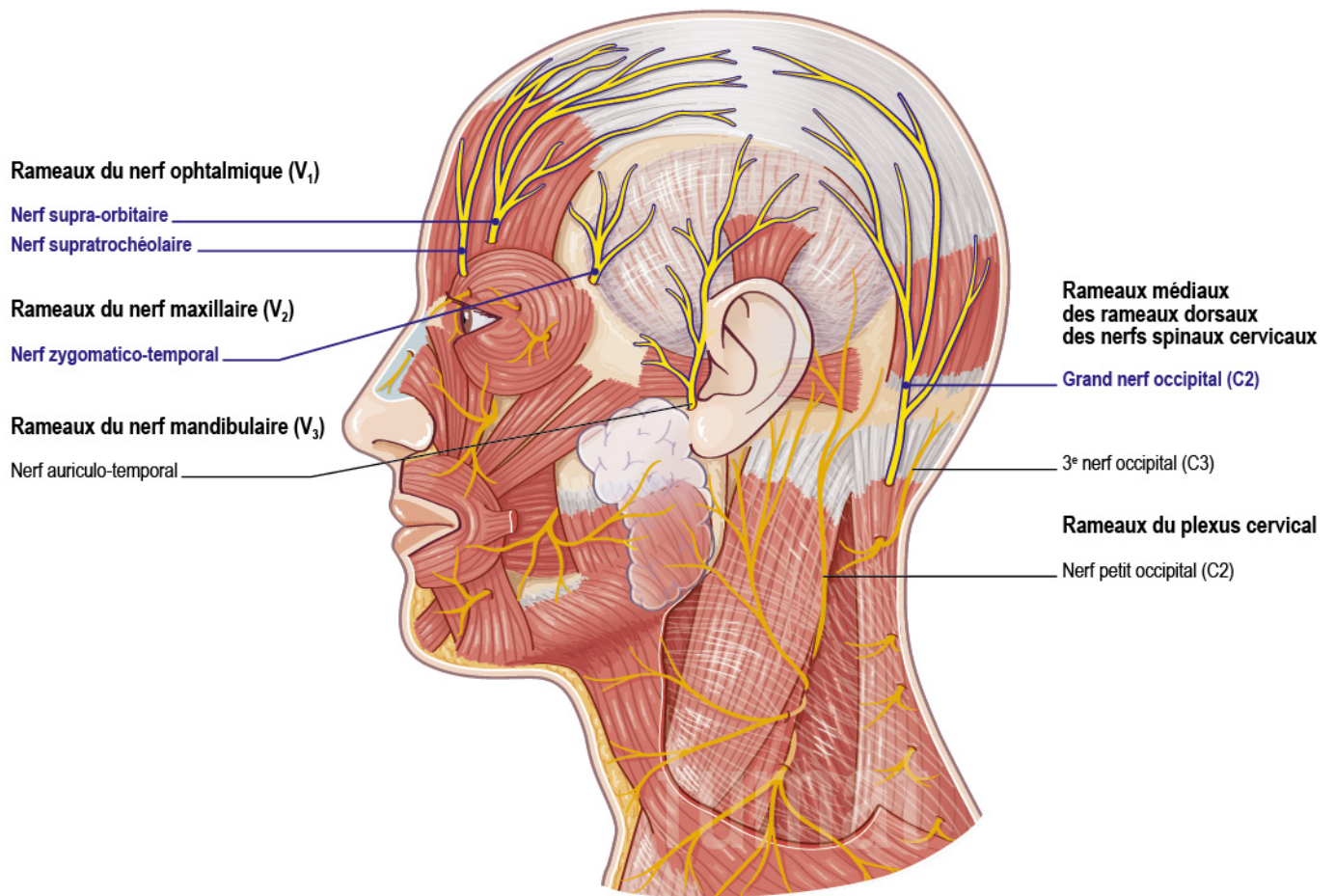
Dr Guillin - IMOSTEO

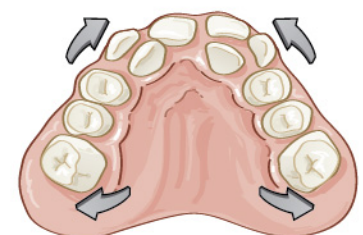
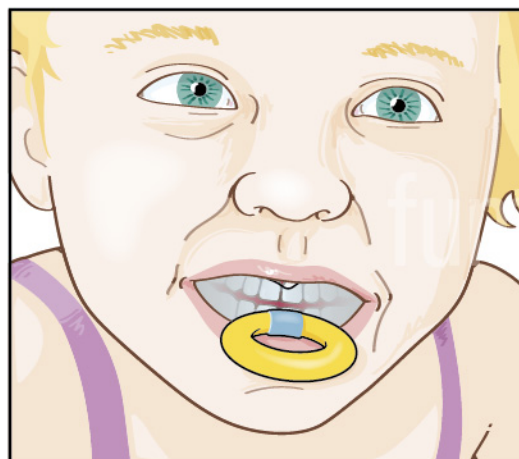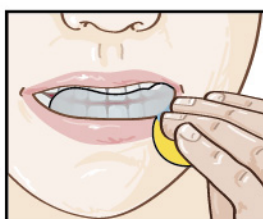
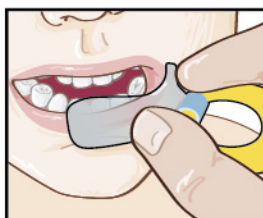
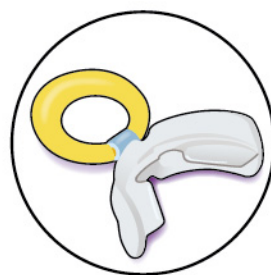
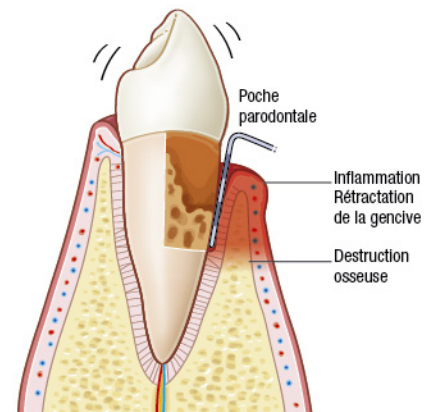
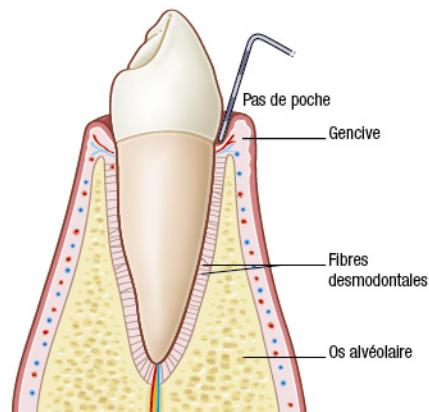
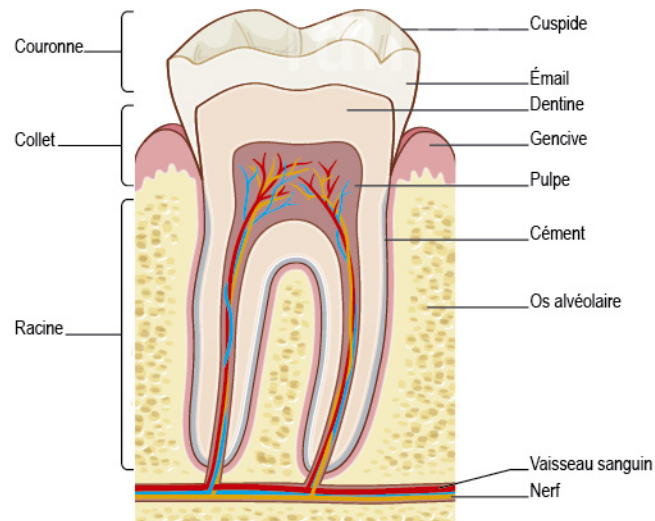
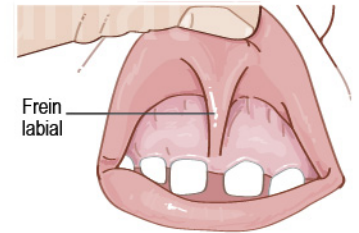
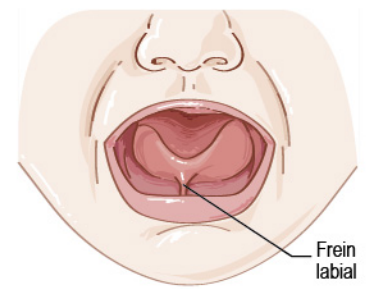
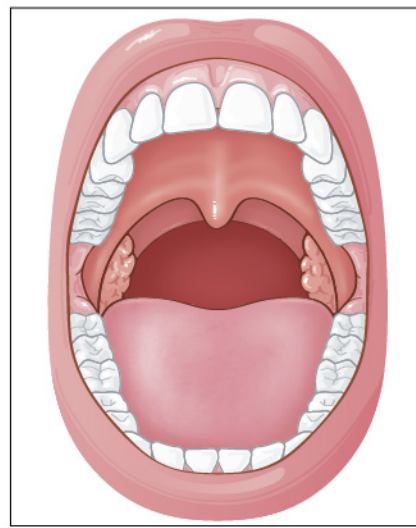
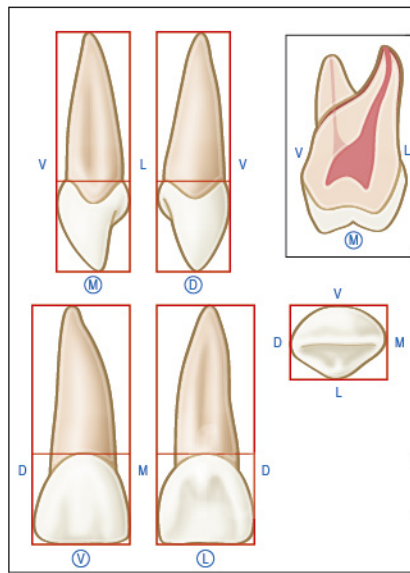




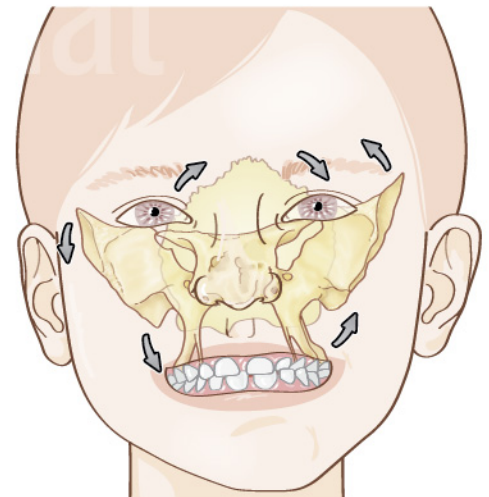
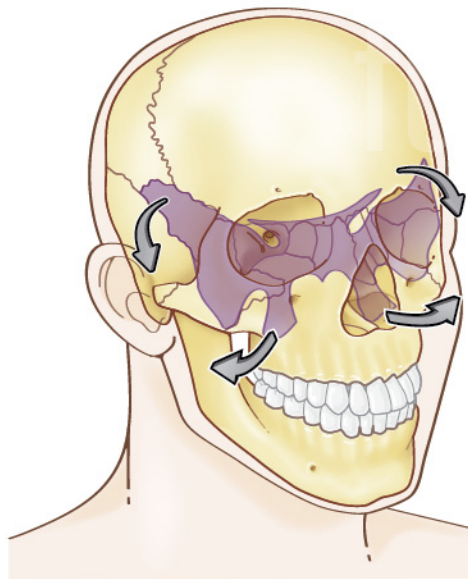
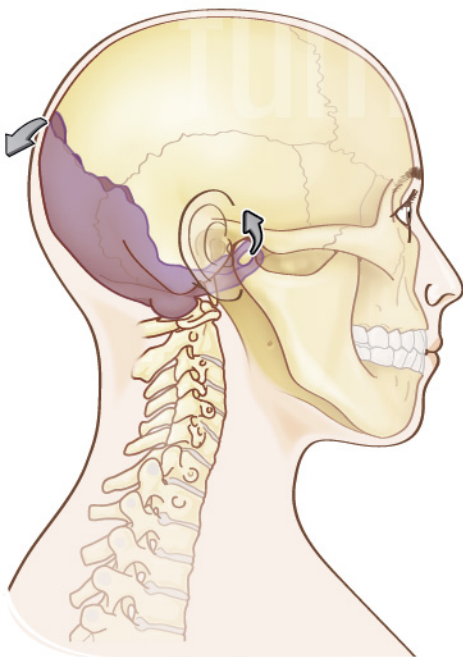
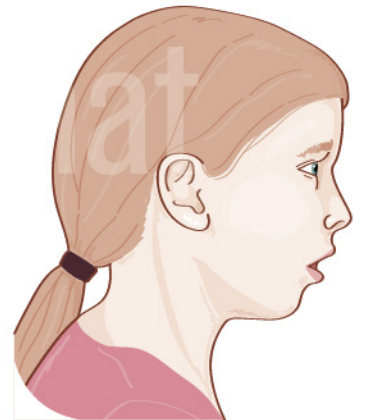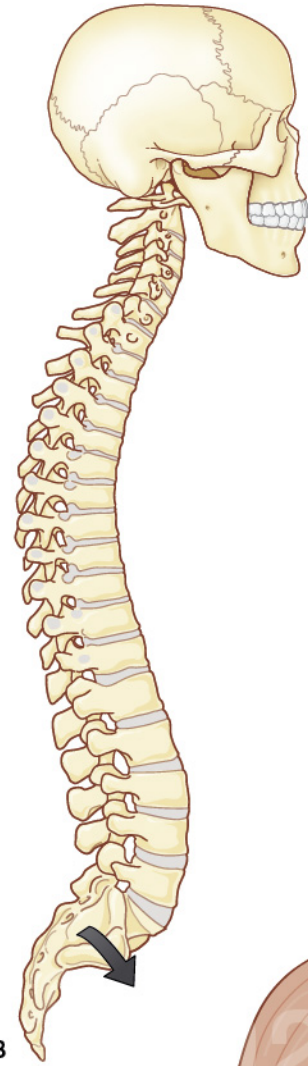
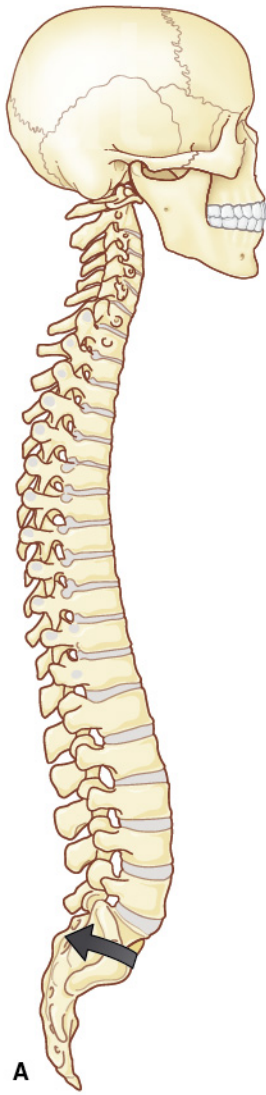
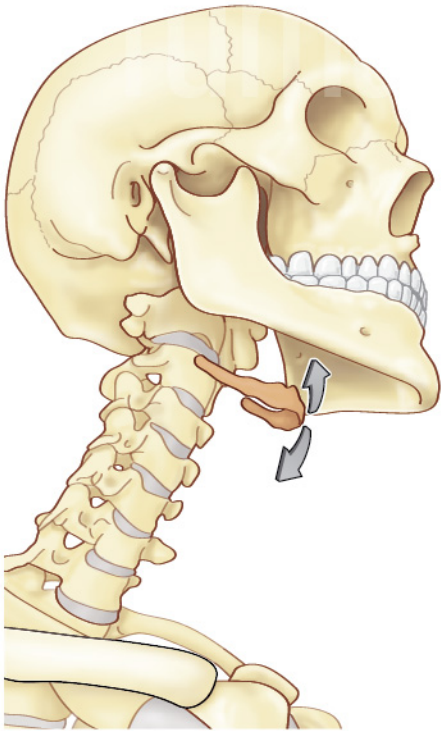


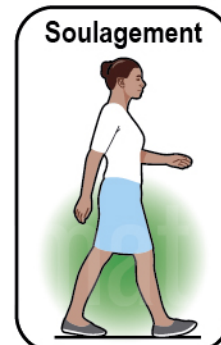
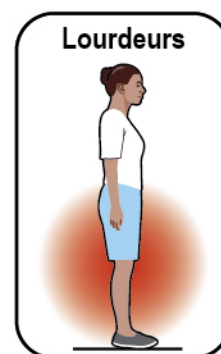
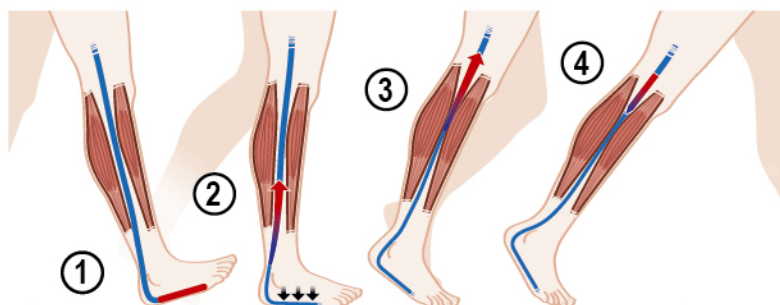
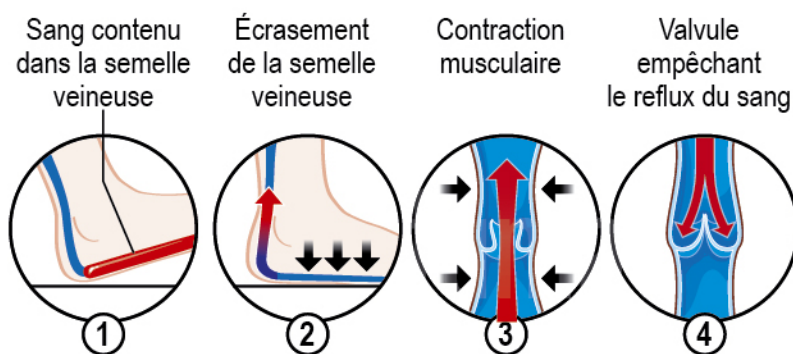
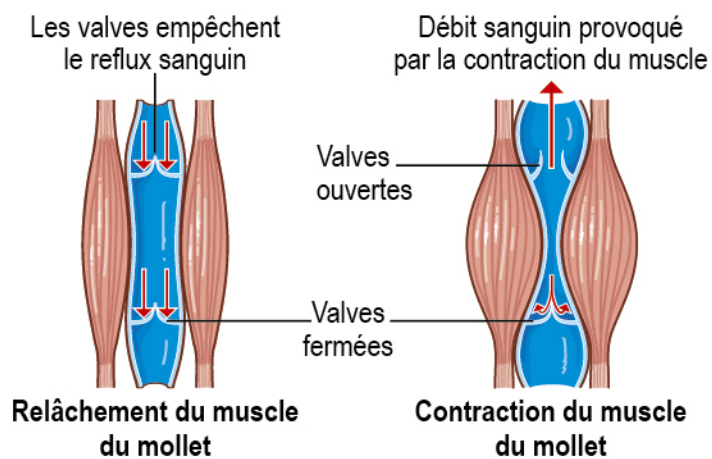
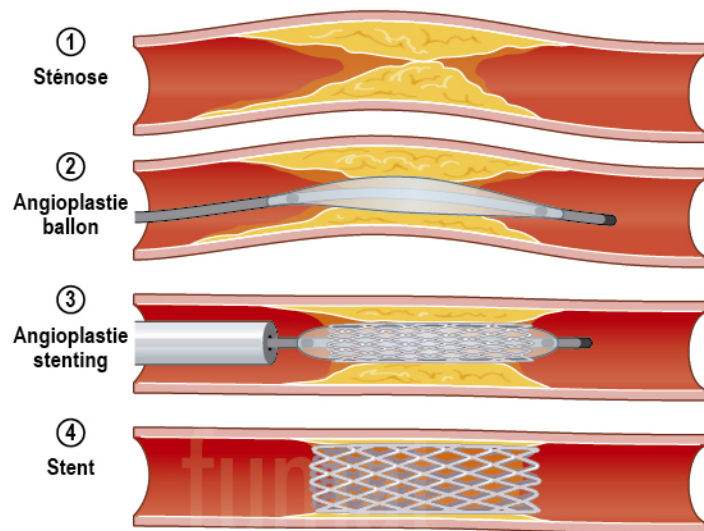
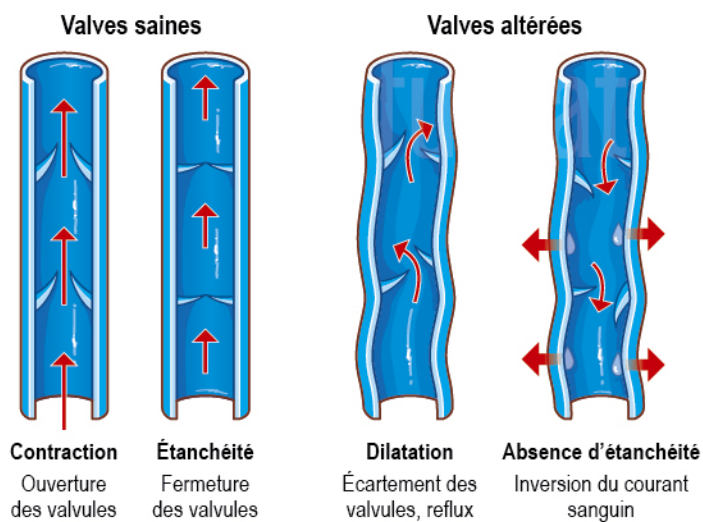




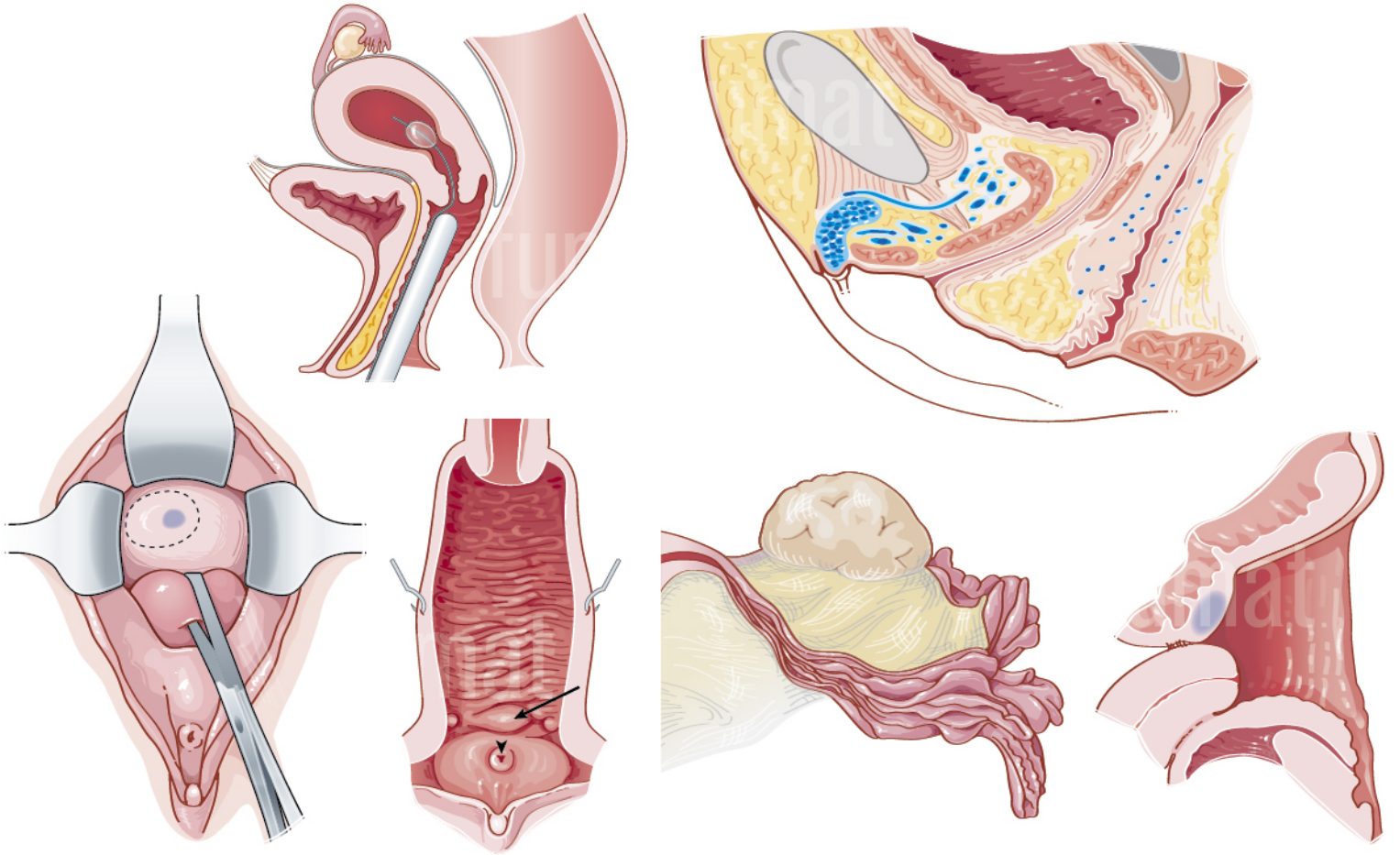




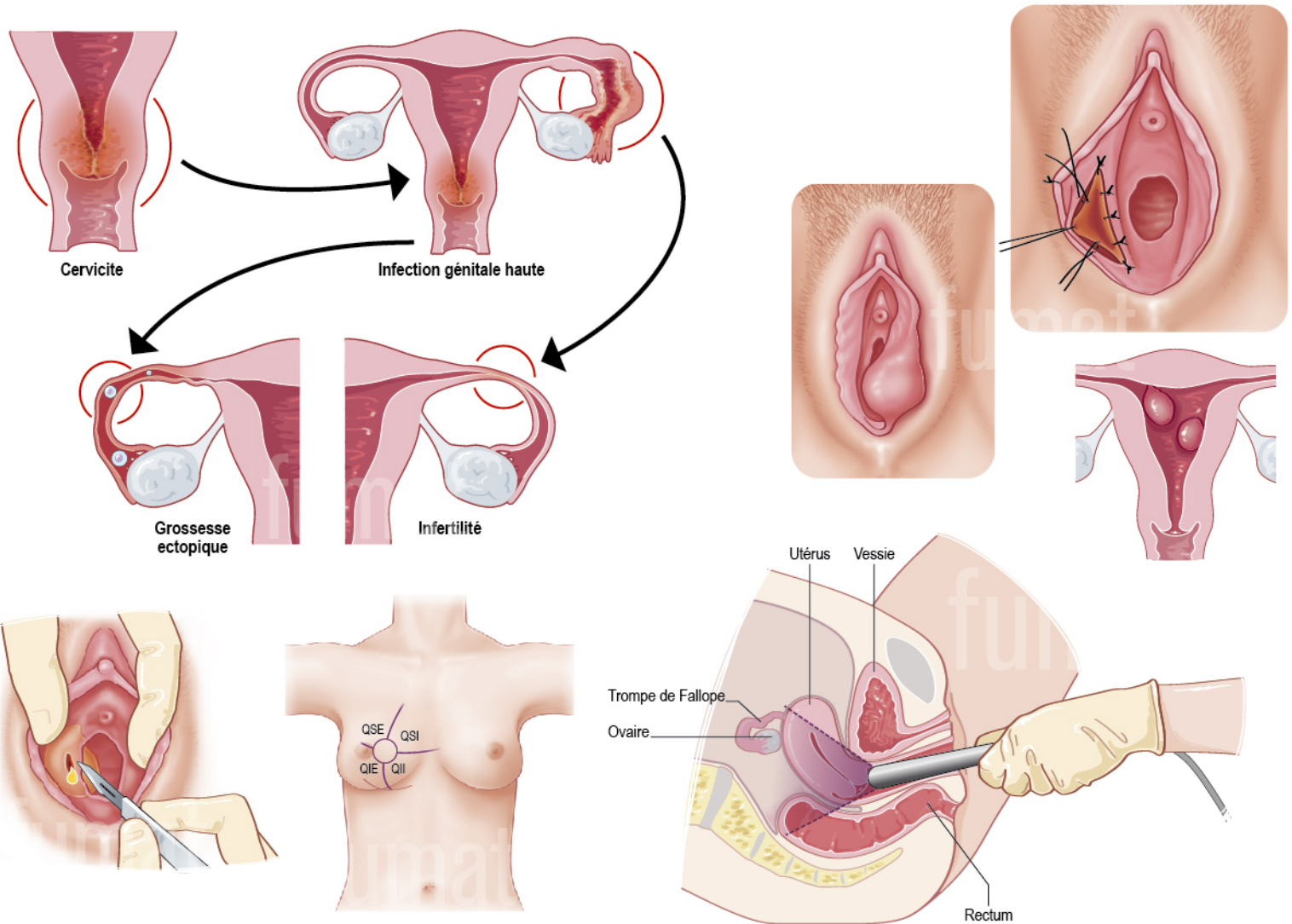




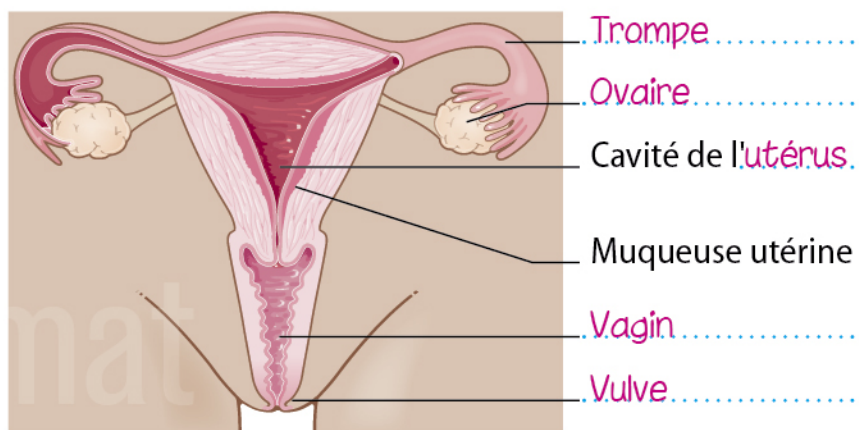
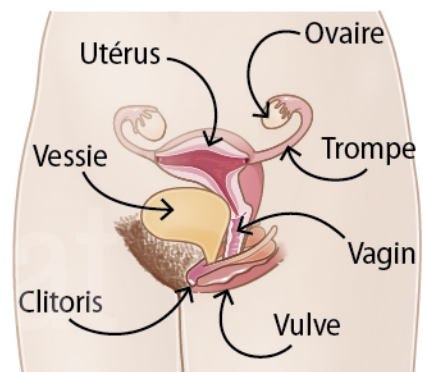
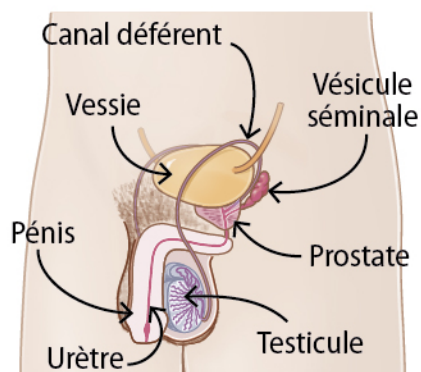
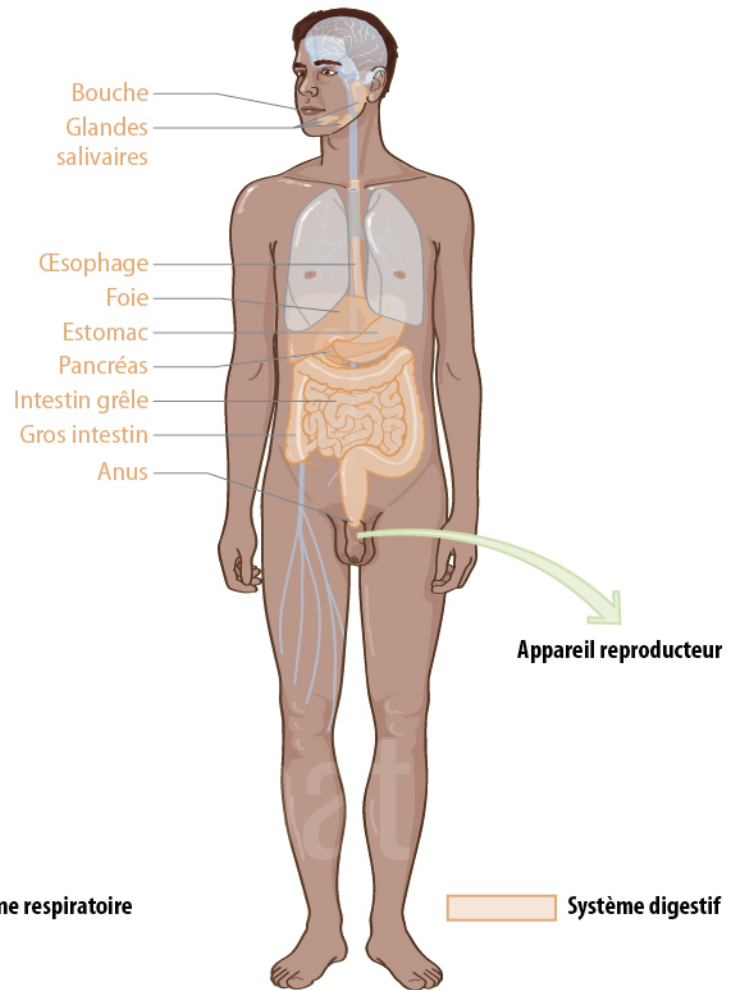
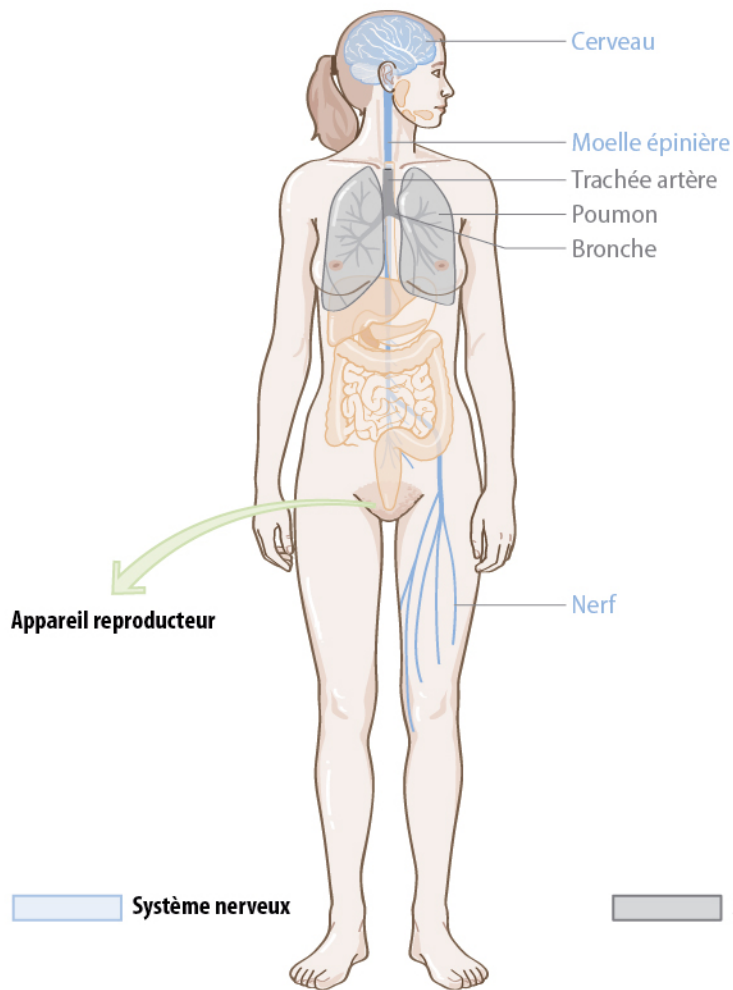




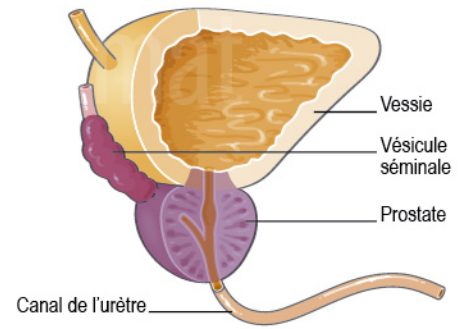
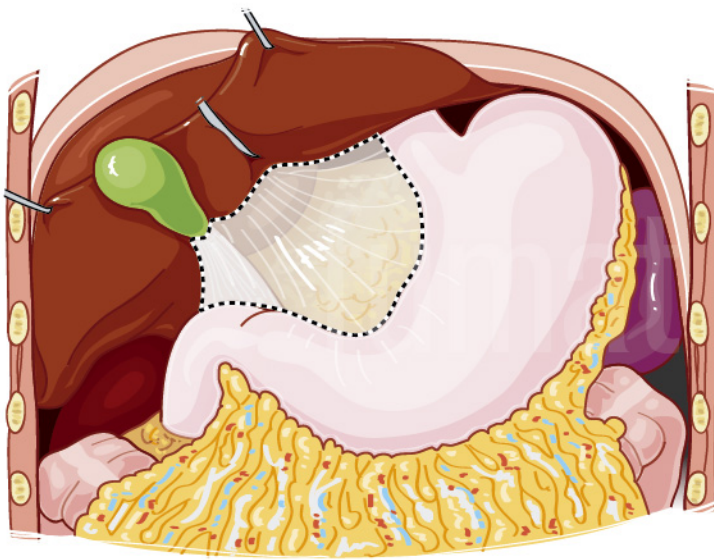
Lavoisier



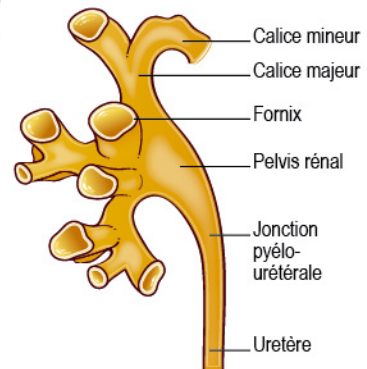
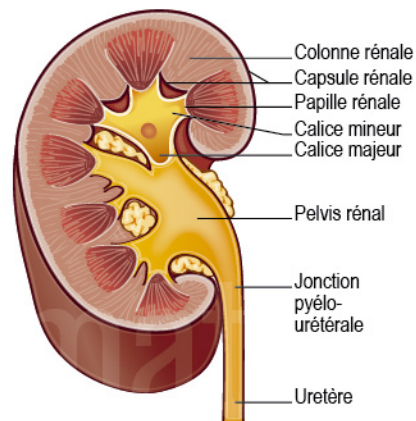
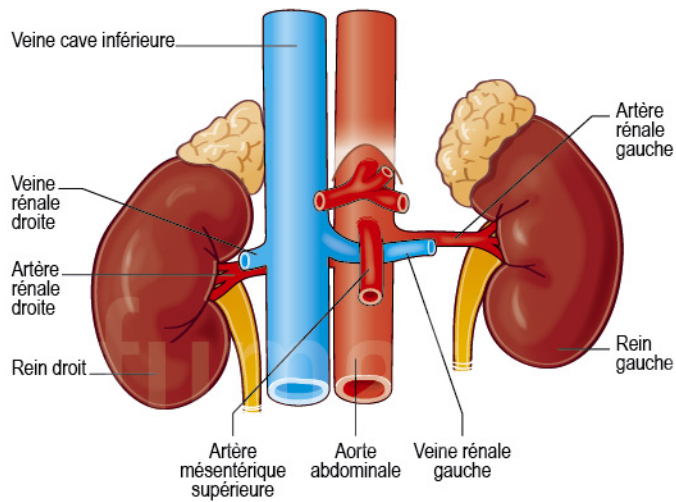
Elsevier Masson



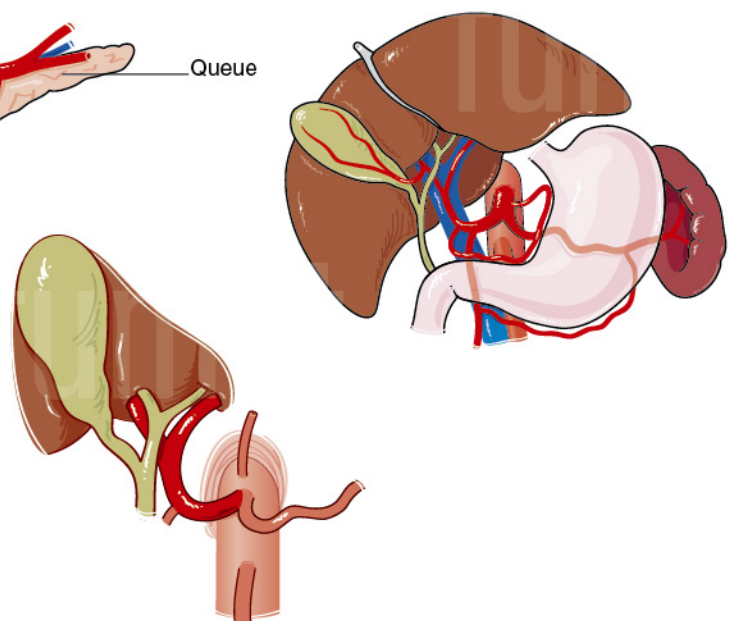
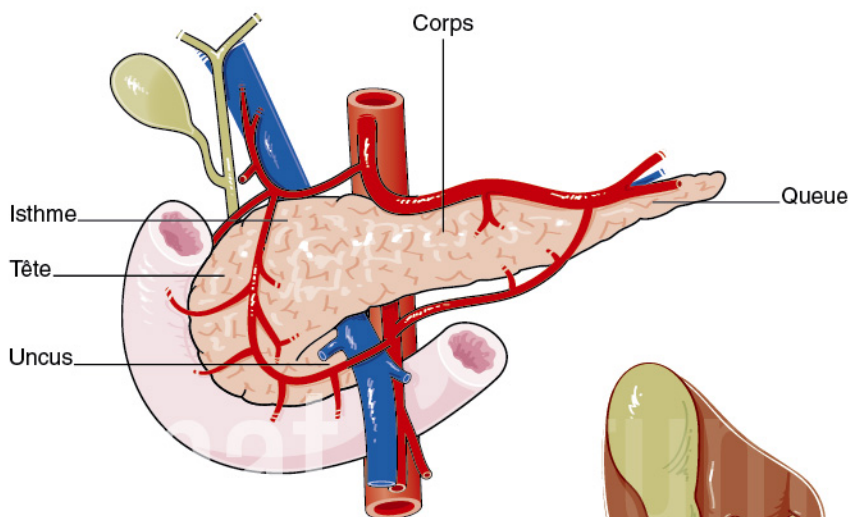




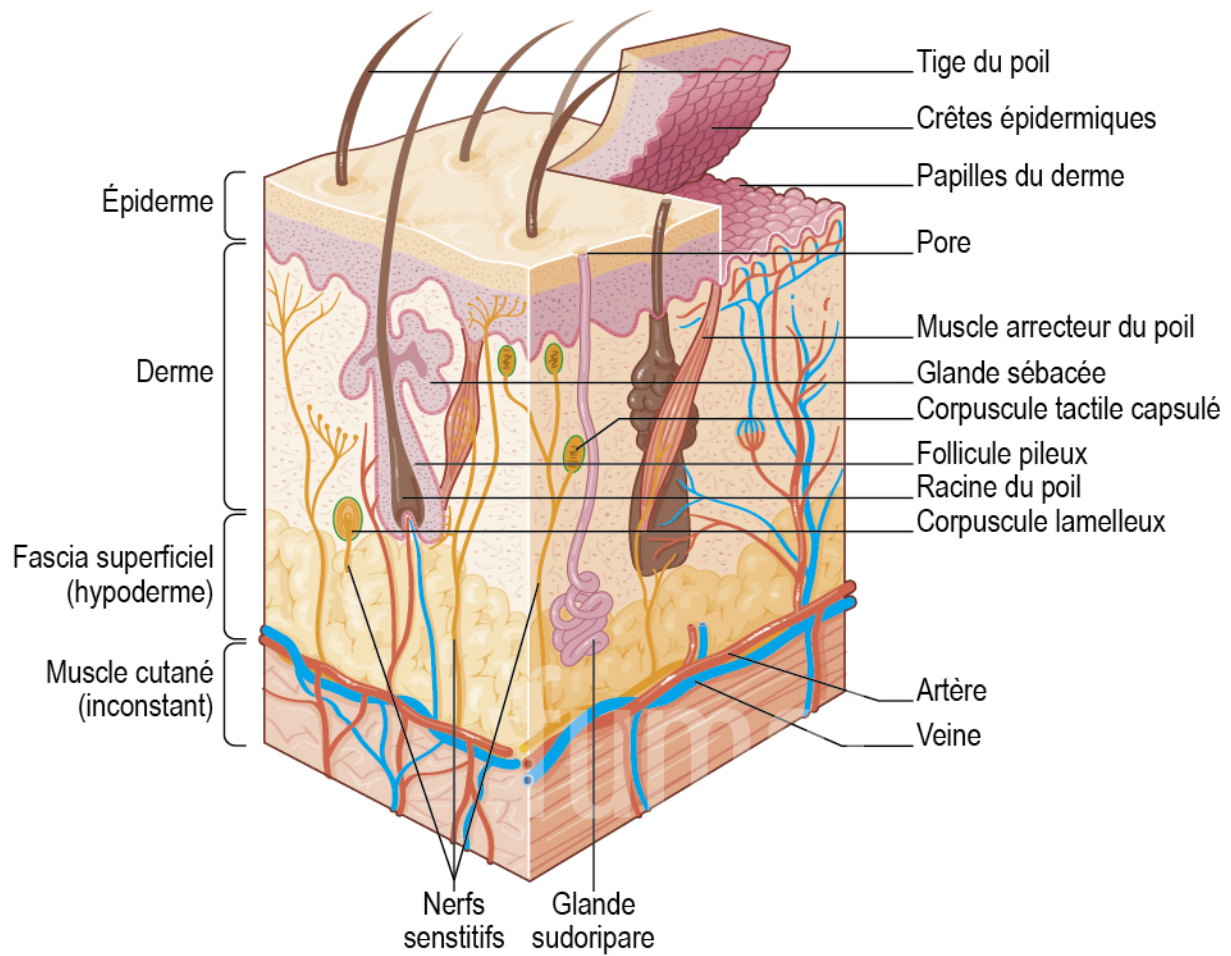
Med Line



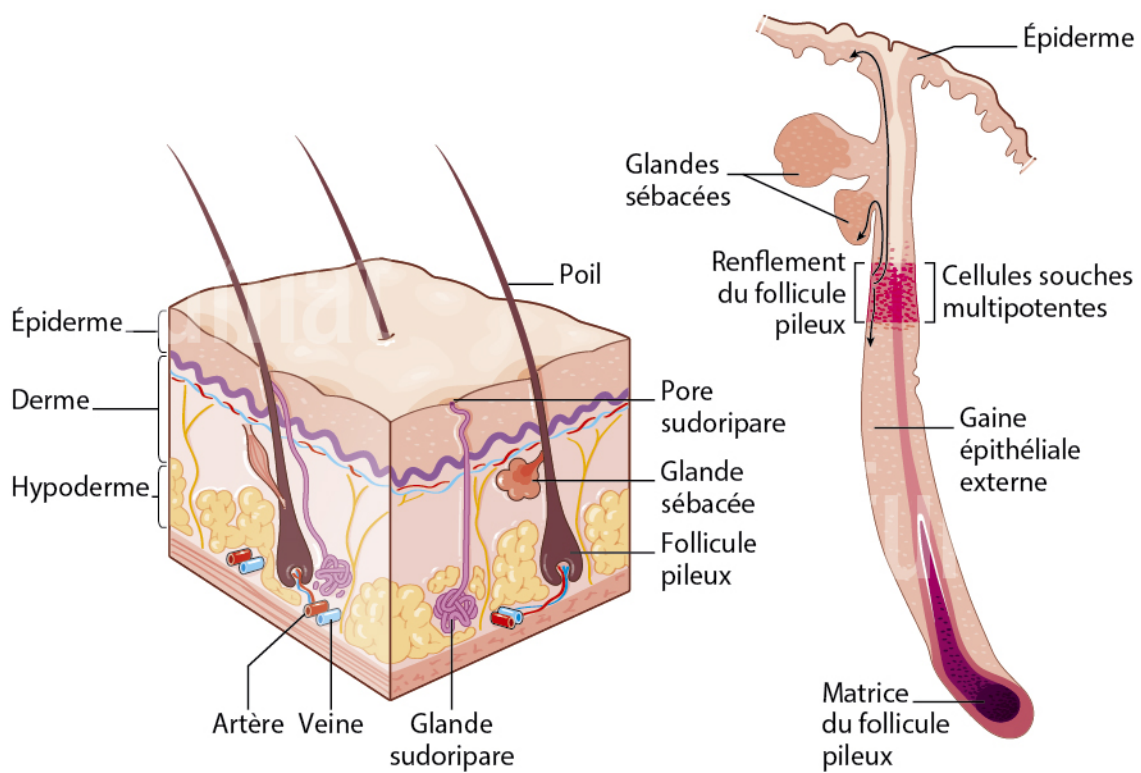
Lavoisier



Elsevier Masson

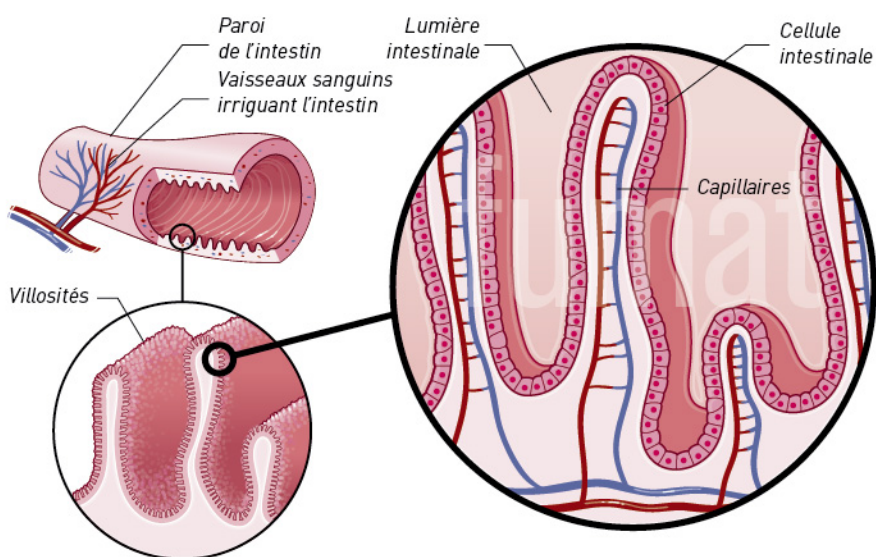
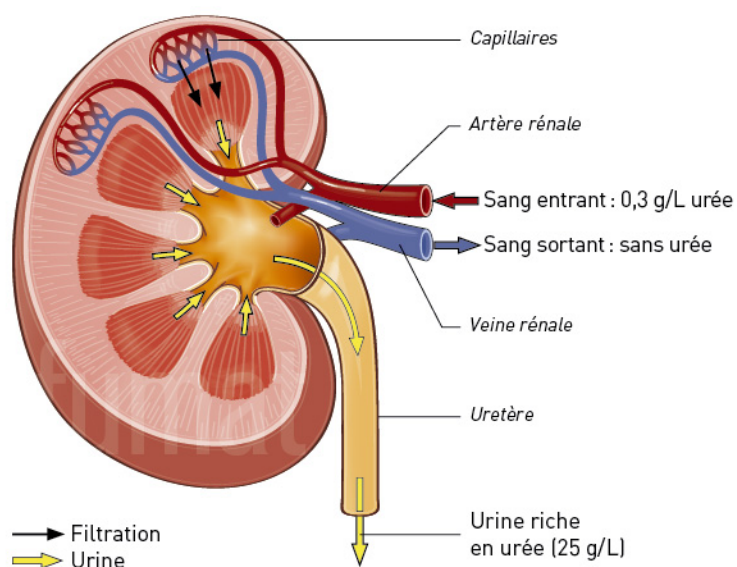
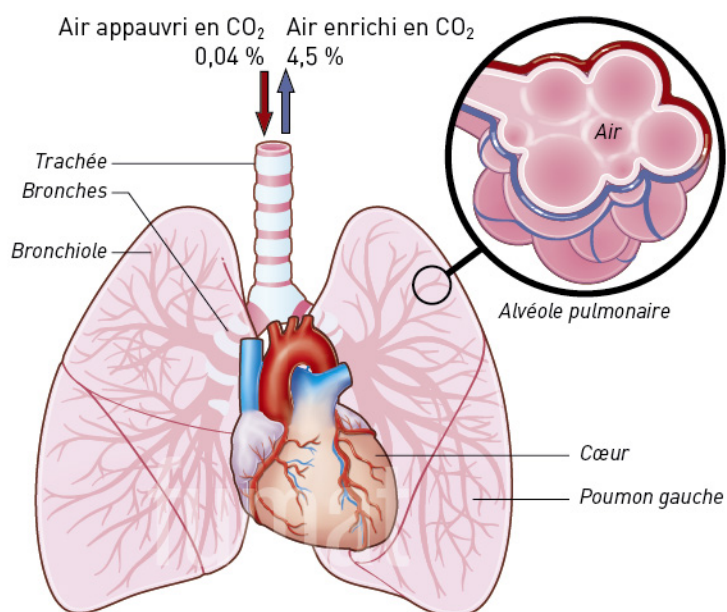
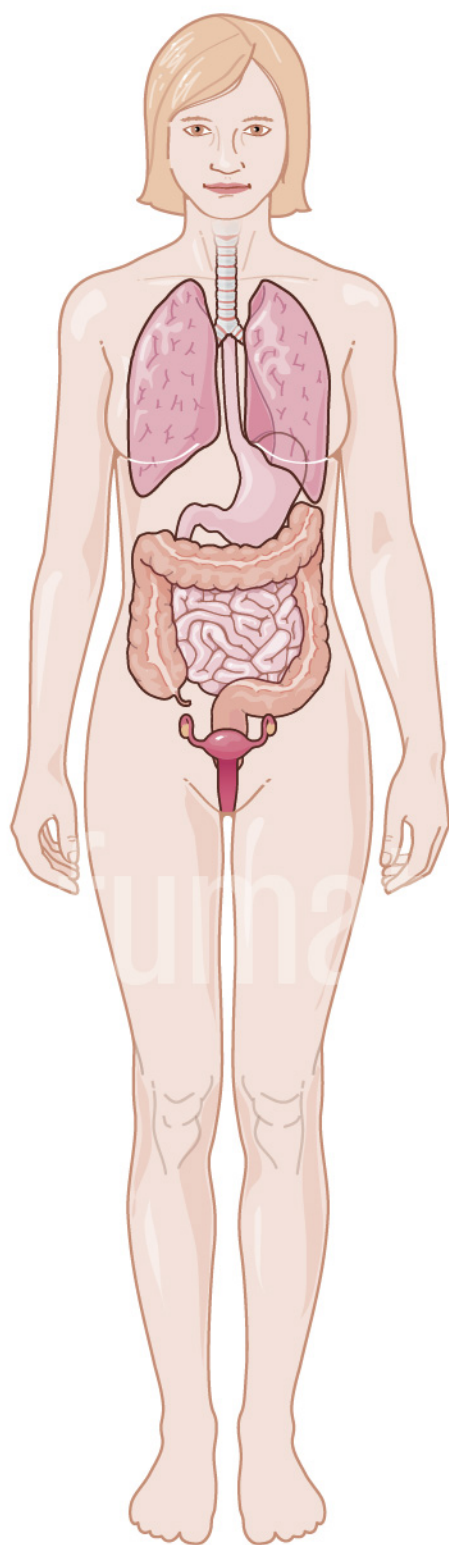


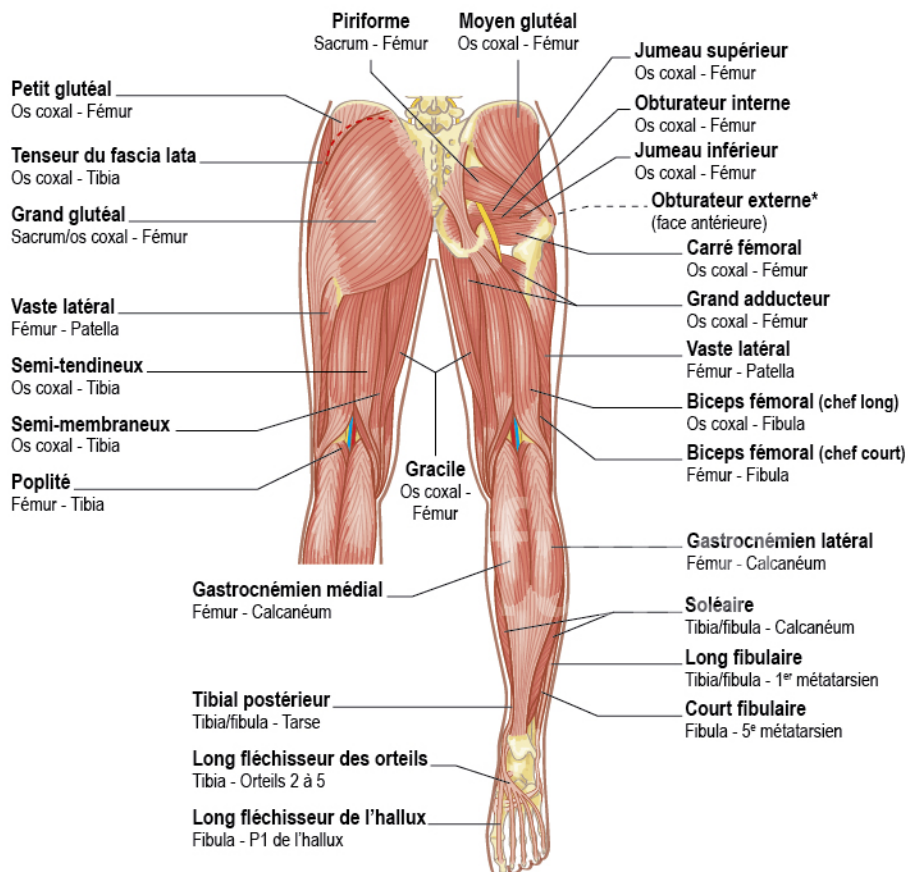
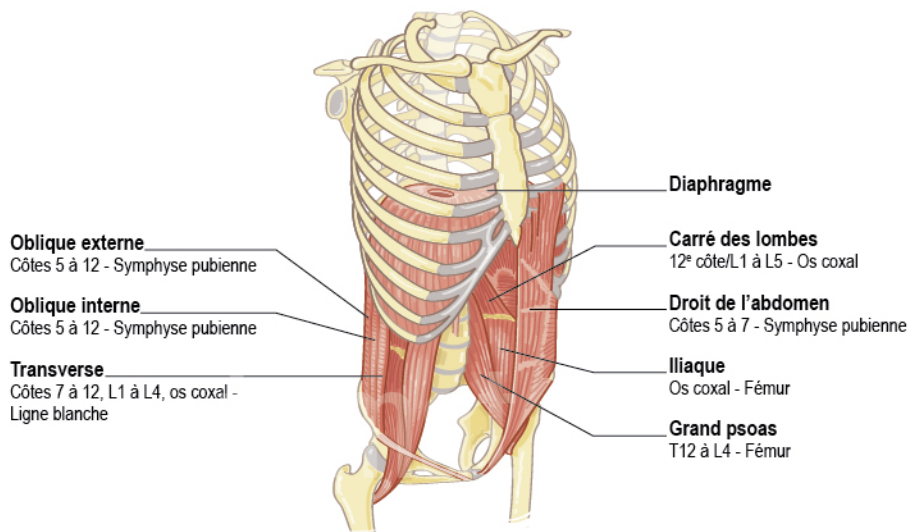
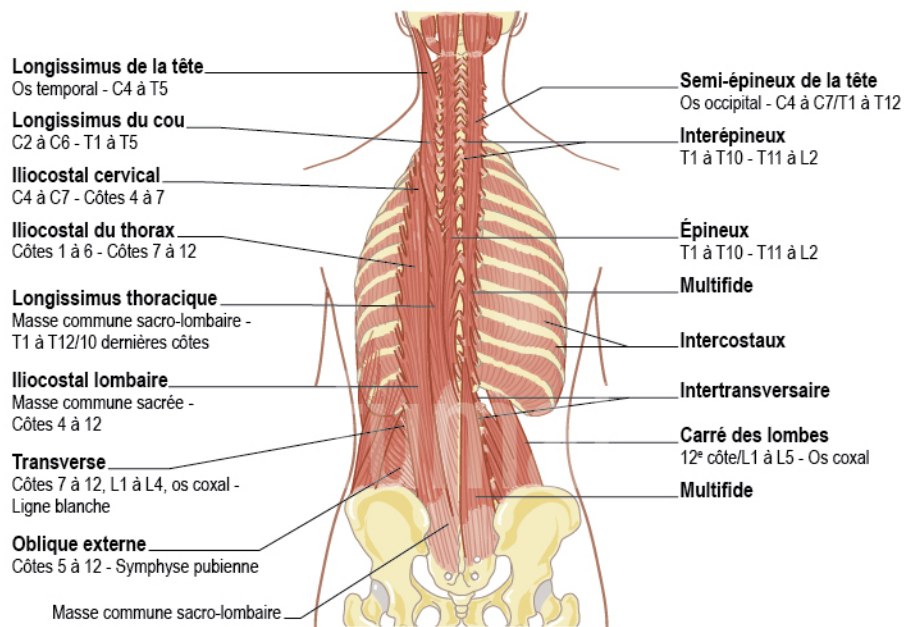
Elsevier Masson



Éditions John Libbey Eurotext

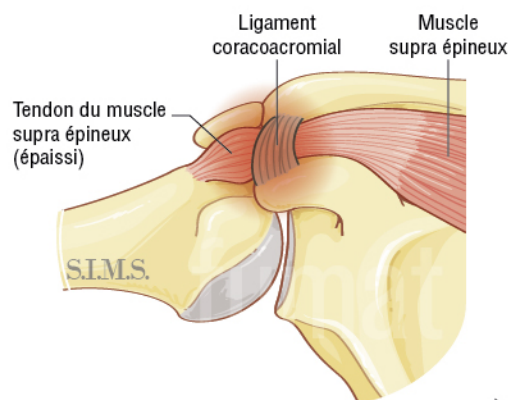




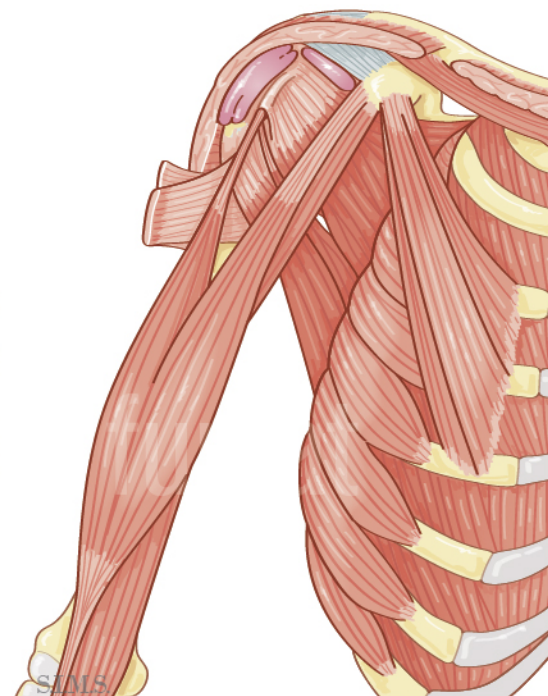
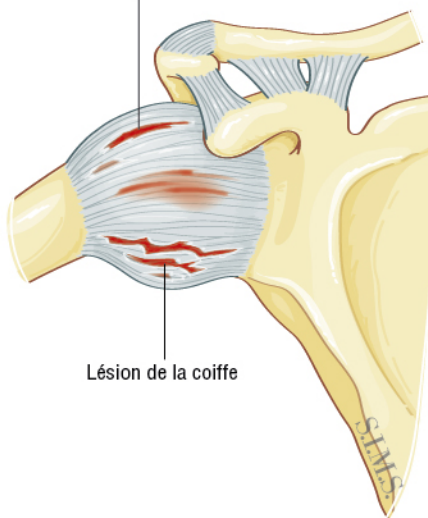




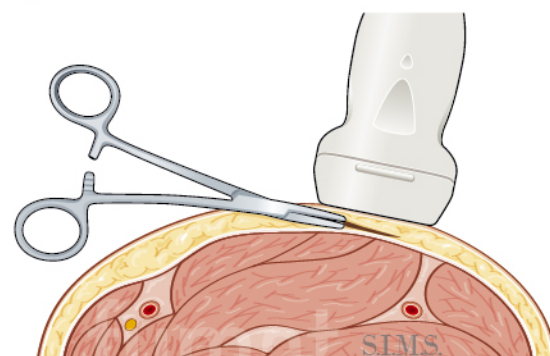
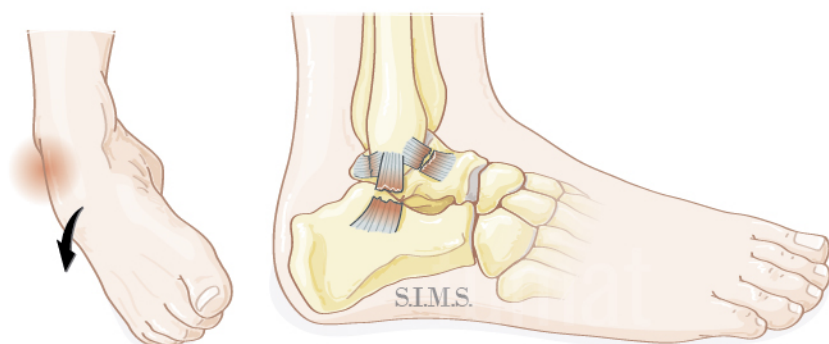
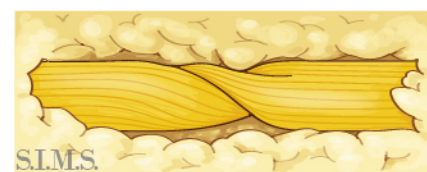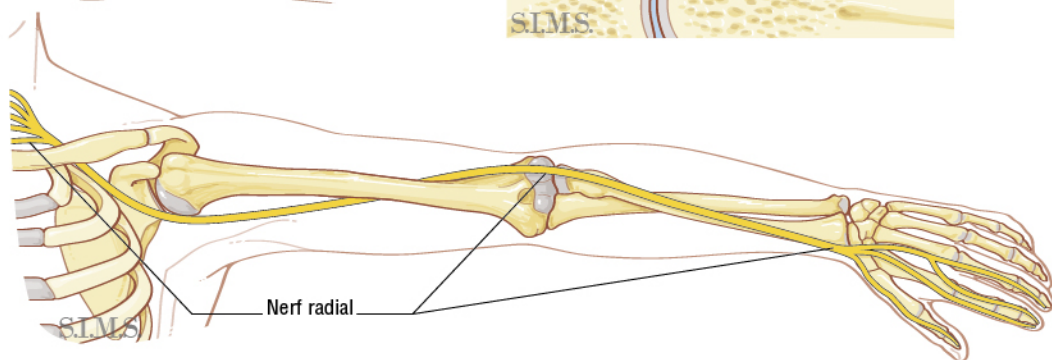
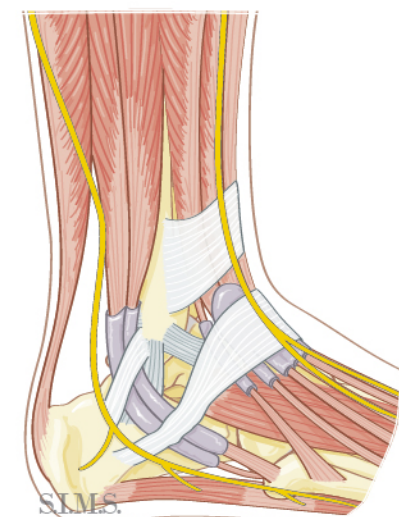
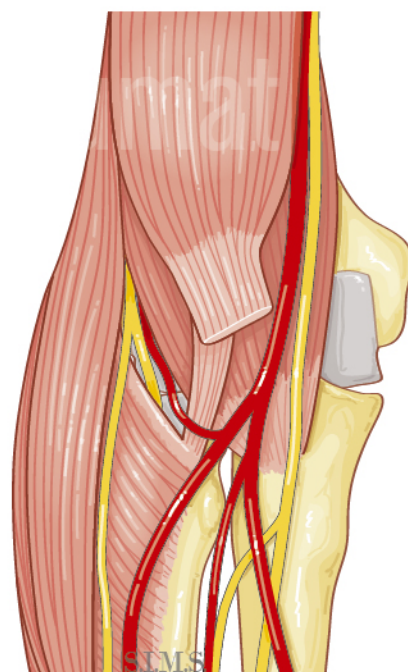
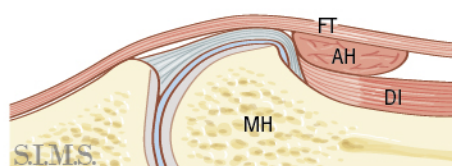
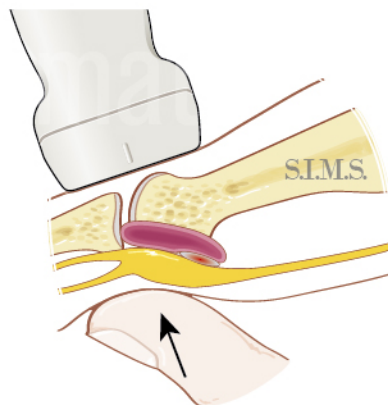
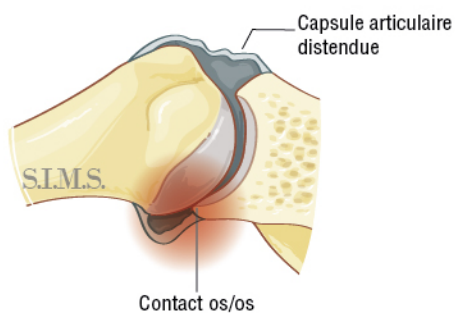
## Conflit externe

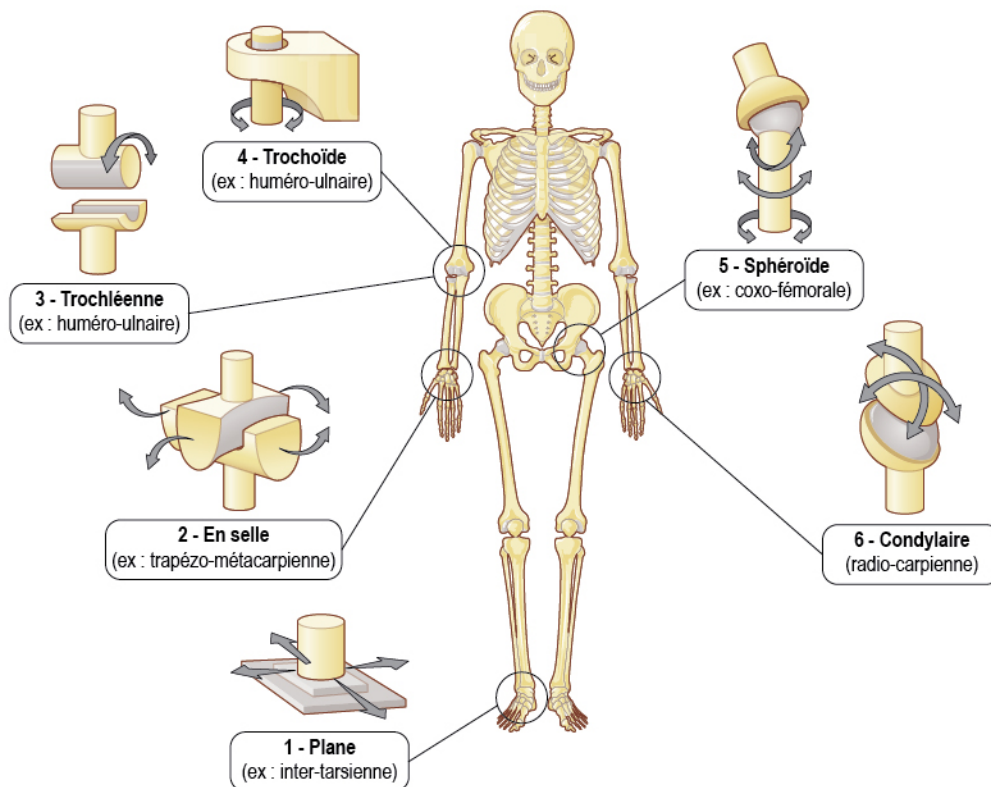
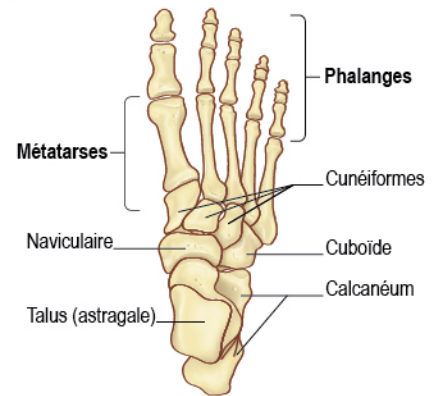
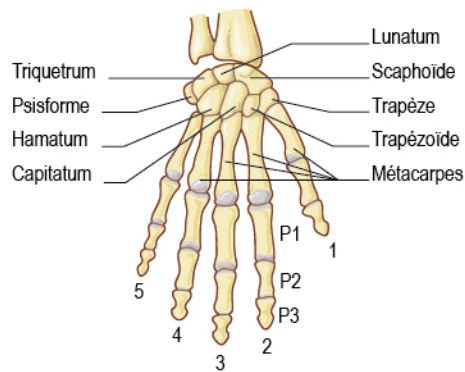
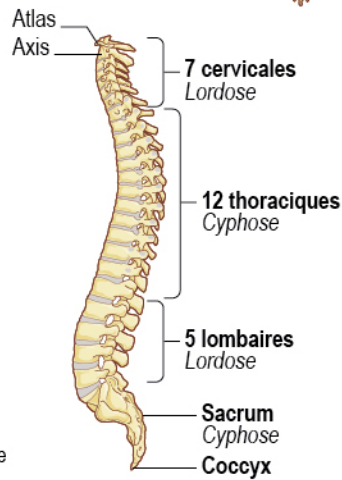
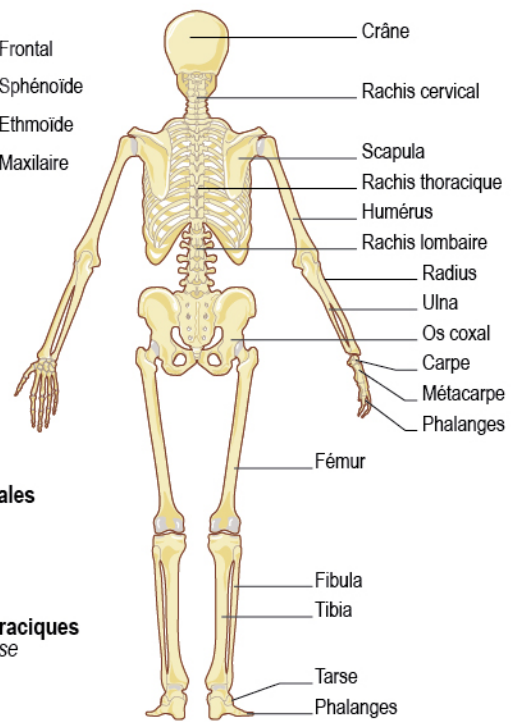
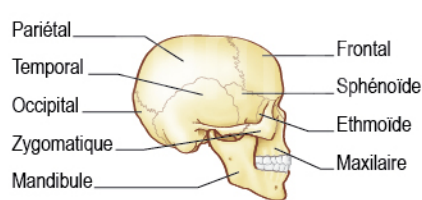
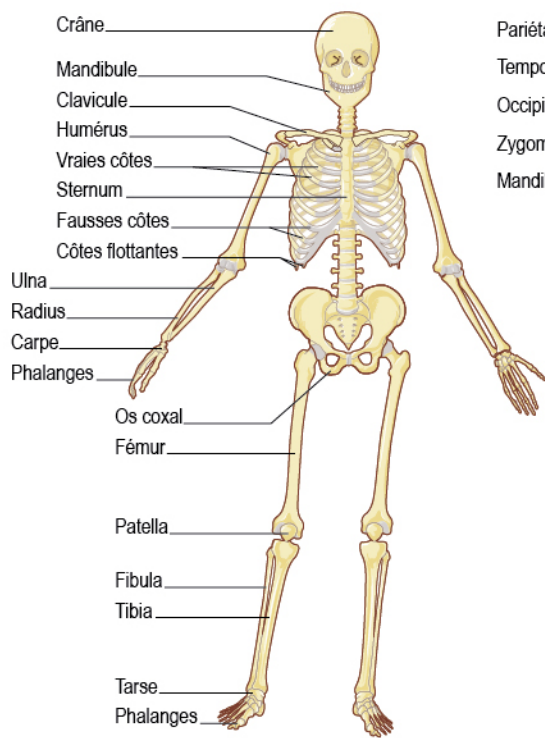


Lésion de la coiffe



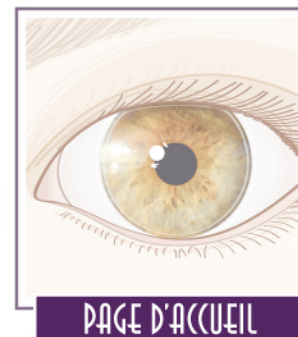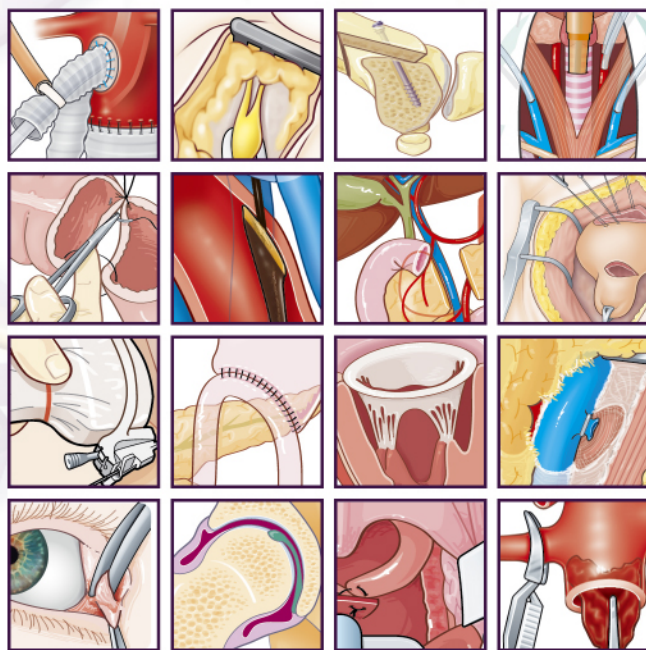
## Conflit interne



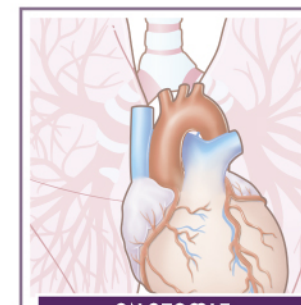




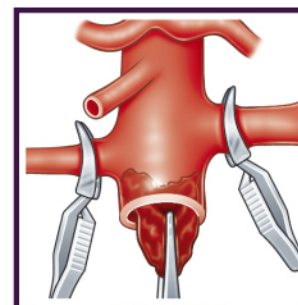
# CHIRURGIE



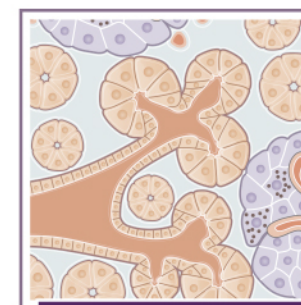
PAGE D'ACCUEIL



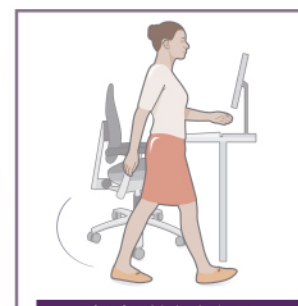
ANATOMIE



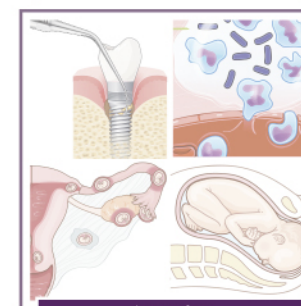
CHIRURGIE



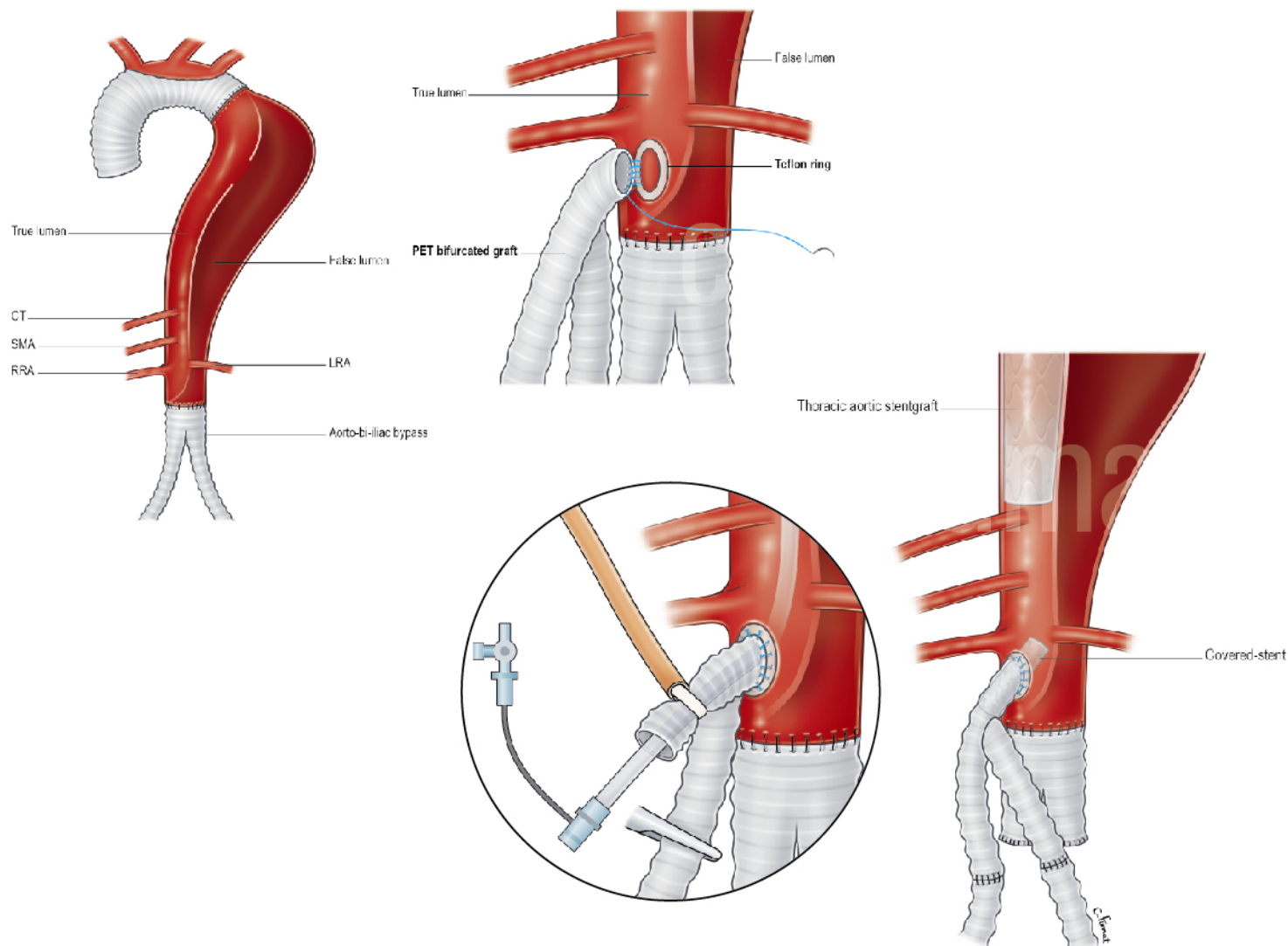
MICROSCOPIE



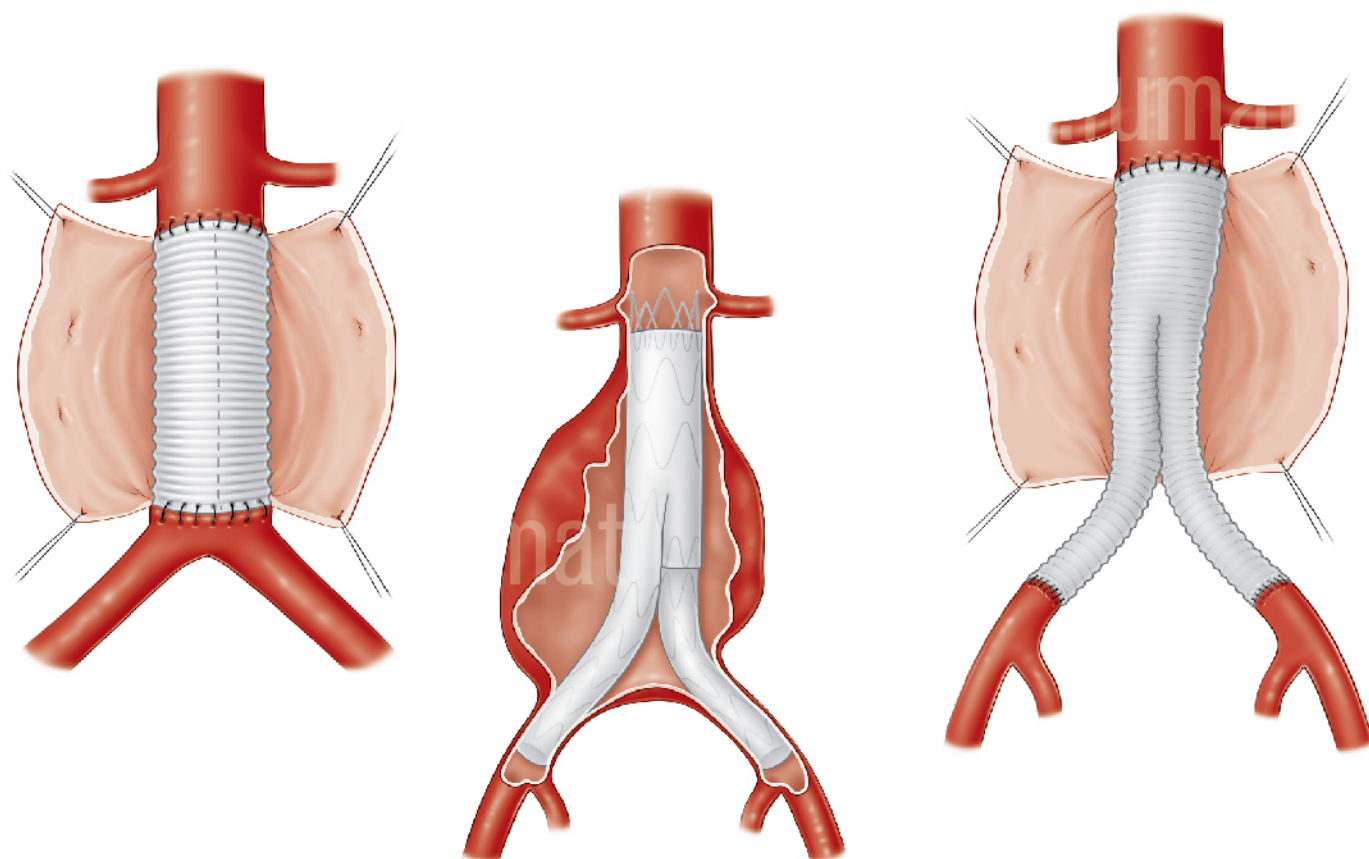
PERSONNAGES



DIVERS

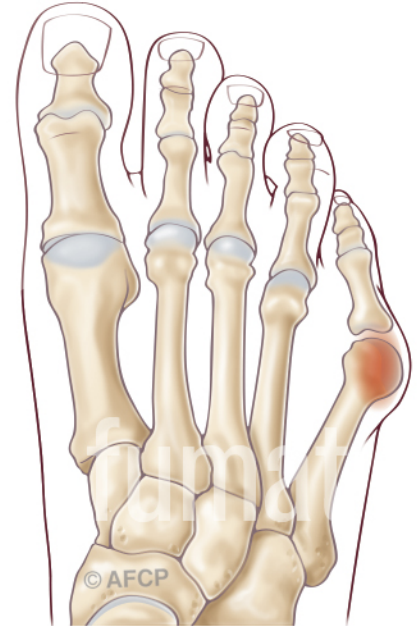
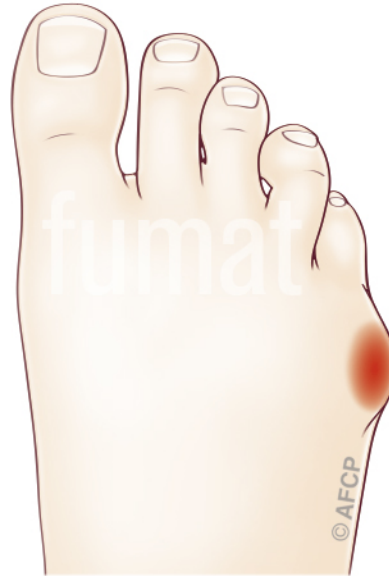
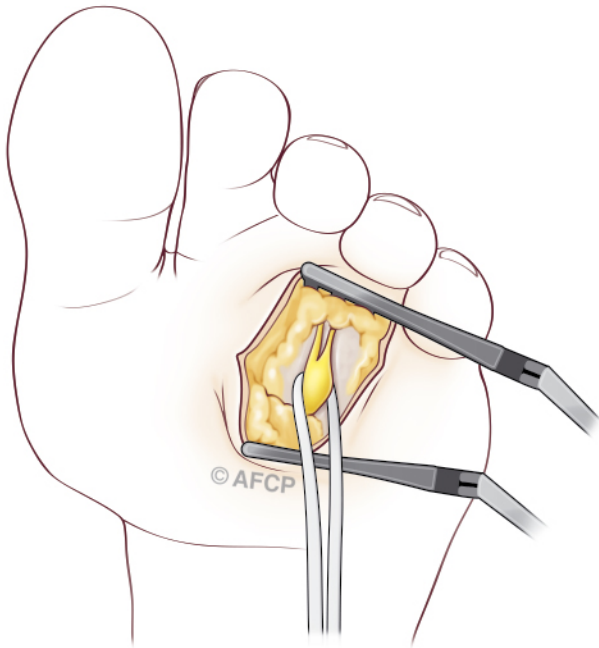
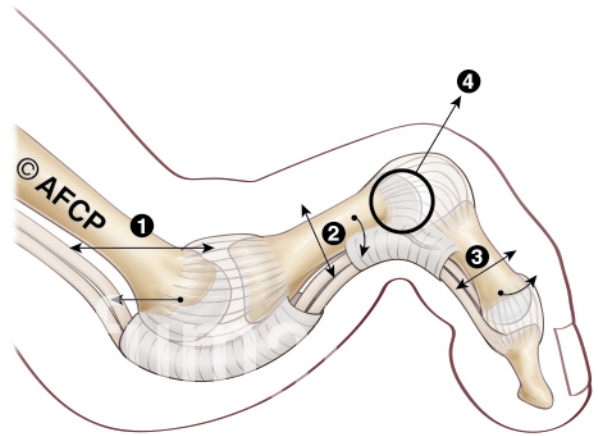
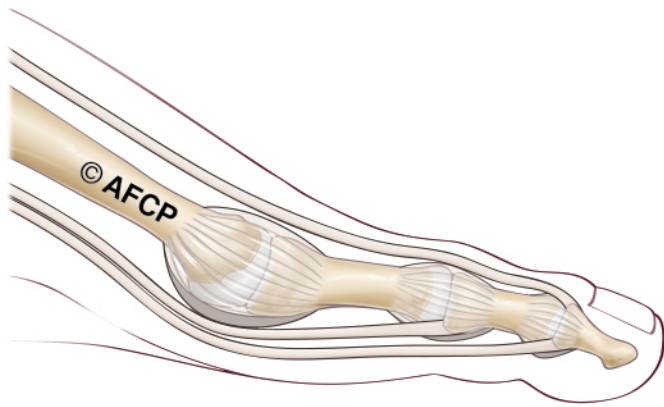


CHRU Strasbourg - Pr Nabil Chakfé

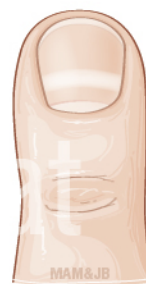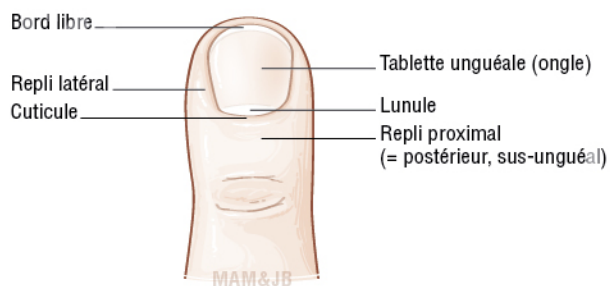


ARCHIVTT- Pr Yves Castier

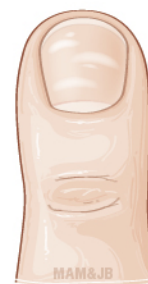



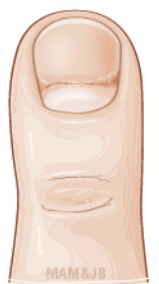## Association Française de Chirurgie de la Cheville et du Pied



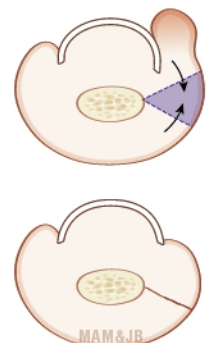
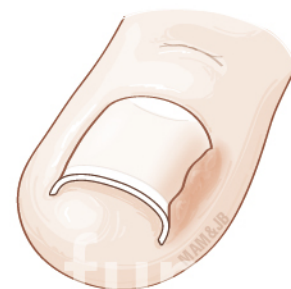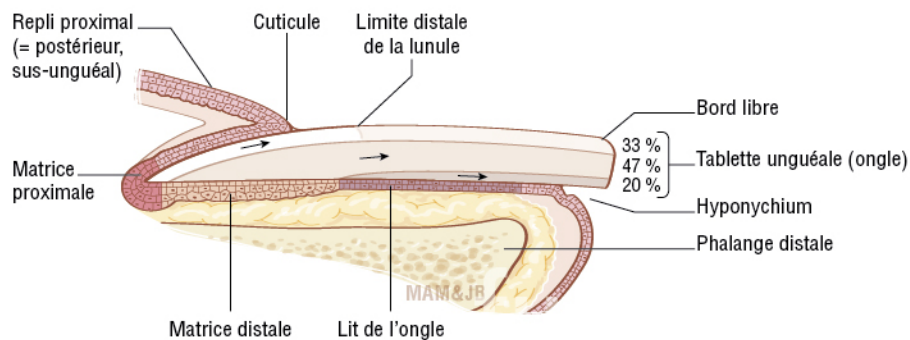
Lignes de Mees



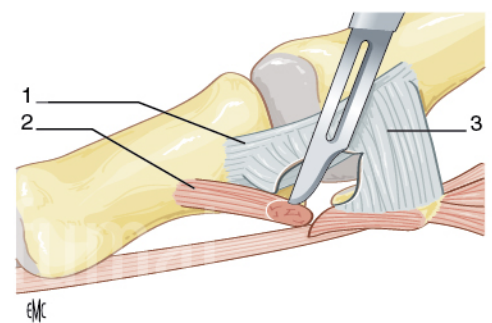
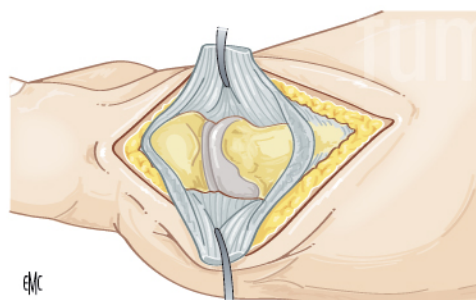
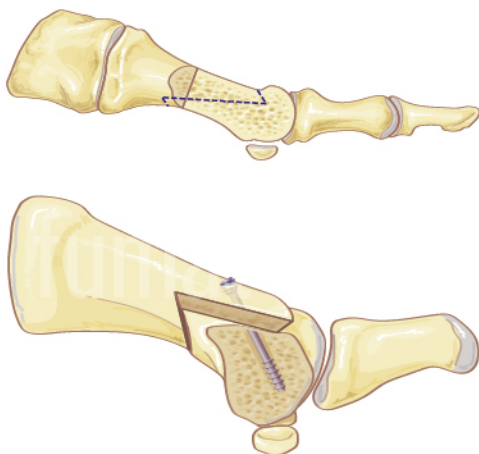
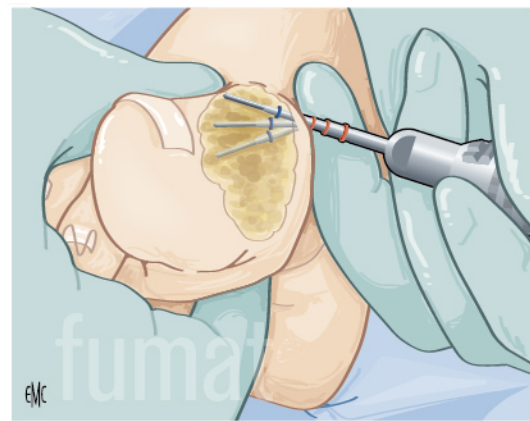
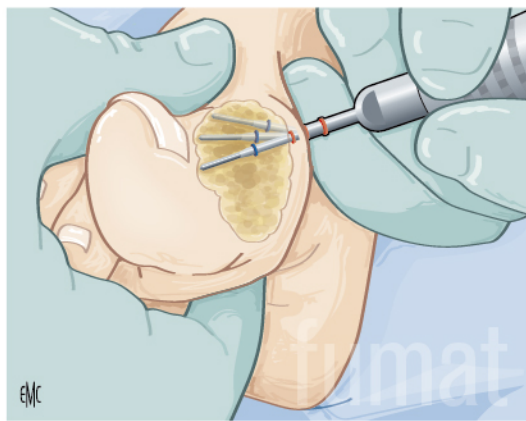
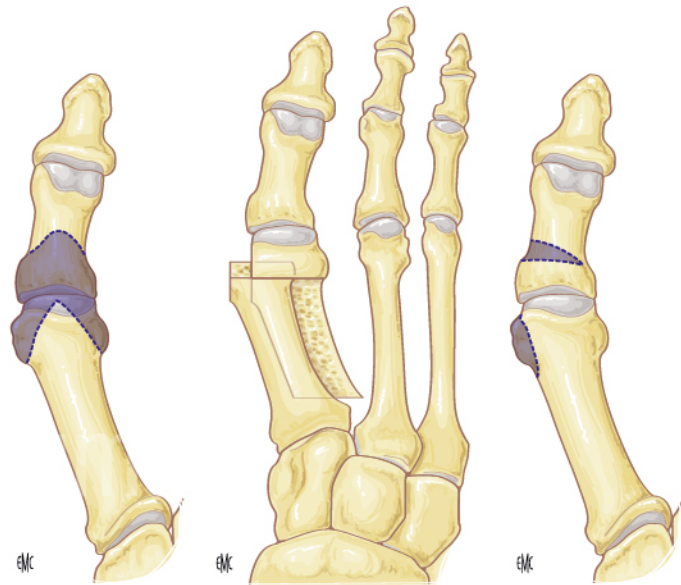
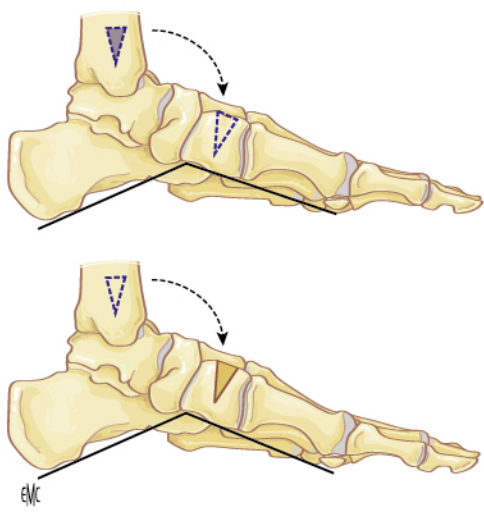
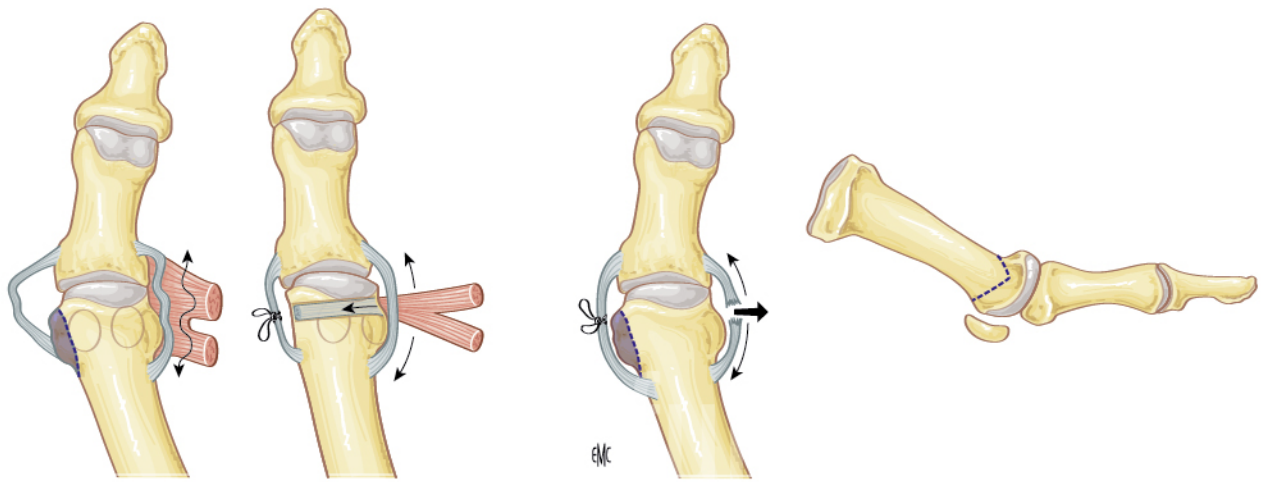
Leuconychies



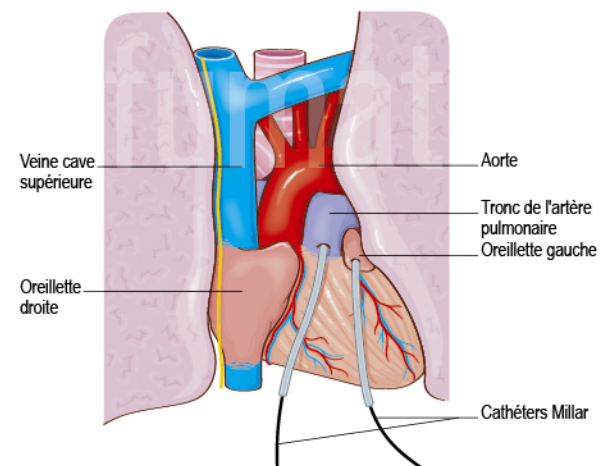
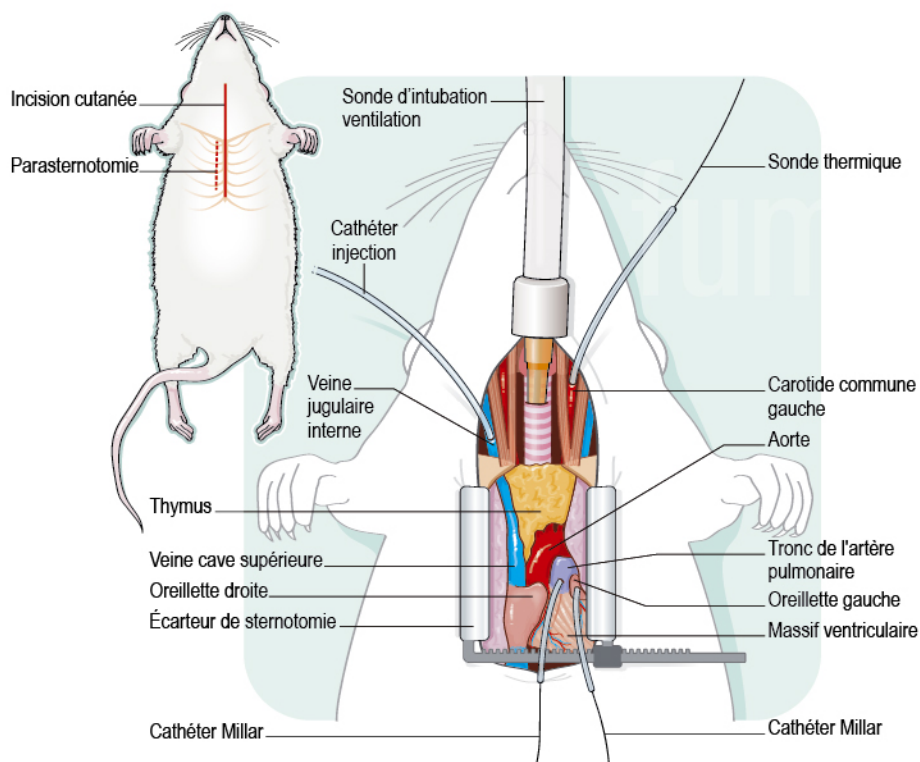
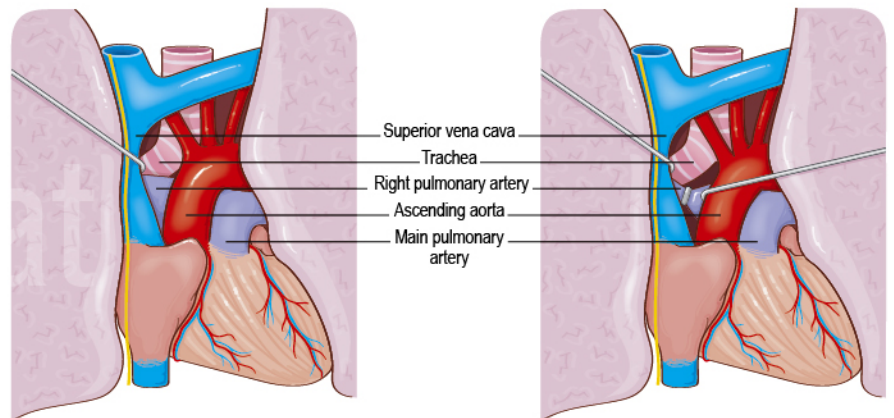
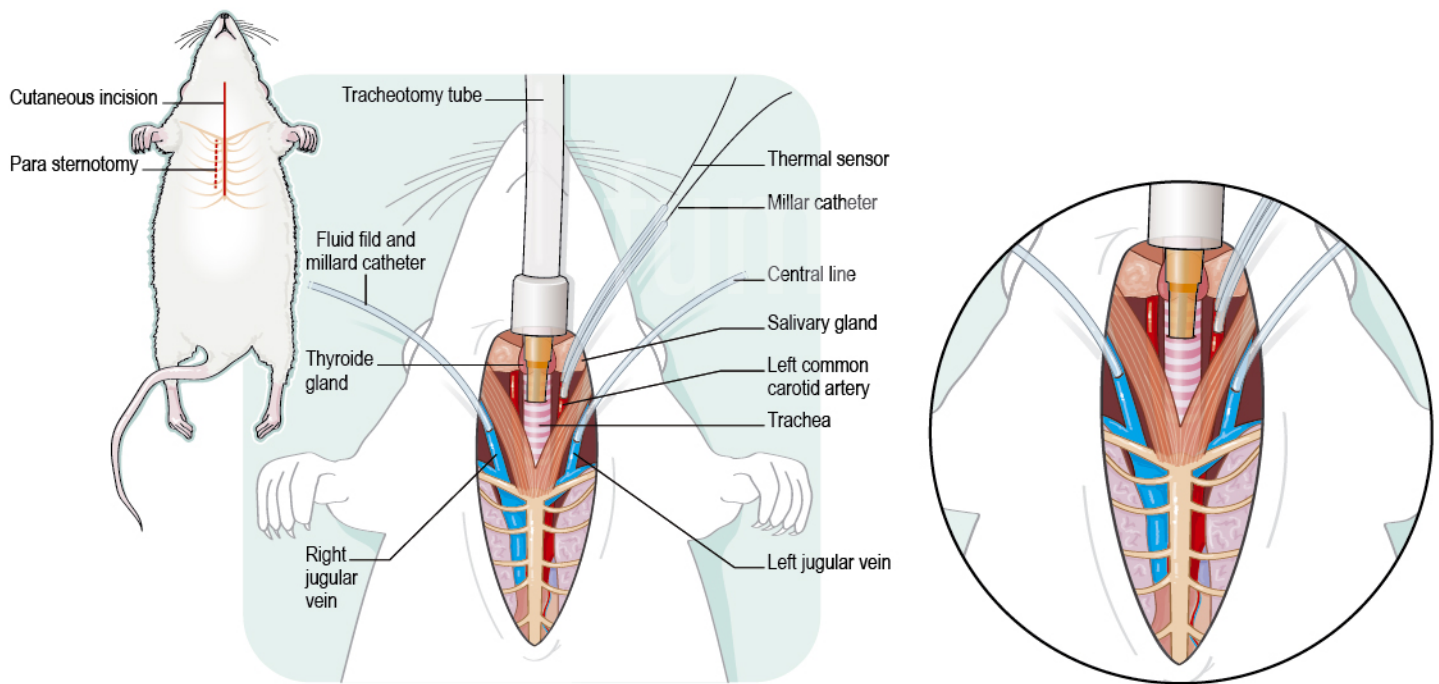
Lignes de Beau

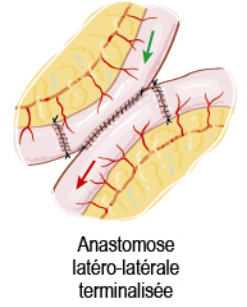
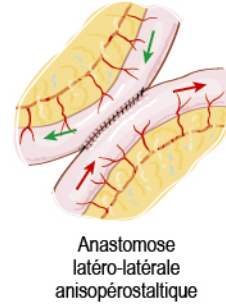
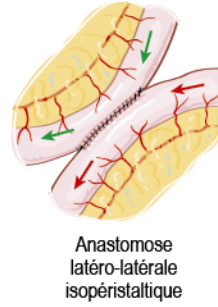
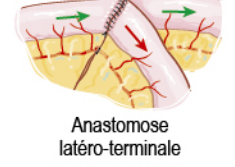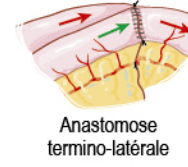
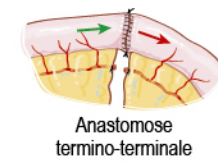
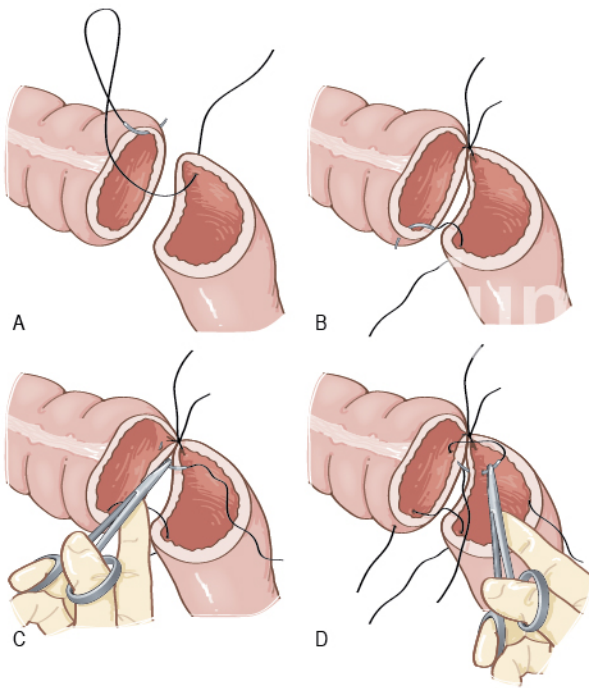


Plastie du bourrelet

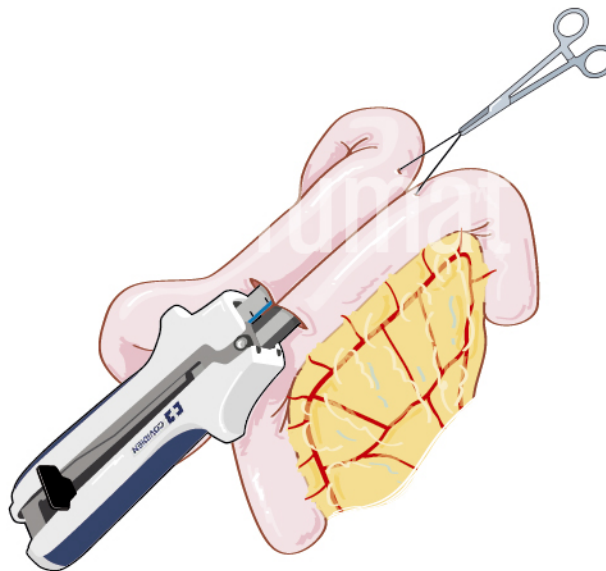
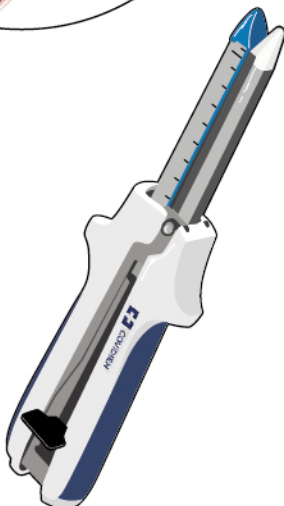
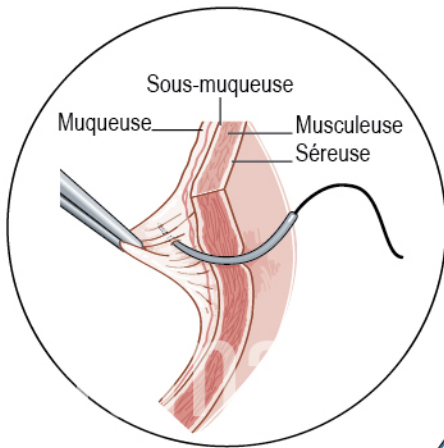
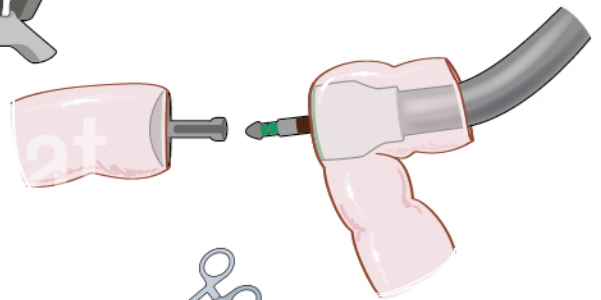
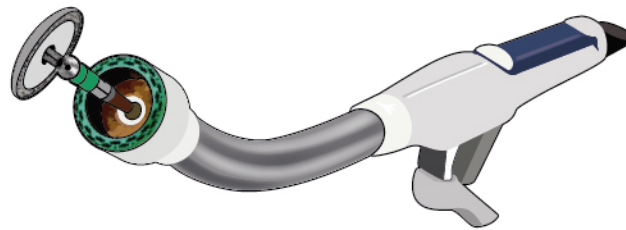
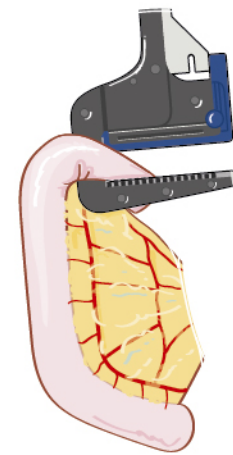
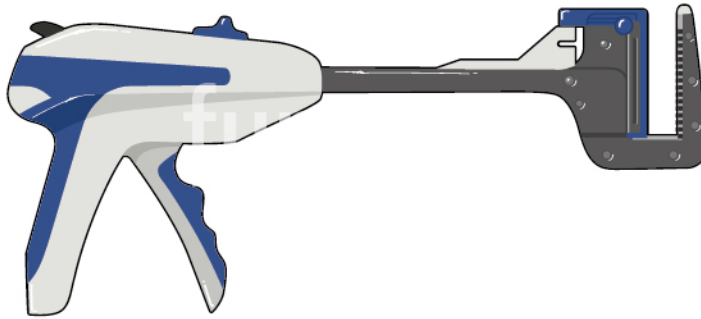




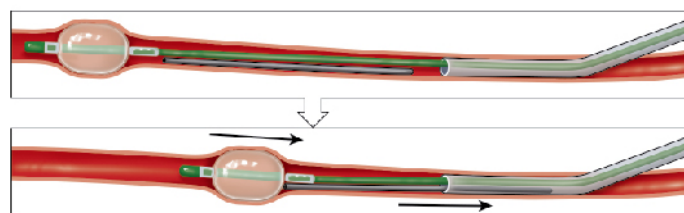
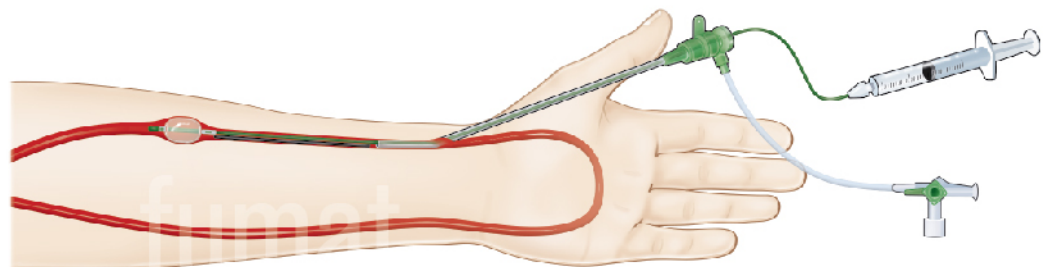
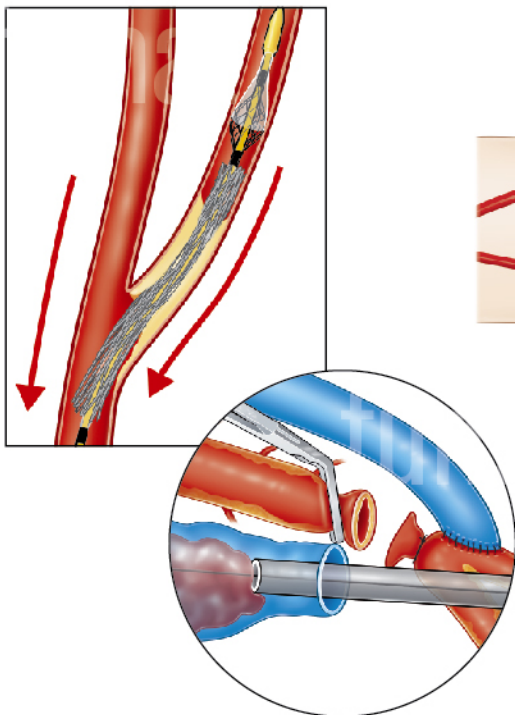
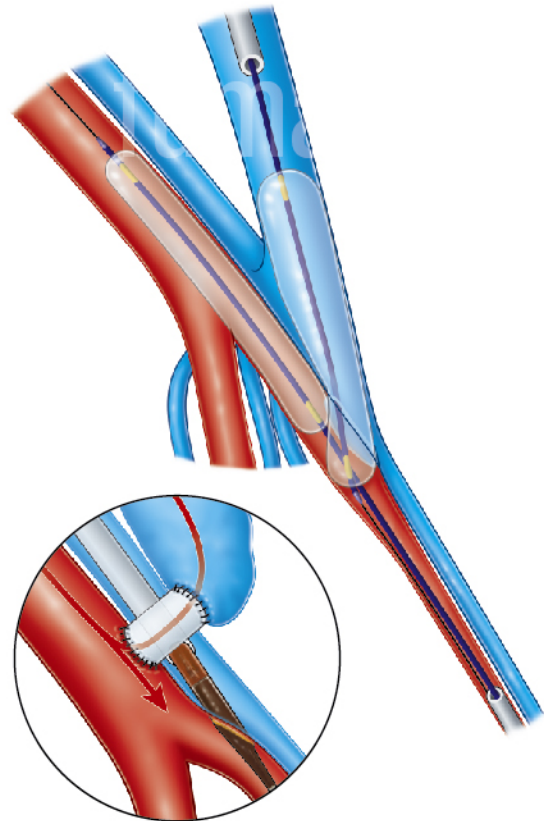
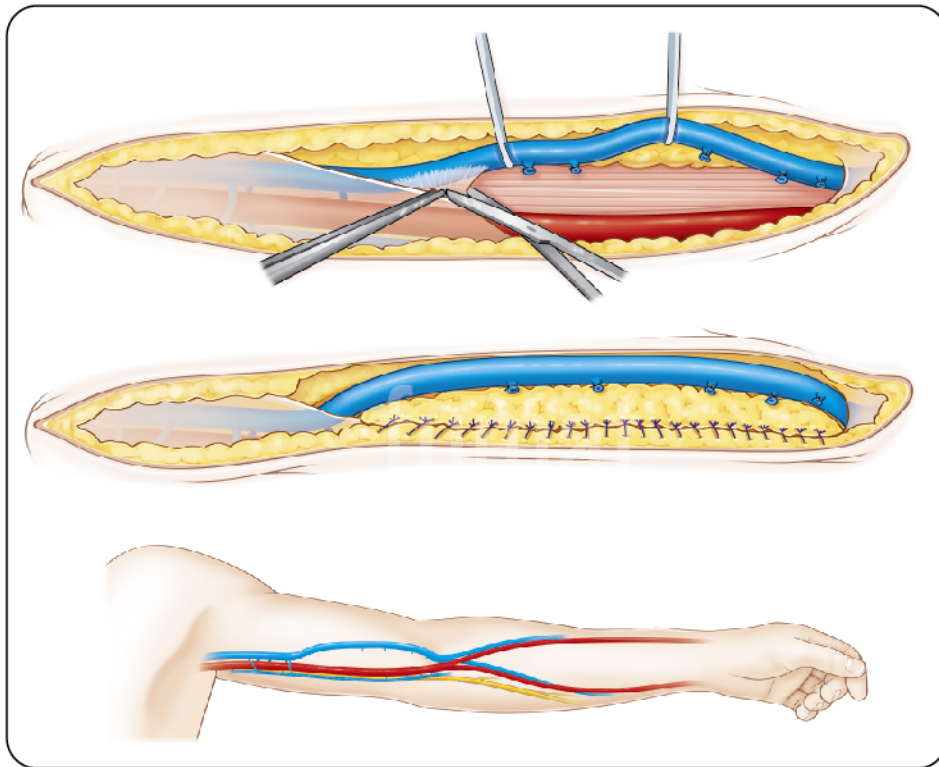
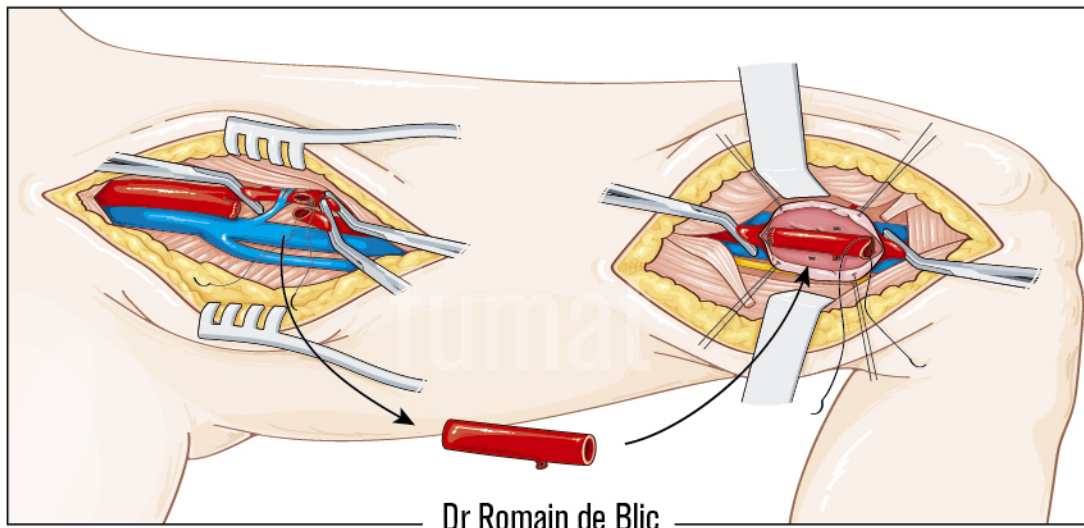


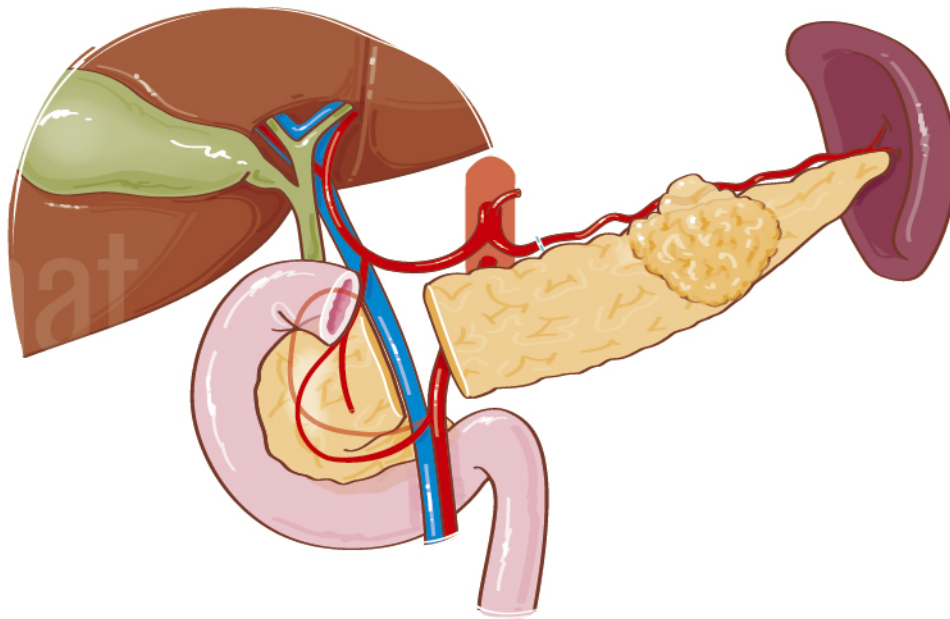
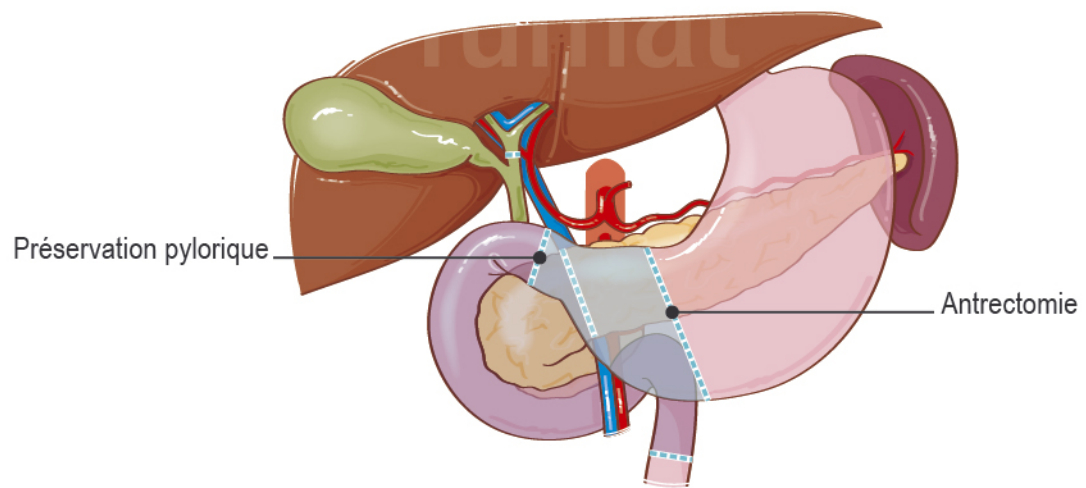


→ Flux afférent  
→ Flux efférent

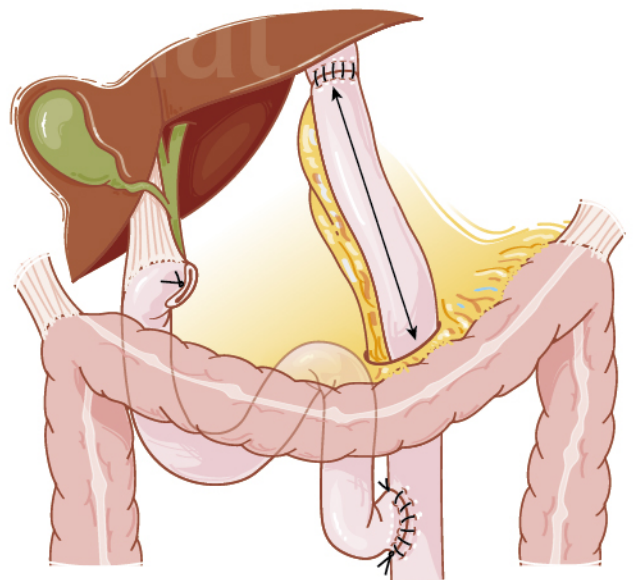
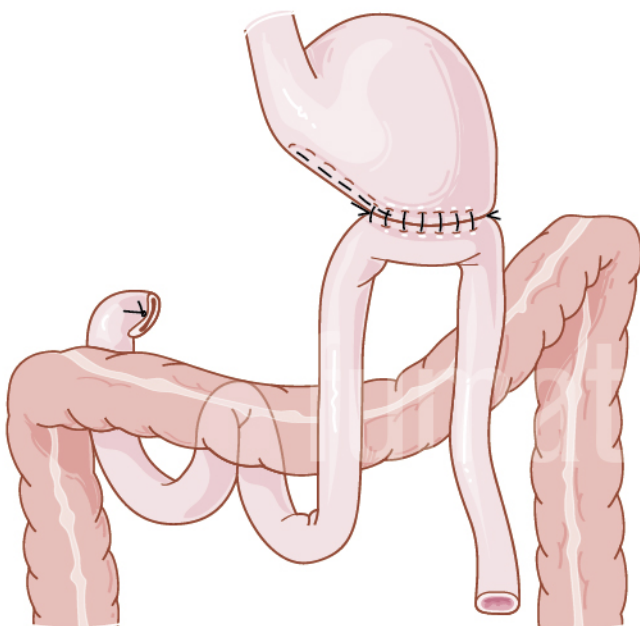






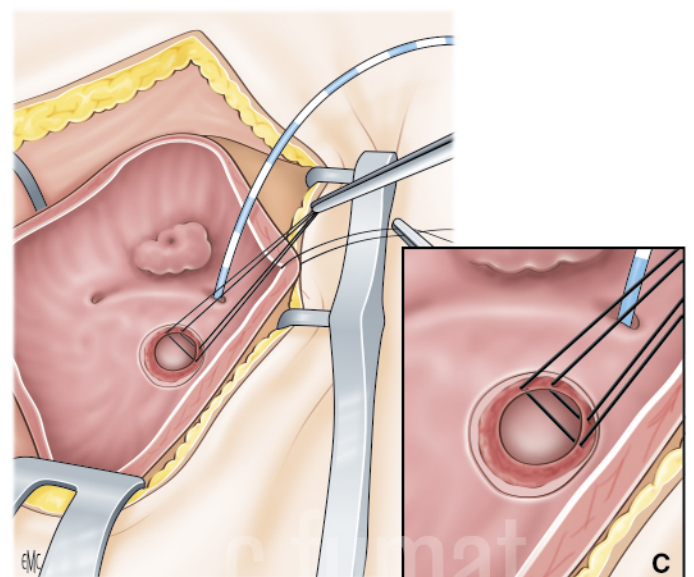
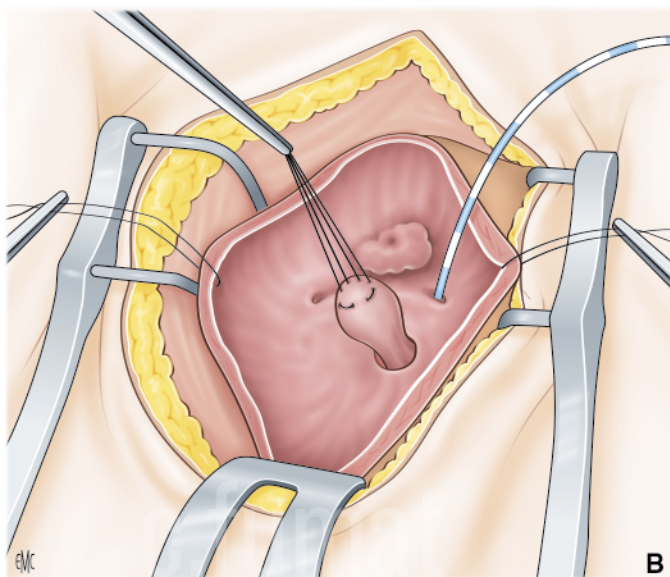
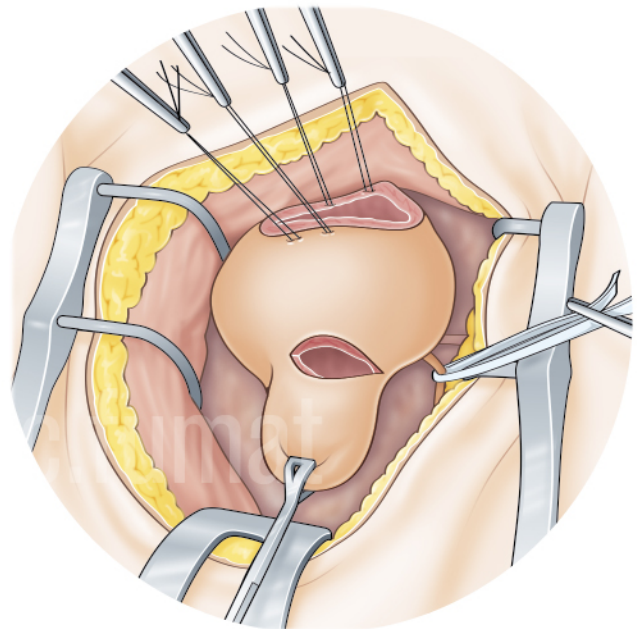
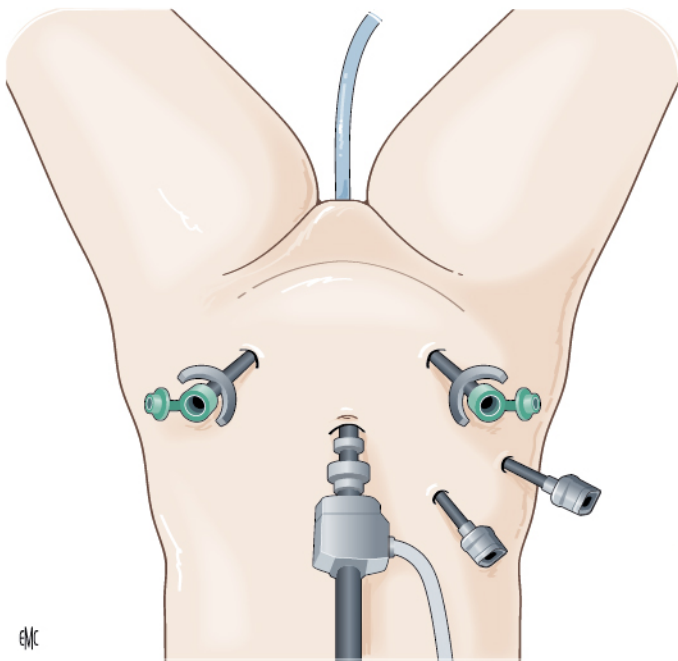
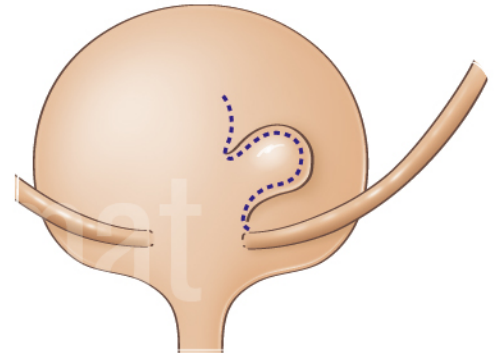
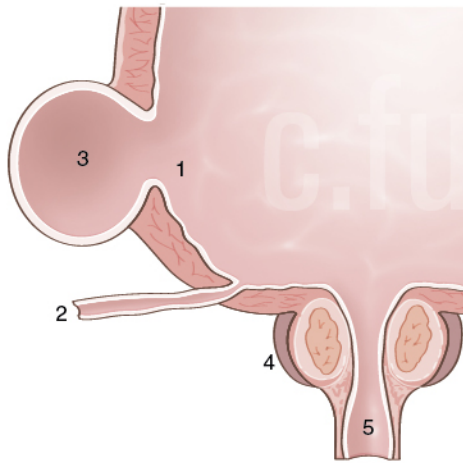
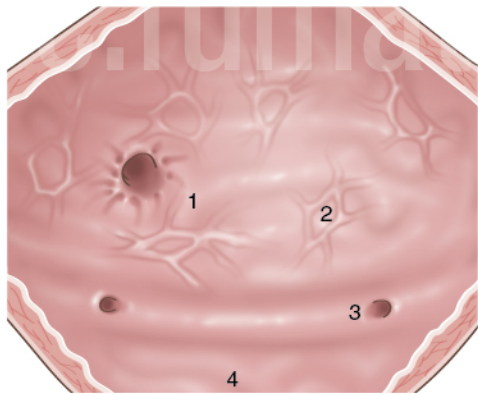


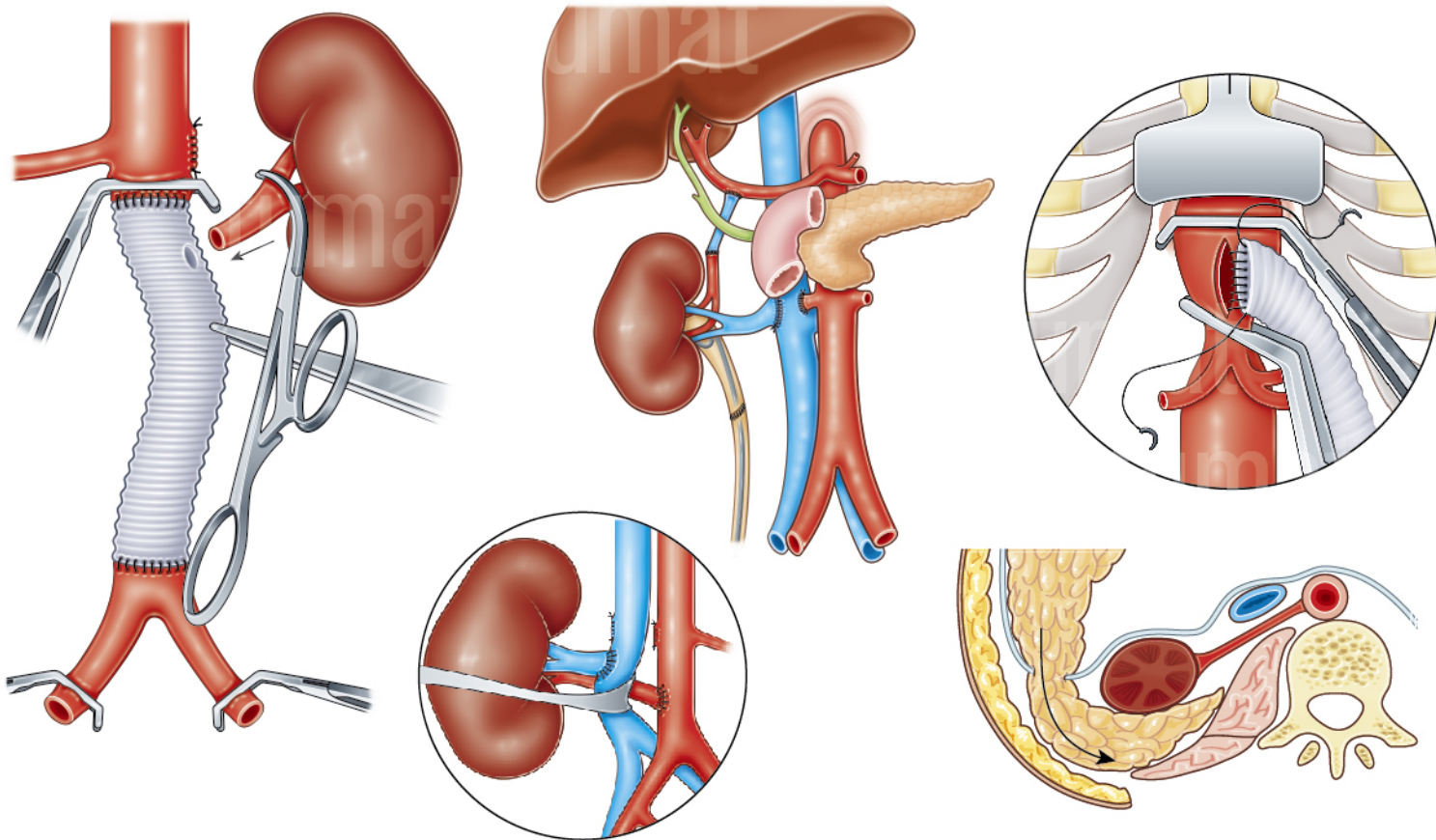
Éditions John Libbey Eurotext



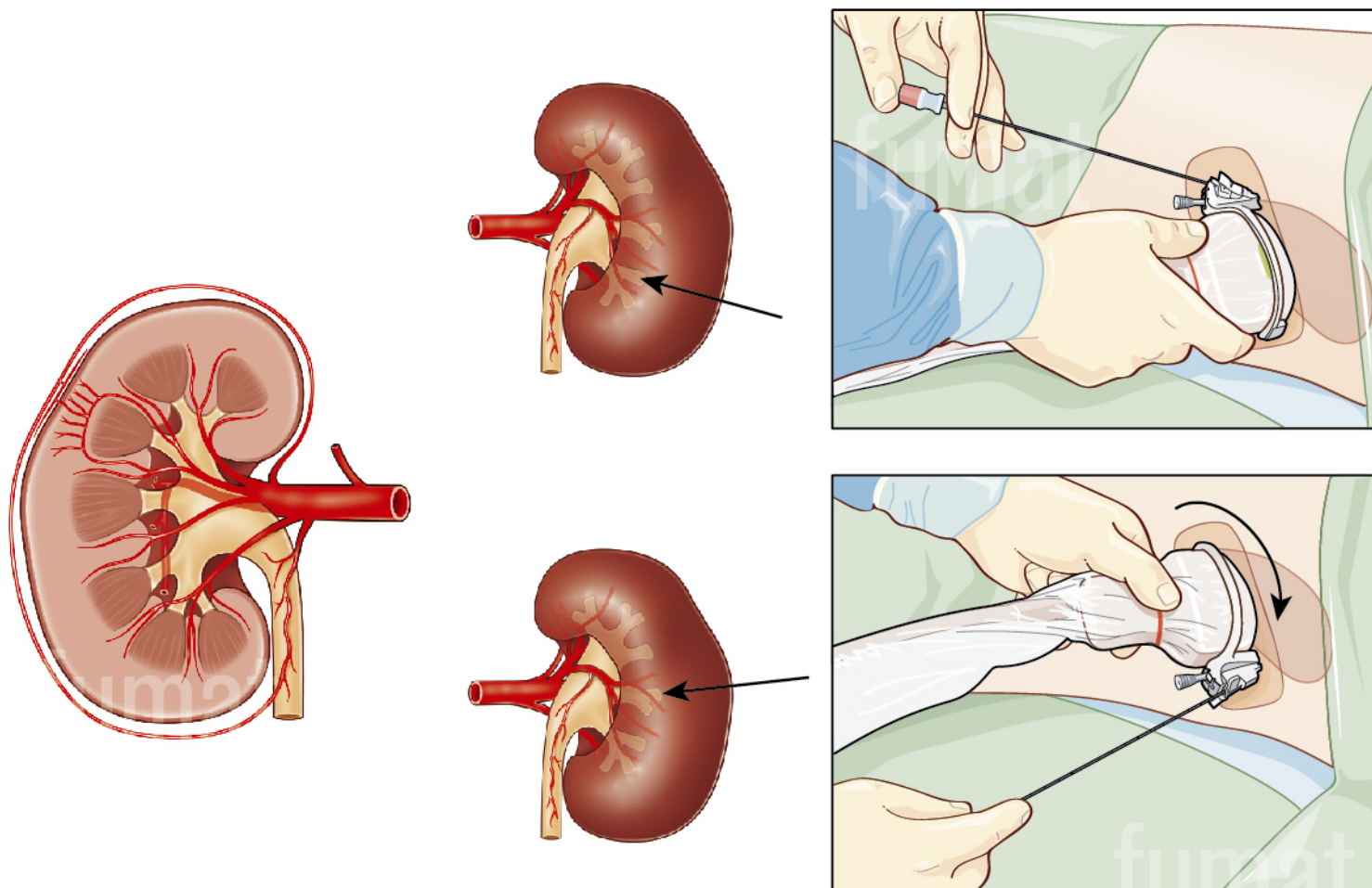
Éditions Med Line



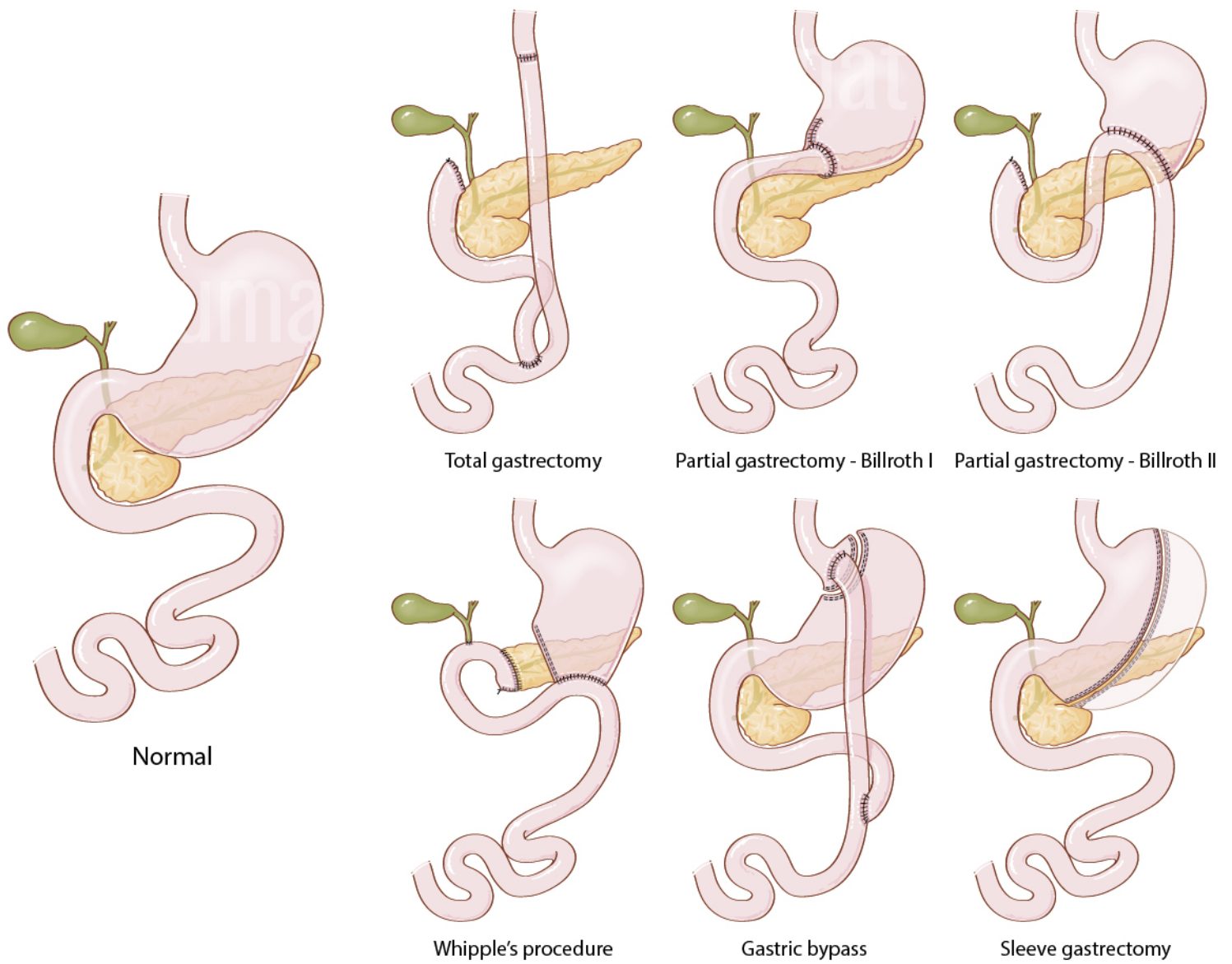




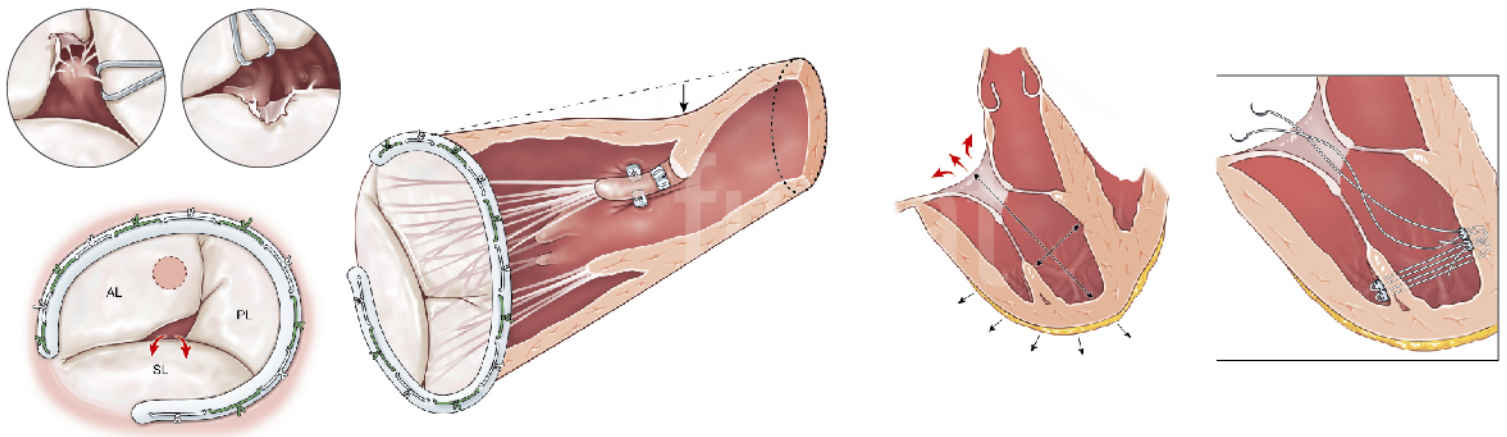
Elsevier Masson - EMC



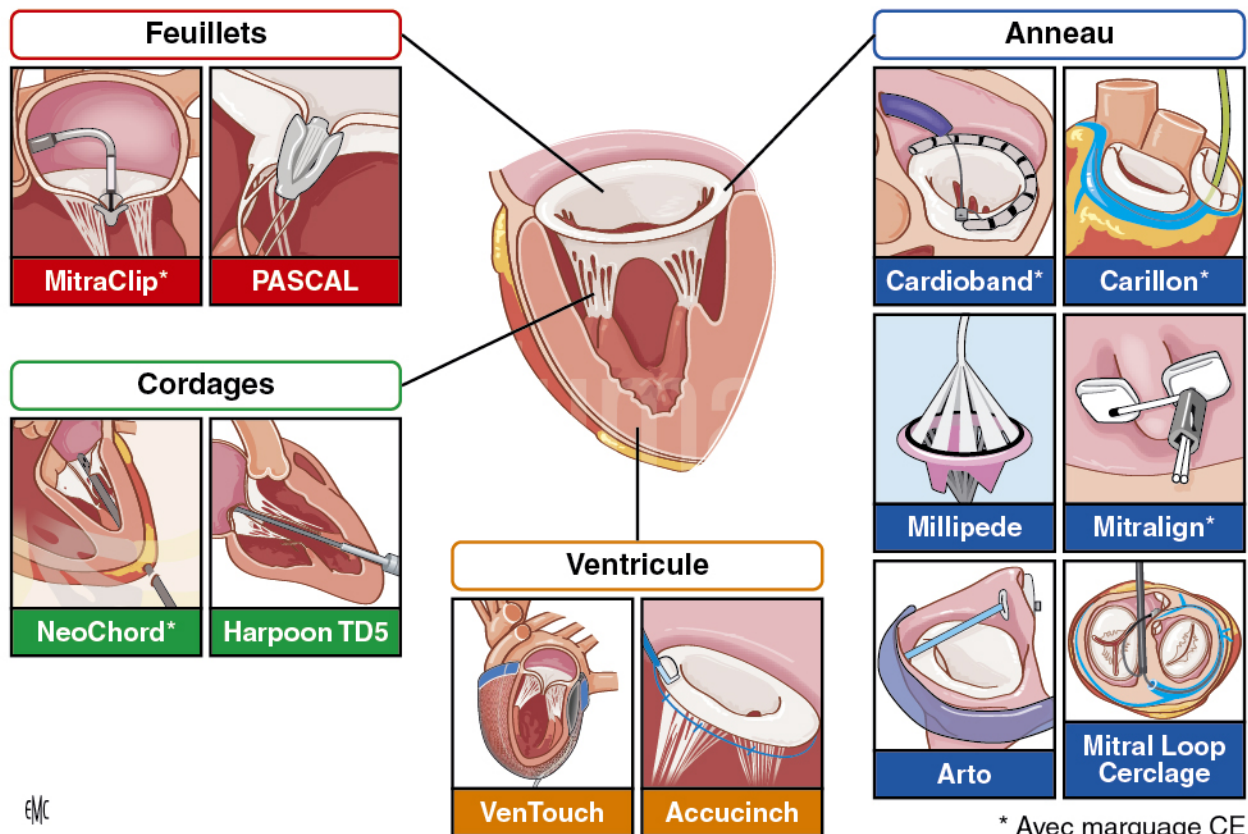
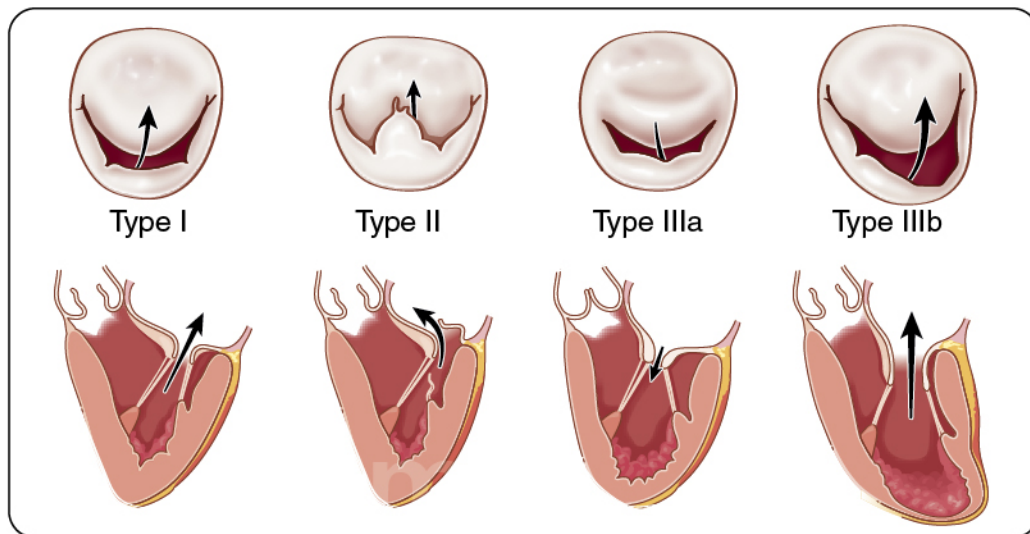




Capsule endoscopy in patients with Surgically Altered Gastric Anatomy (SAGA)	
Completion rate	84.3 %
Retention rate	0.4 %
Small bowel transit time	286 minutes
Small bowel cleanliness rate	92.1 %
Diagnostic yield	43.6 %



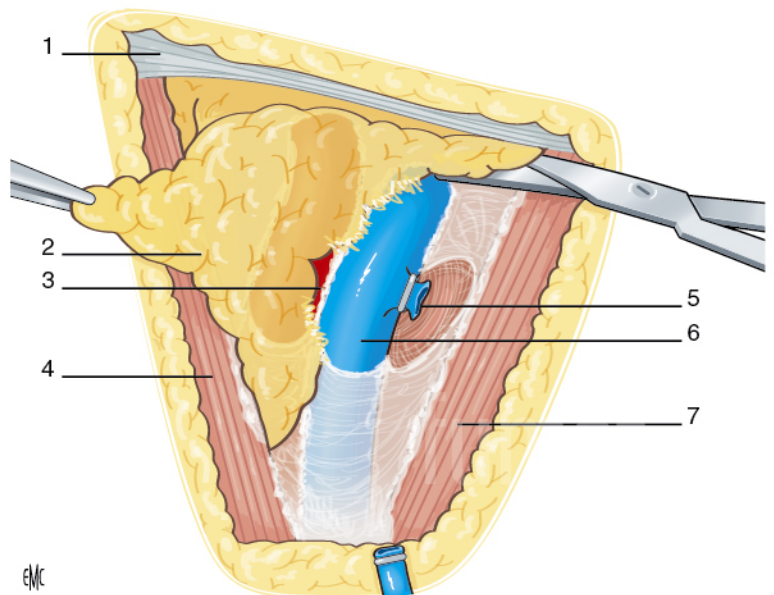
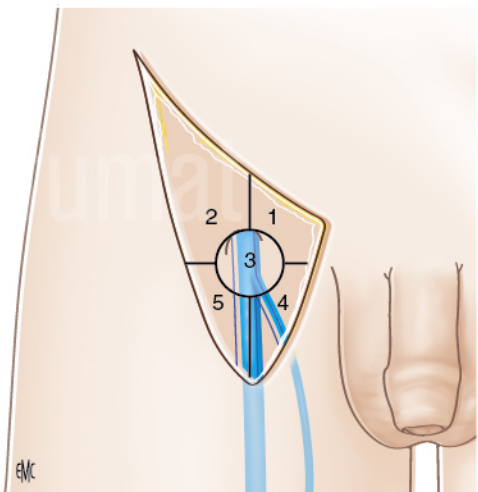
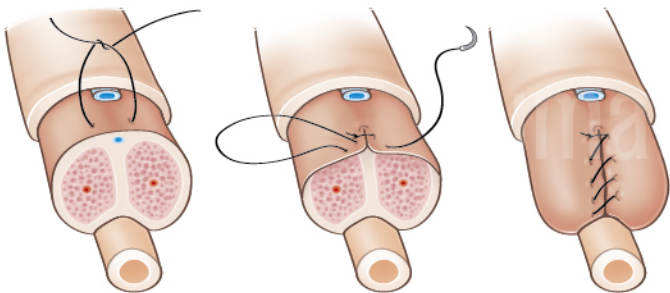
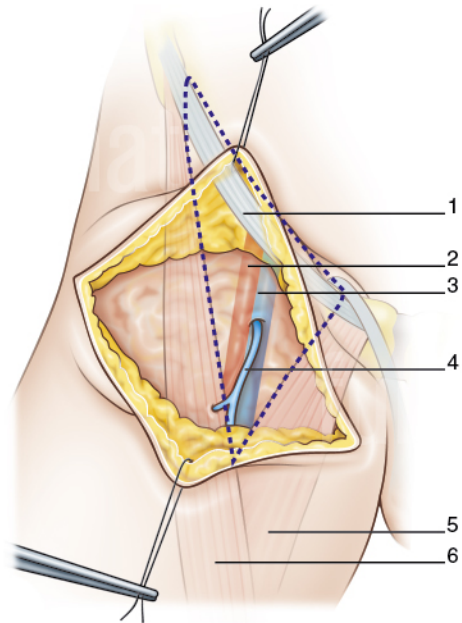
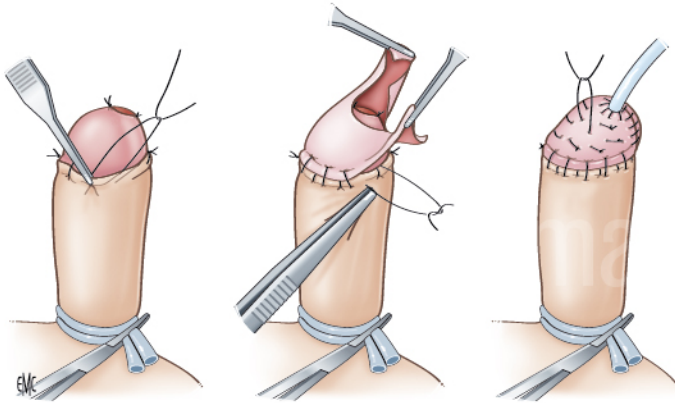
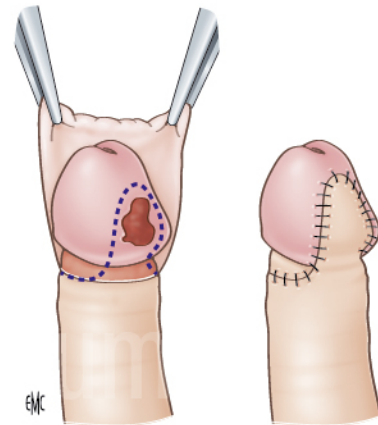
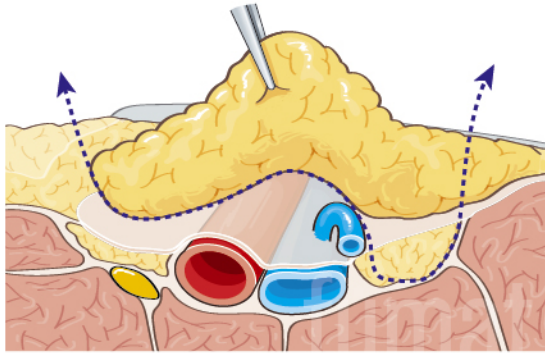
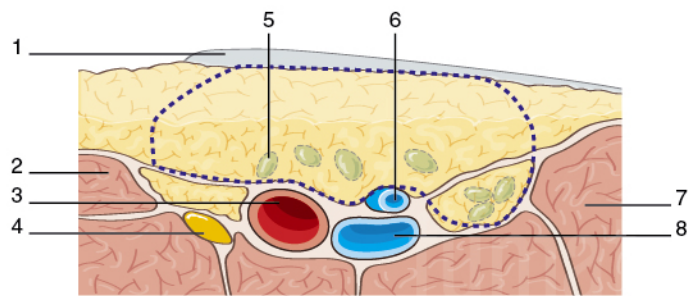
Service cardiologie - CHU Henri Mondor

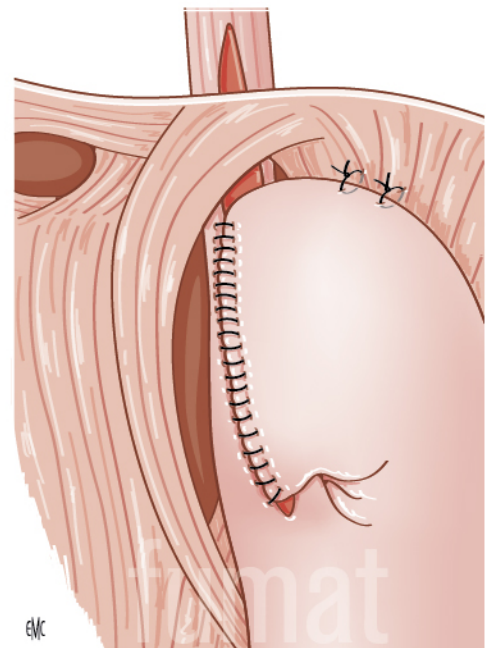
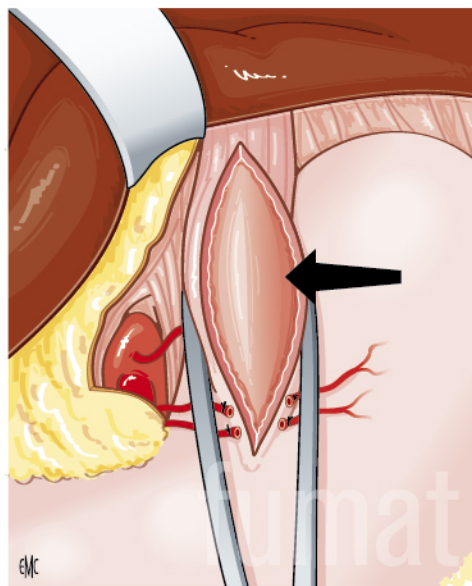
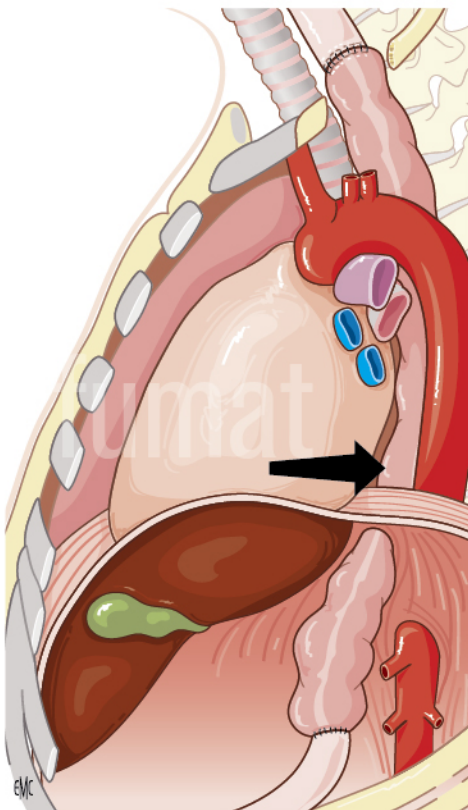
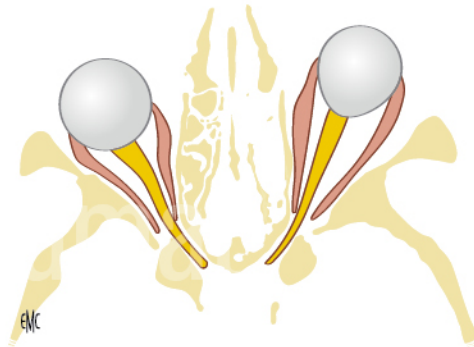
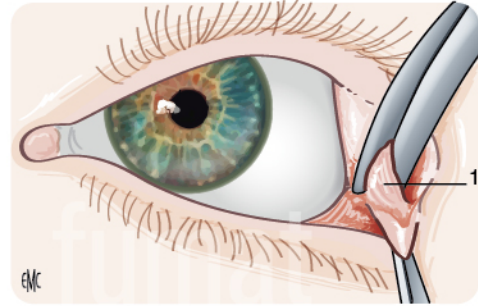
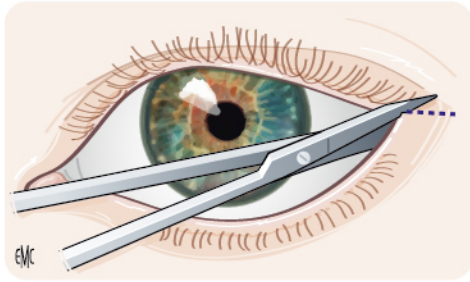
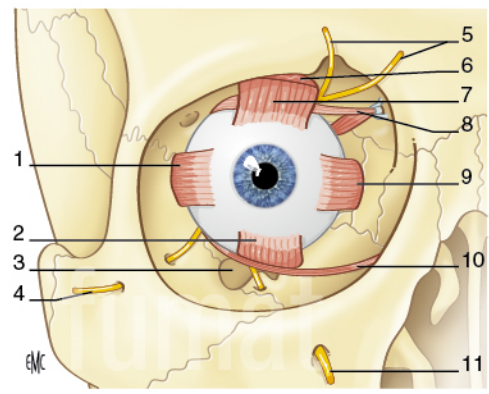
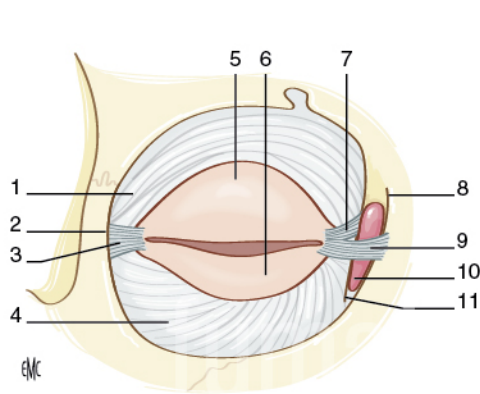


\* Avec marquage CE

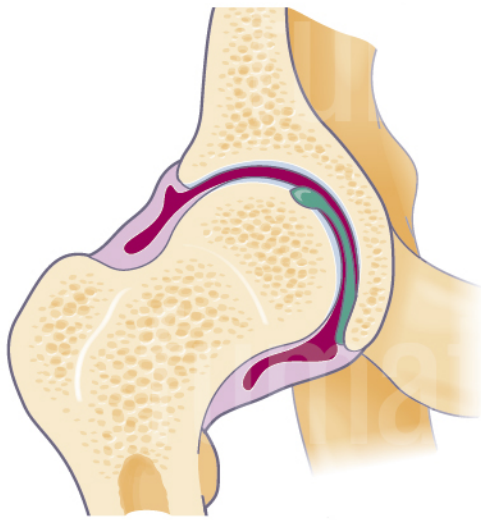
EMC



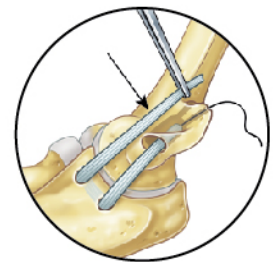
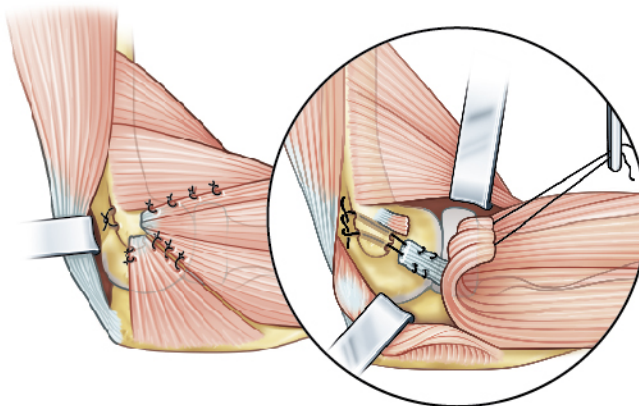
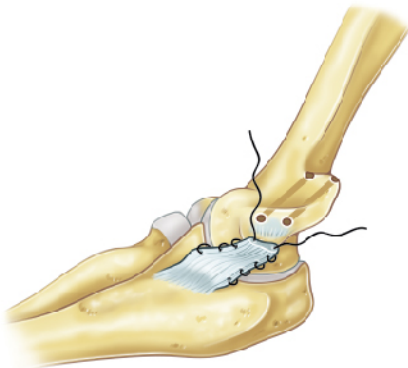
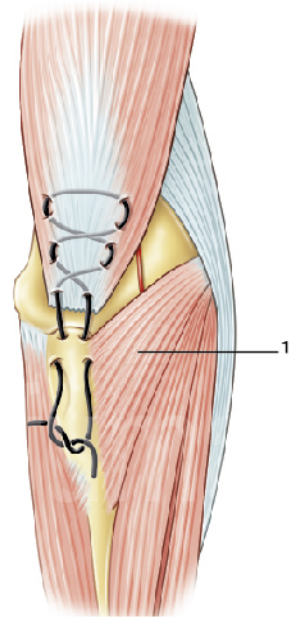
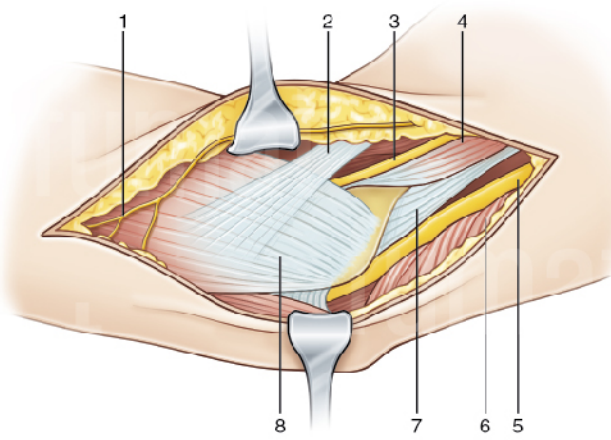
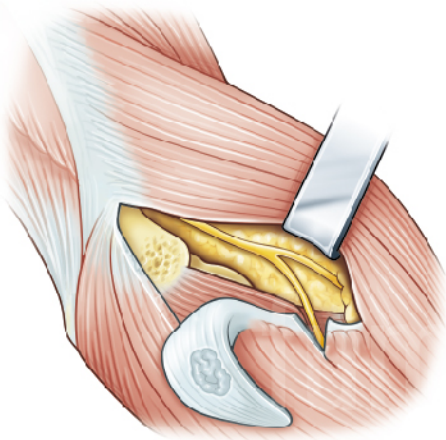




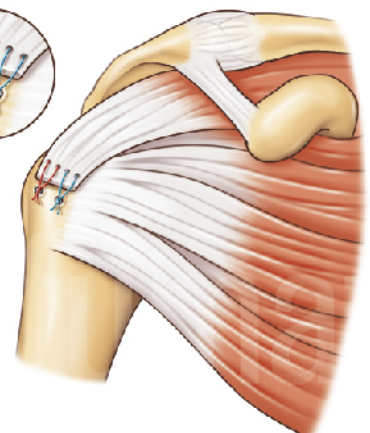
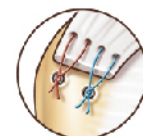
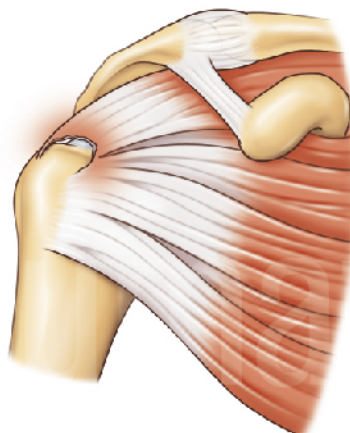
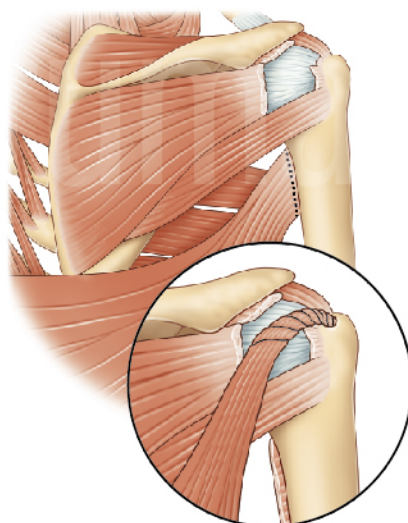




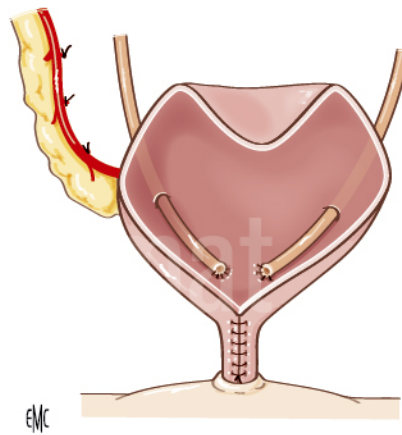
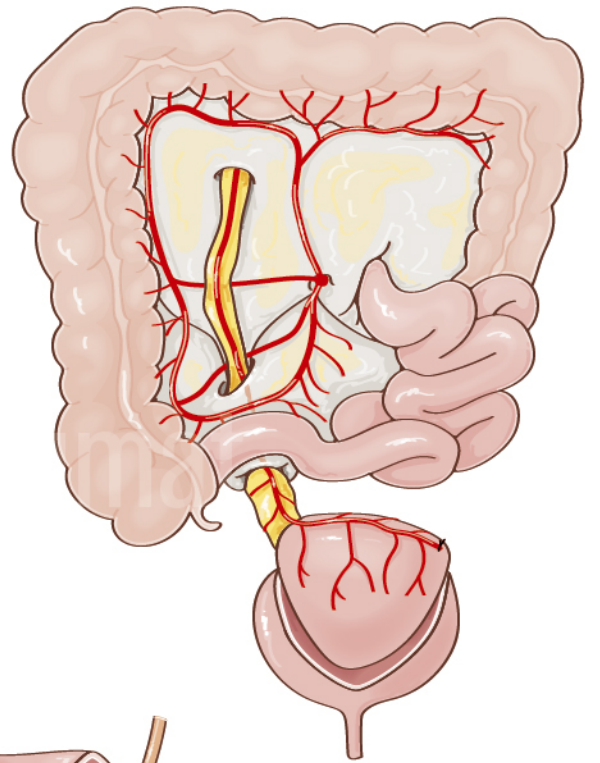
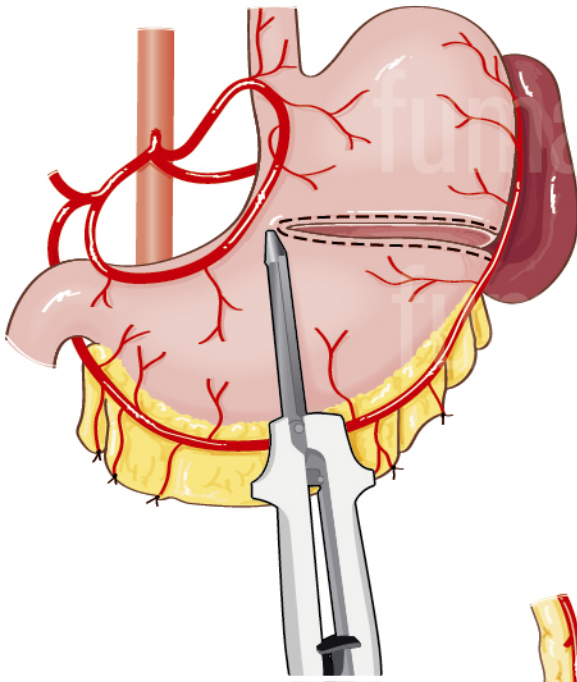
Agence communication santé



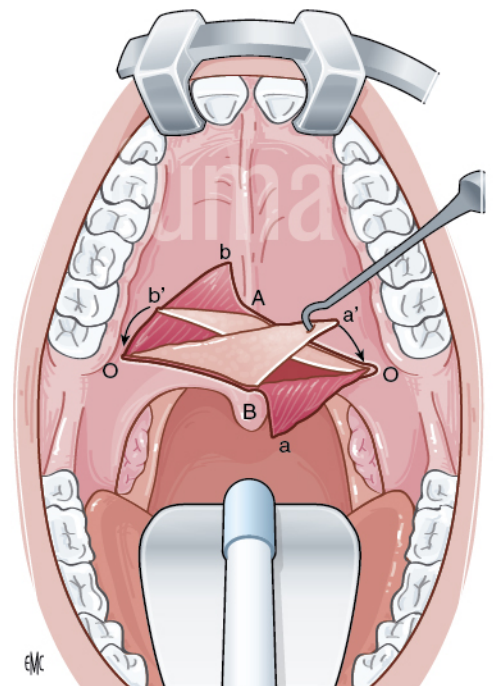
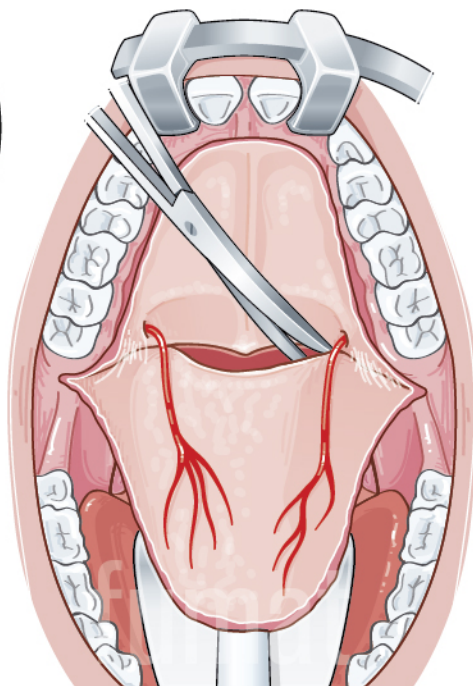
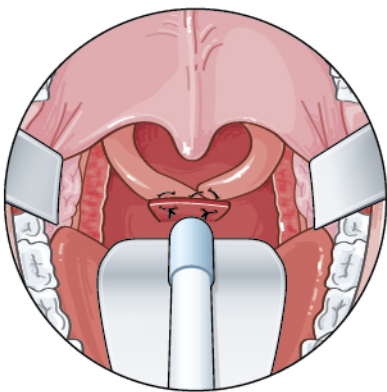
Elsevier Masson - EMC



Sites de chirurgie

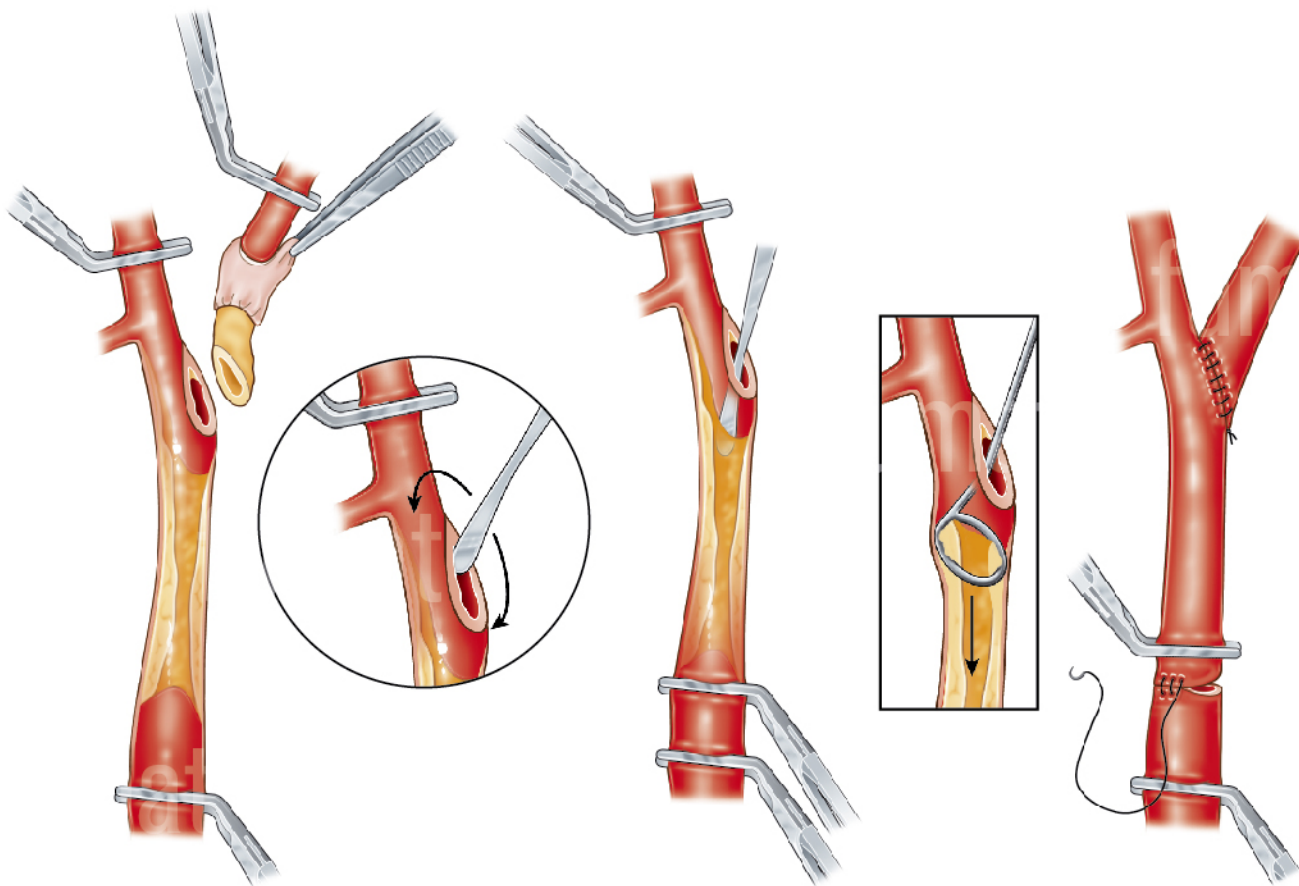


EMC

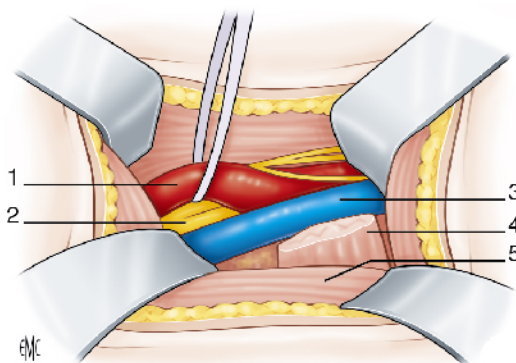
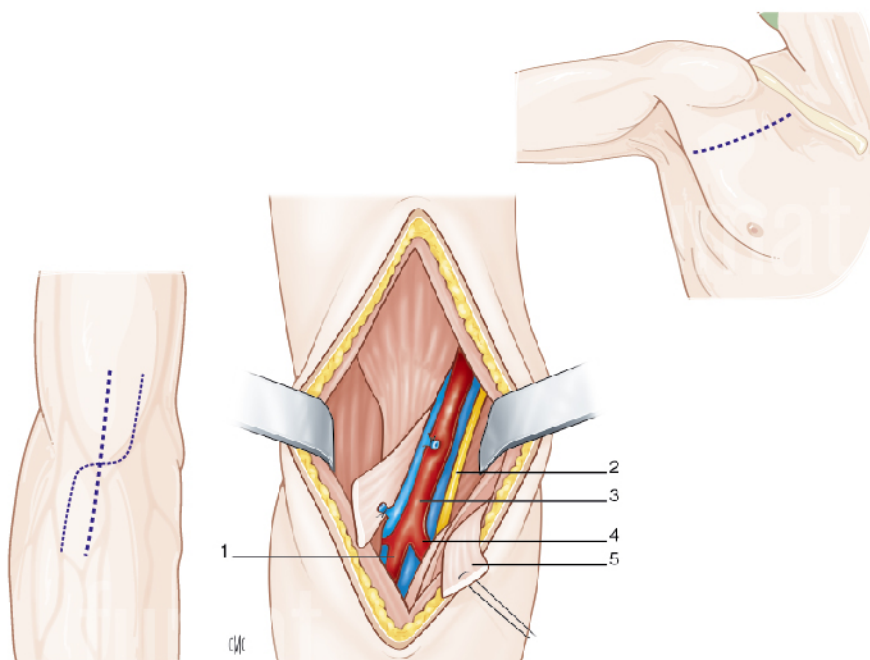
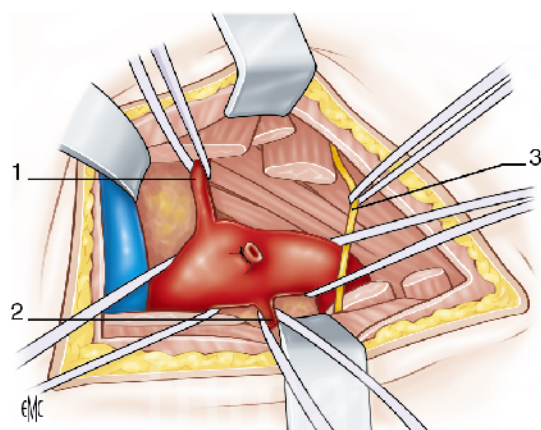
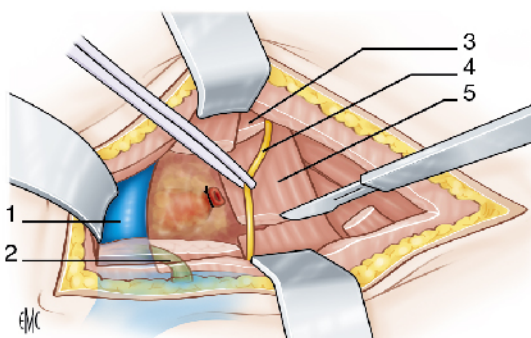
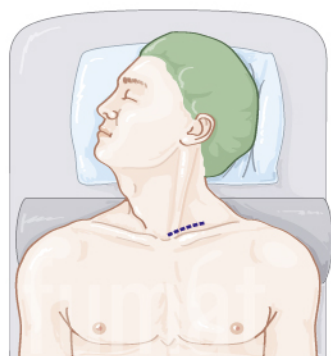


EMC

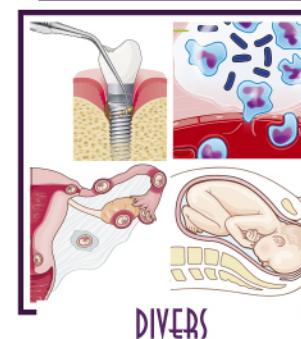
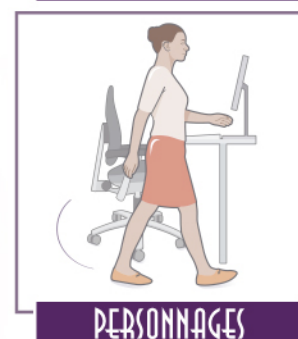
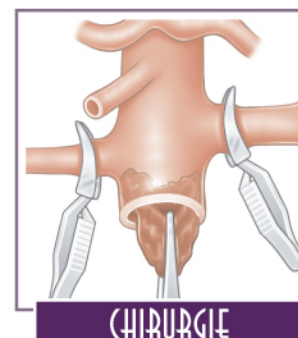
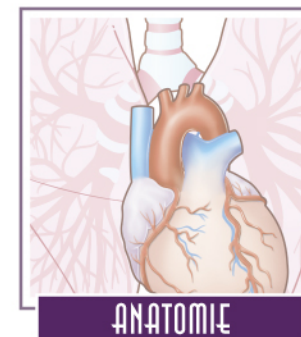
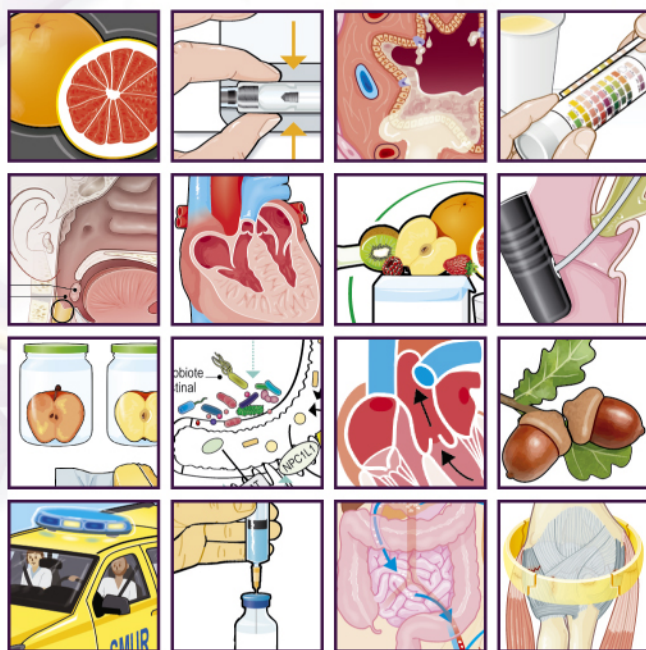




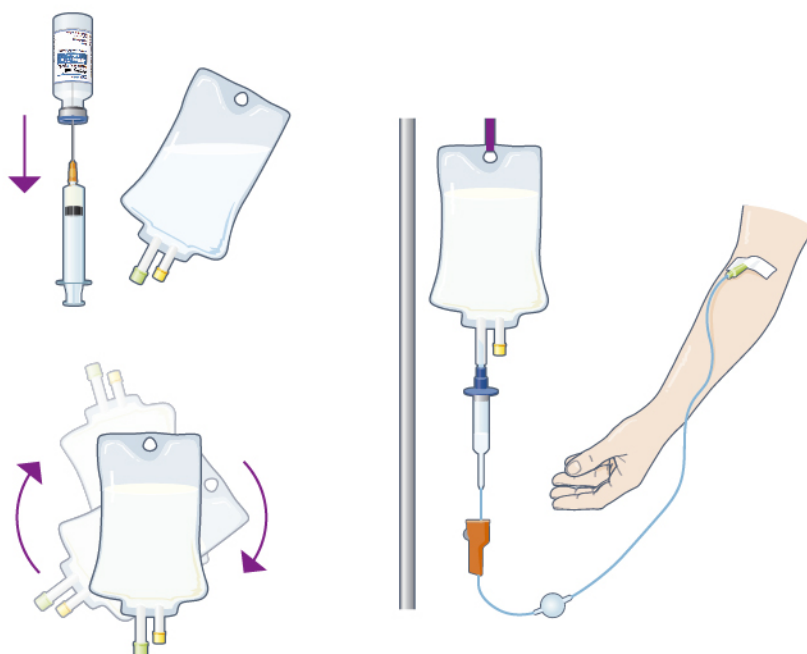
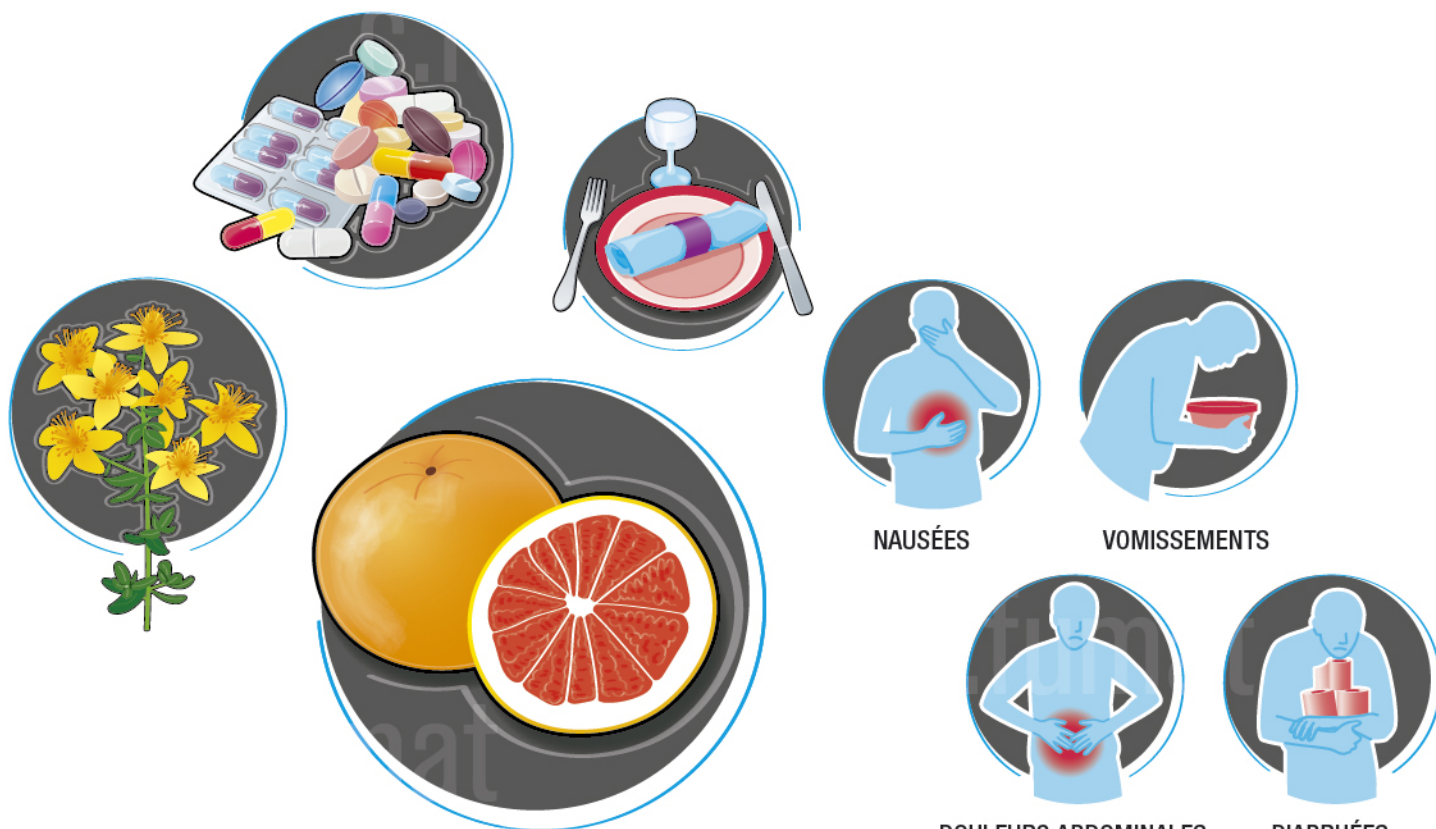
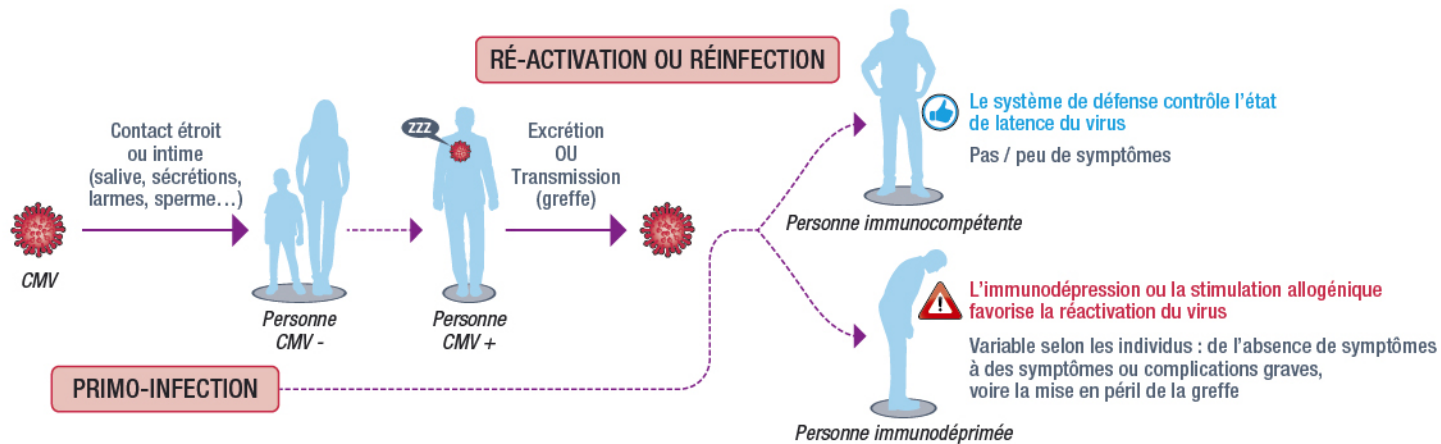
CHU Pitié-Salpêtrière - Service de Chirurgie Vasculaire

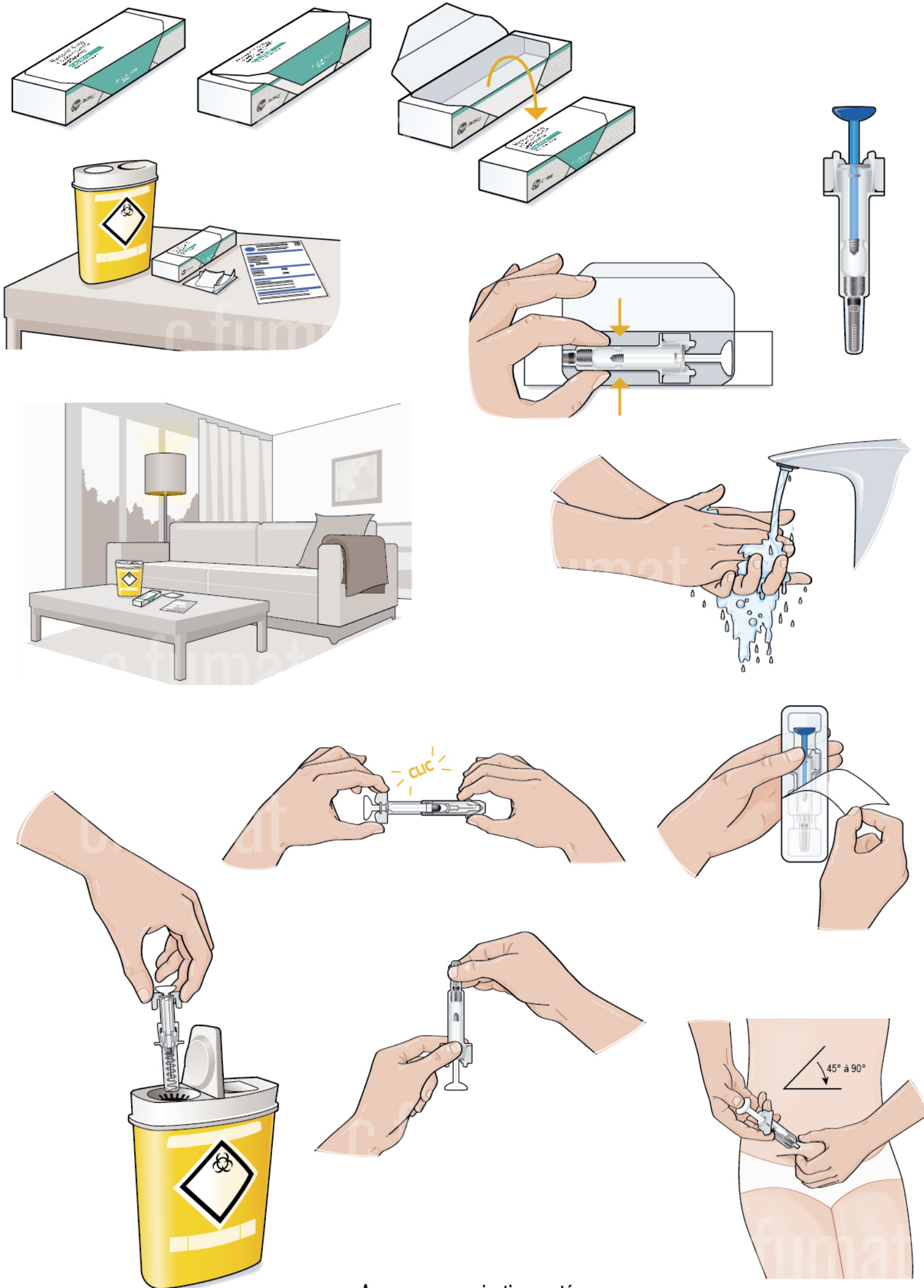


# DIVERS

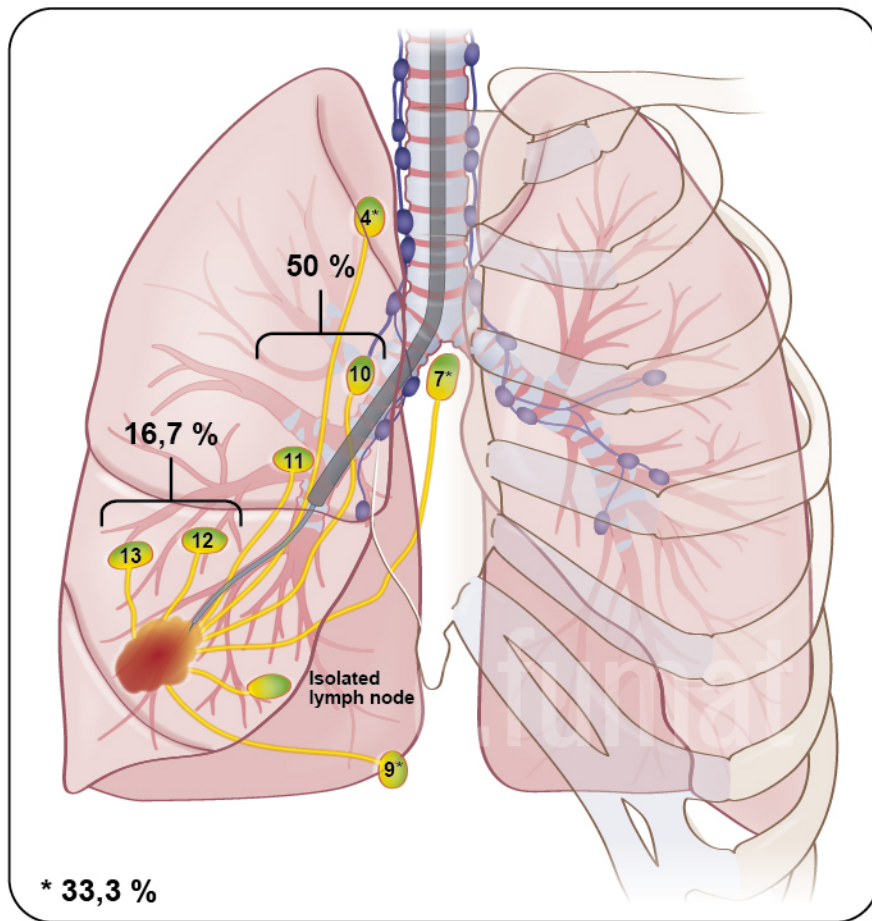




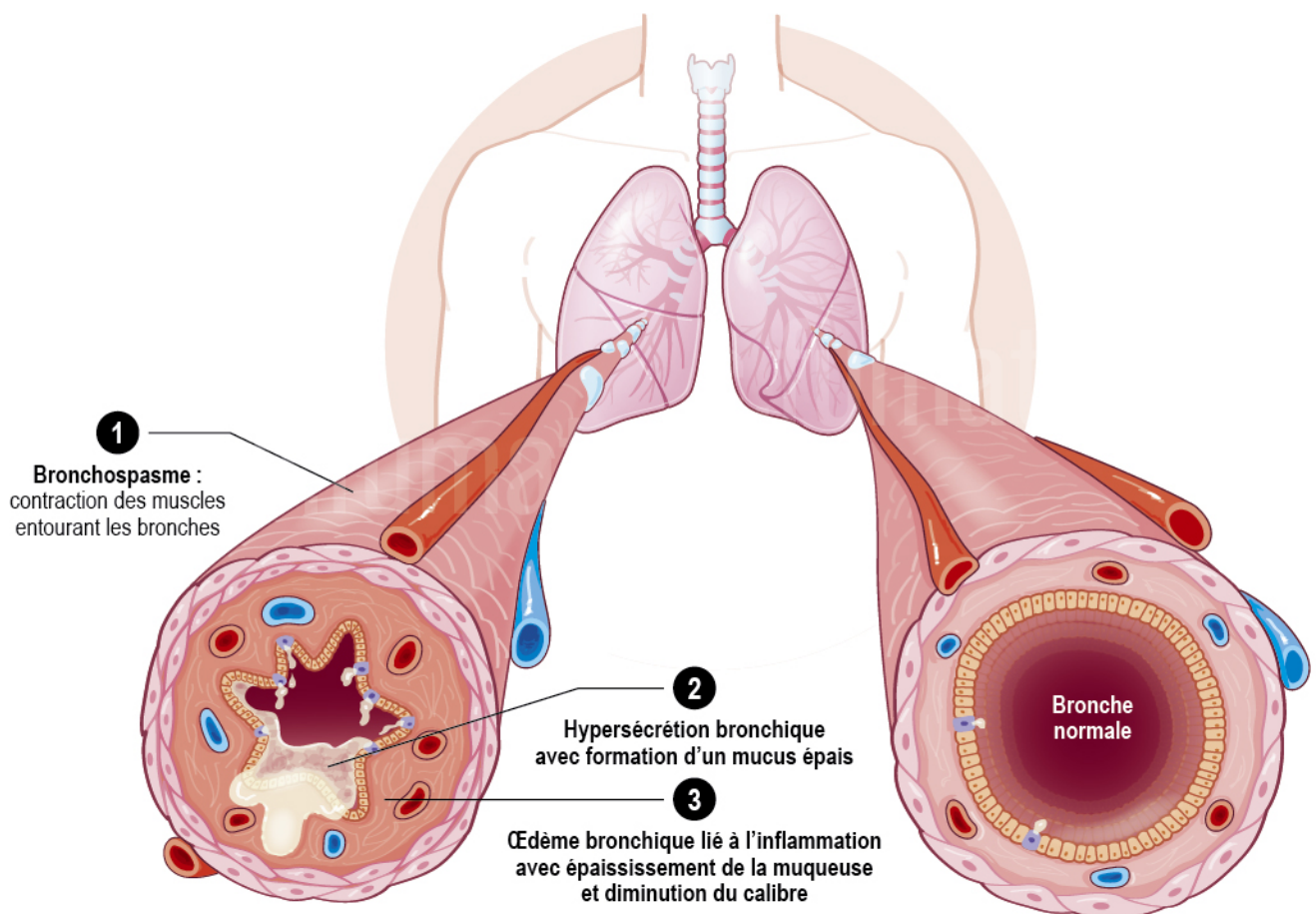


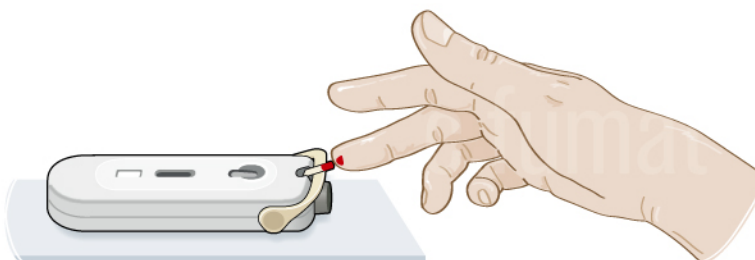
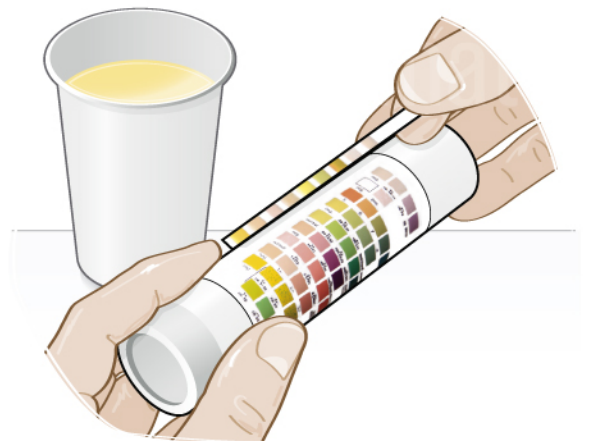
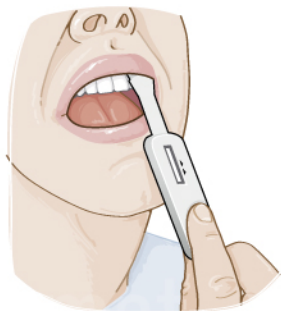
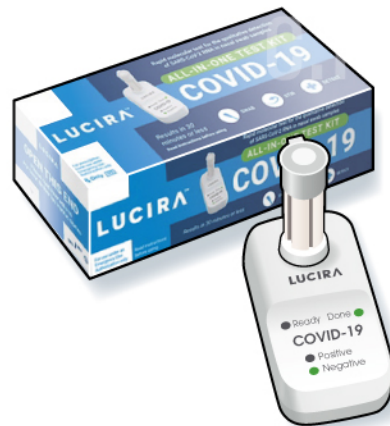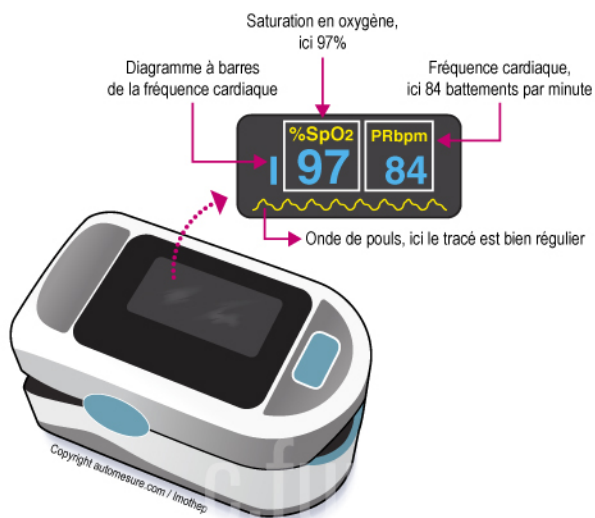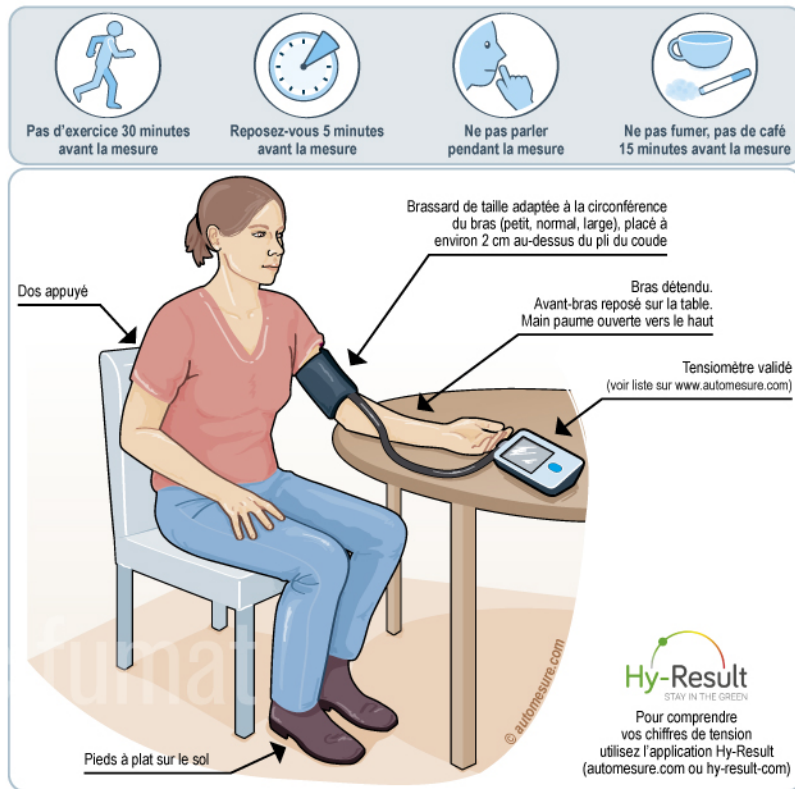




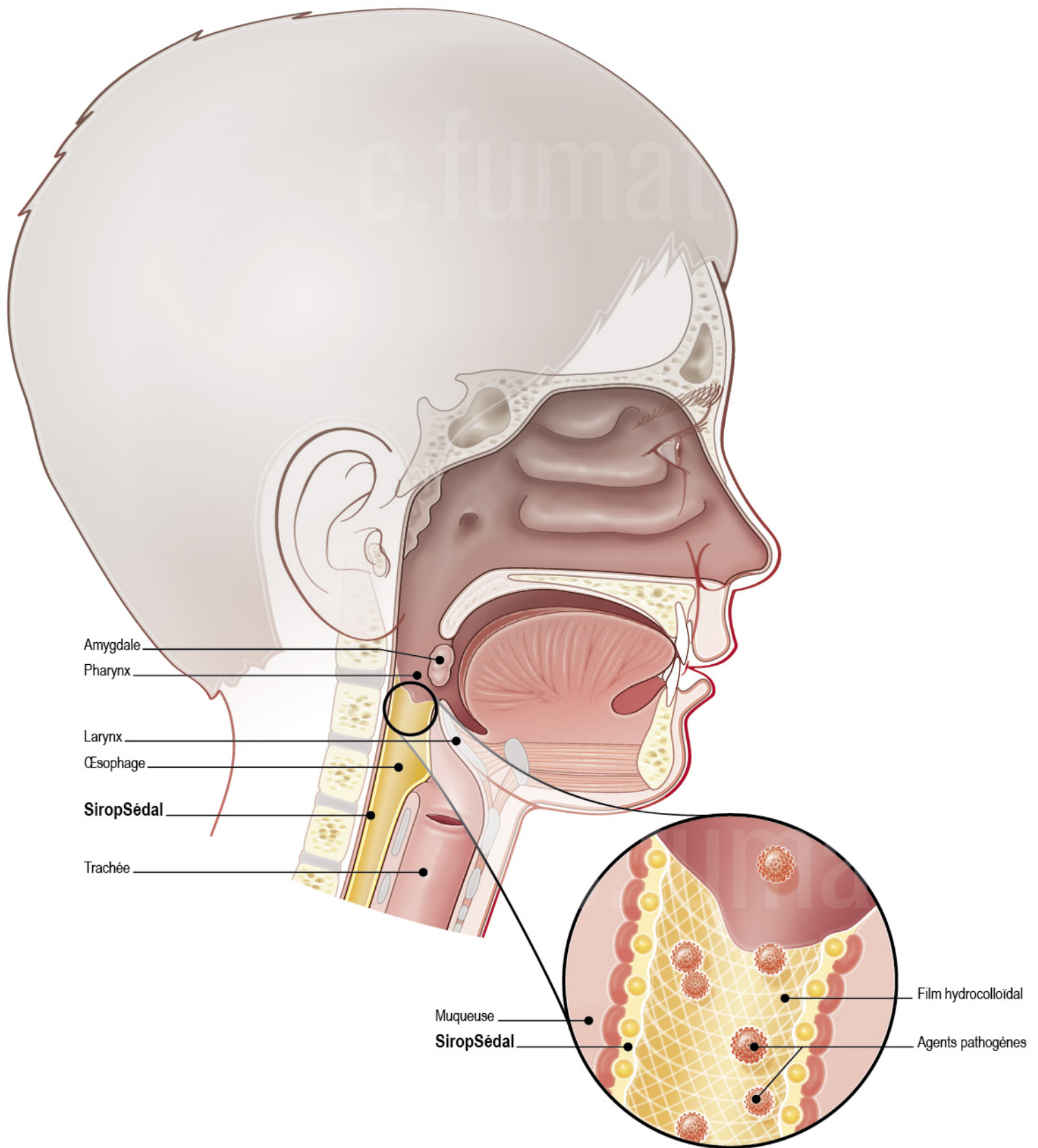


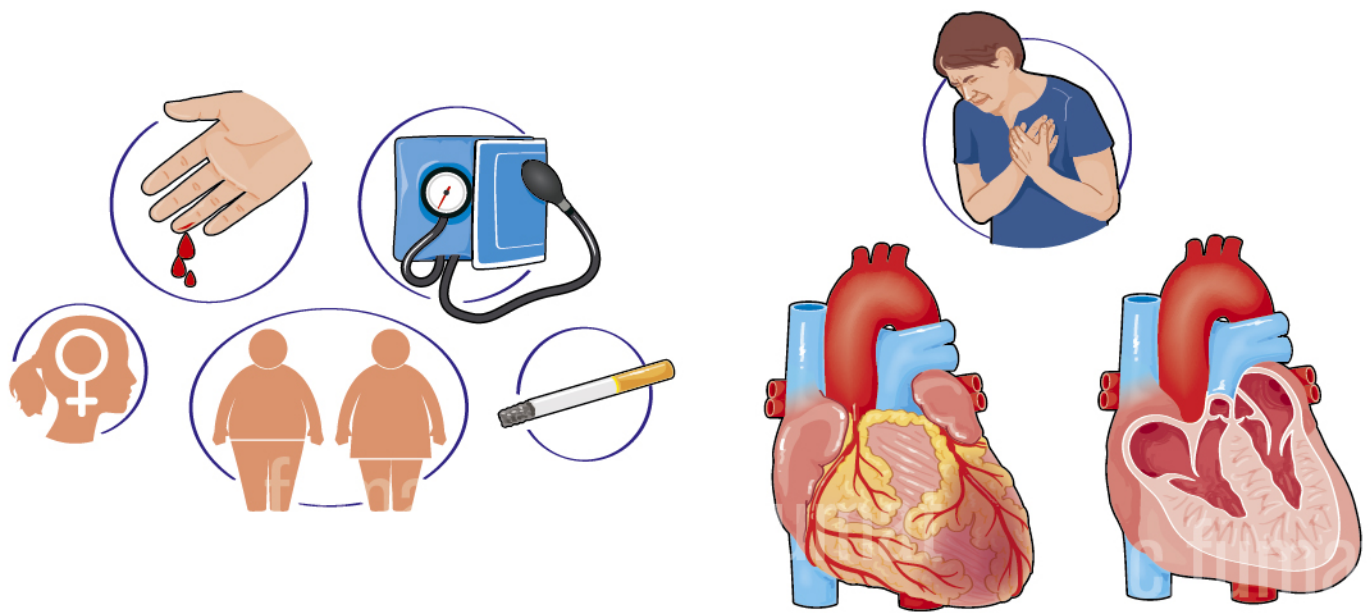
Dr Joseph Seitlinger - CHRU Nancy



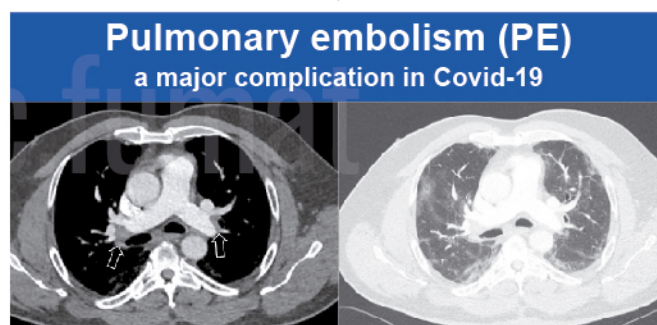
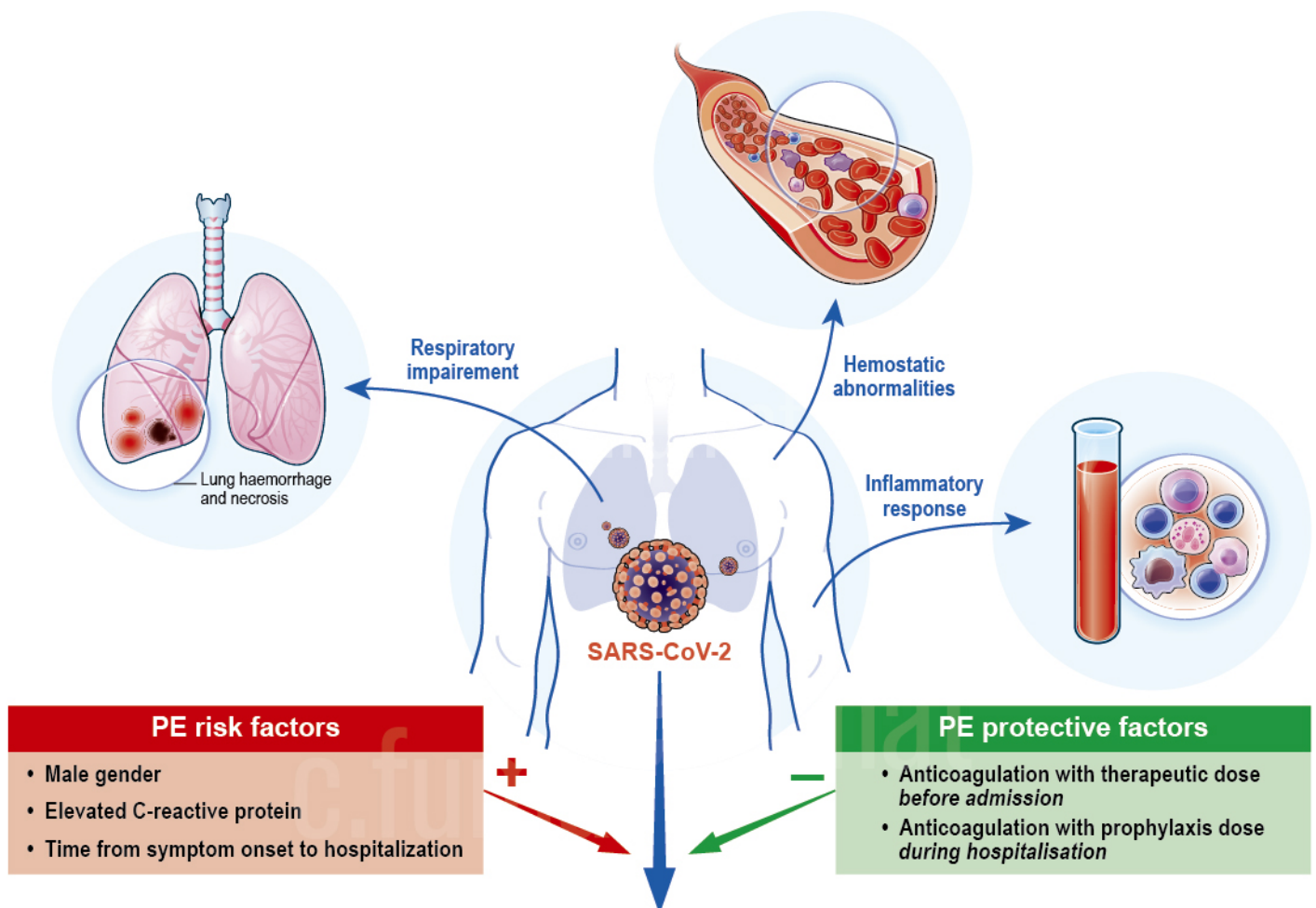




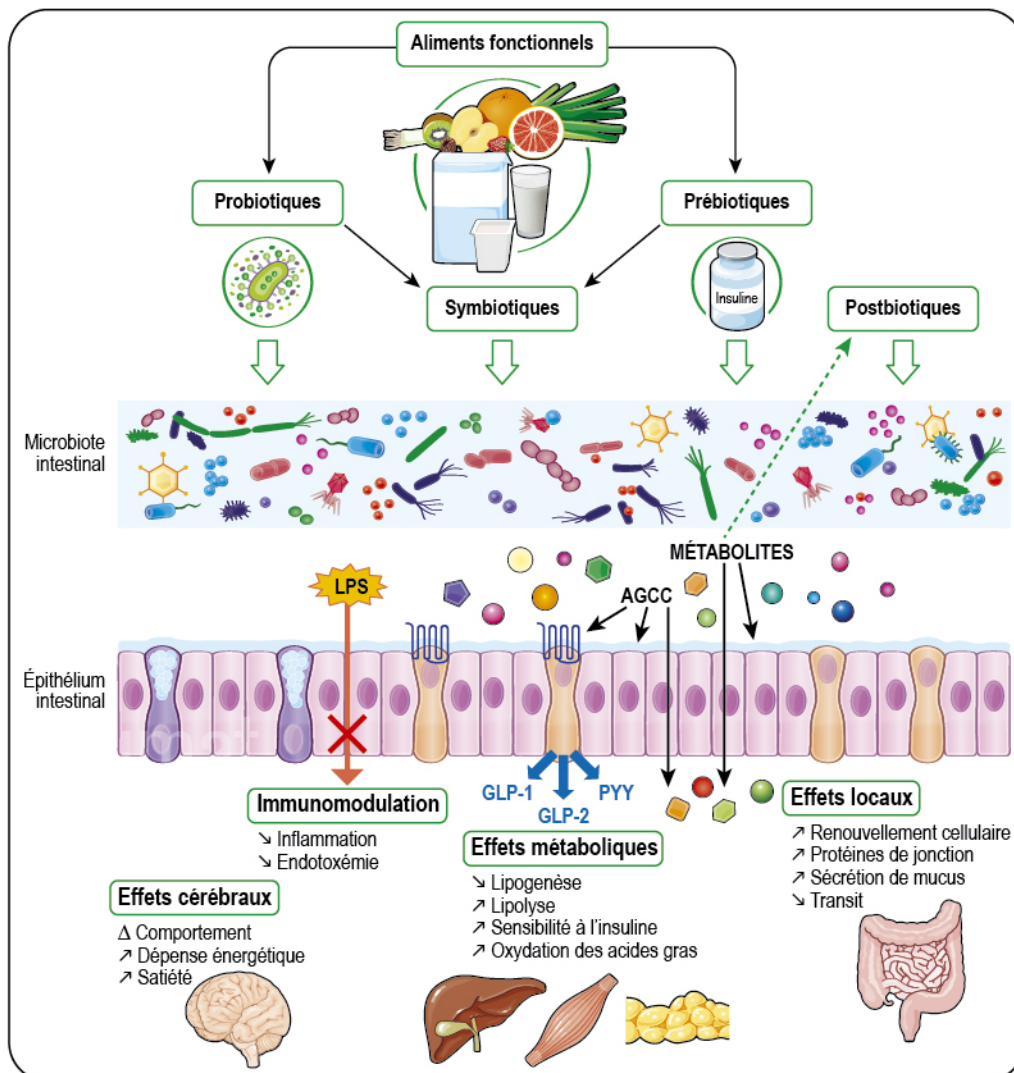
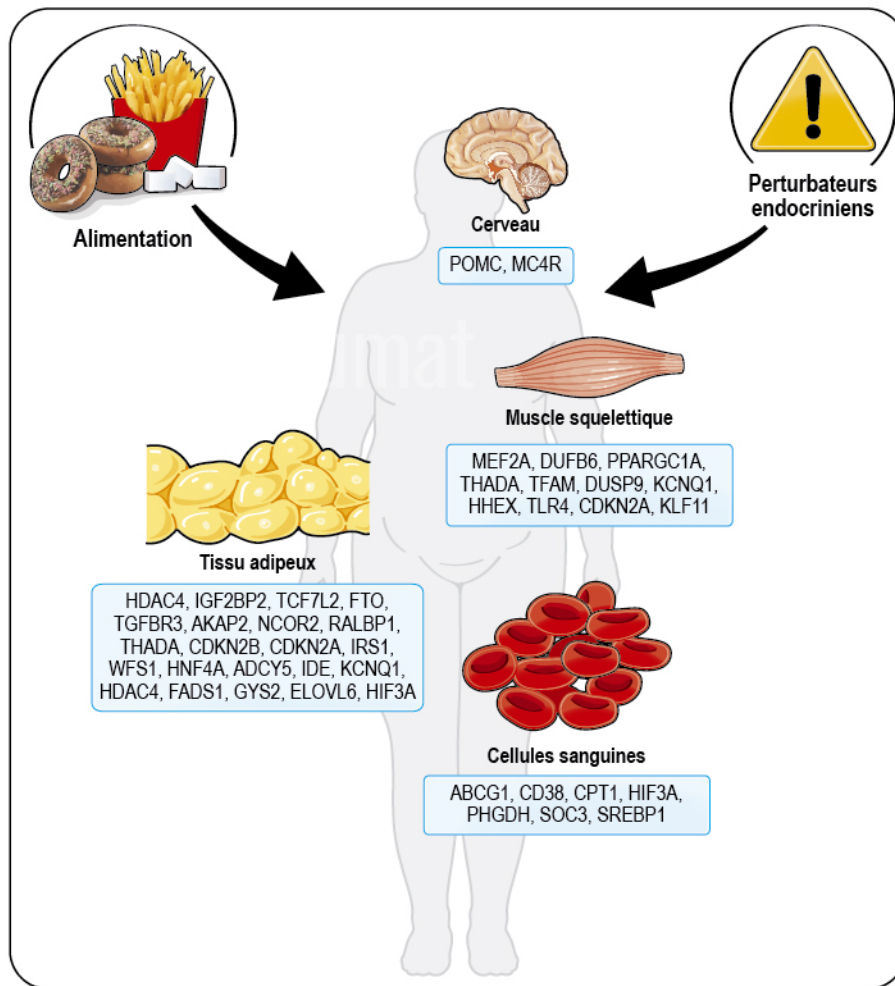


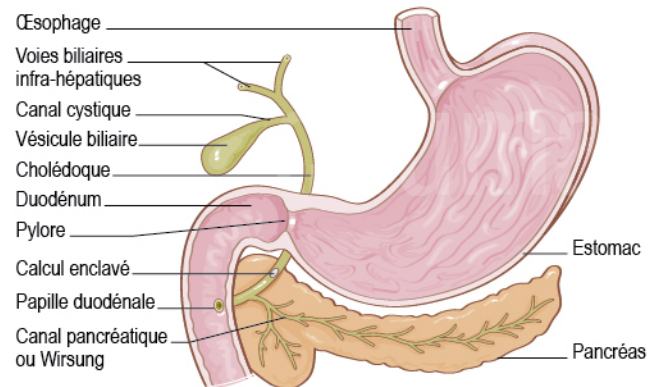
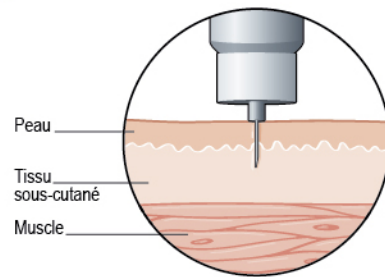
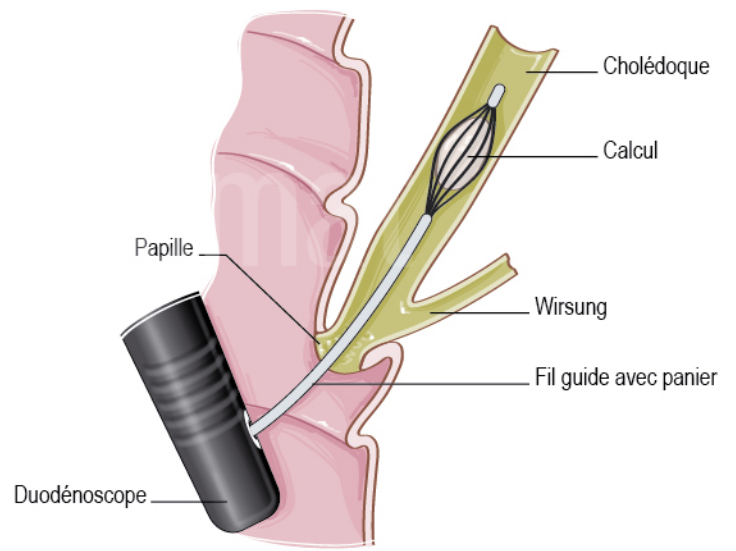
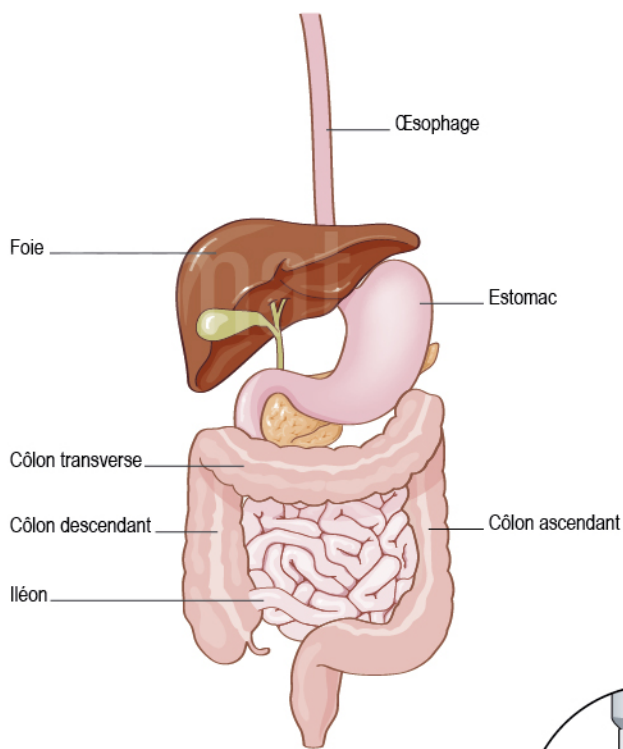


Les laboratoires Servier

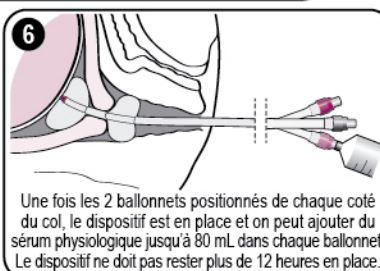
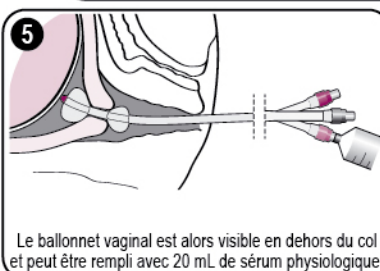
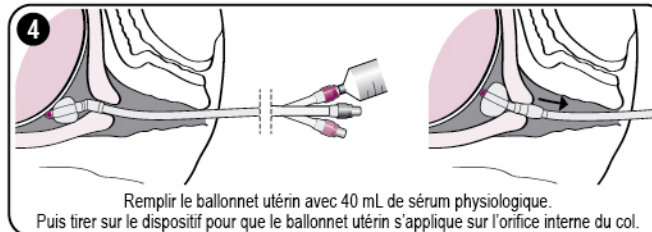
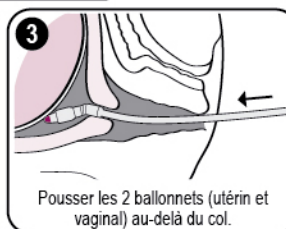
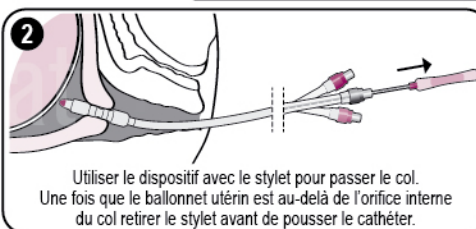
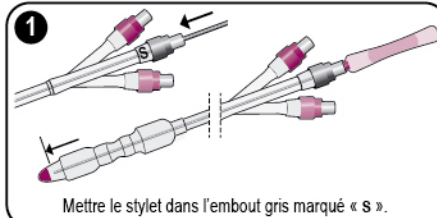




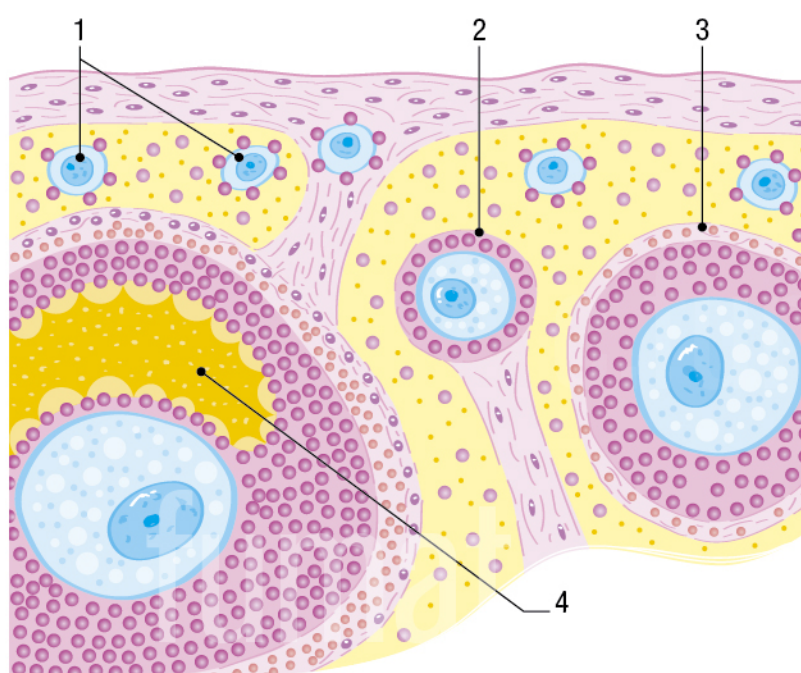
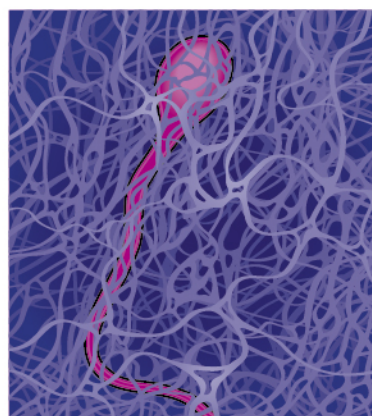
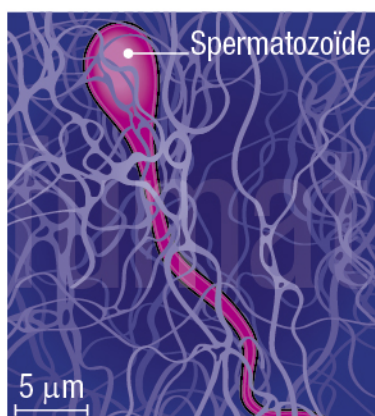
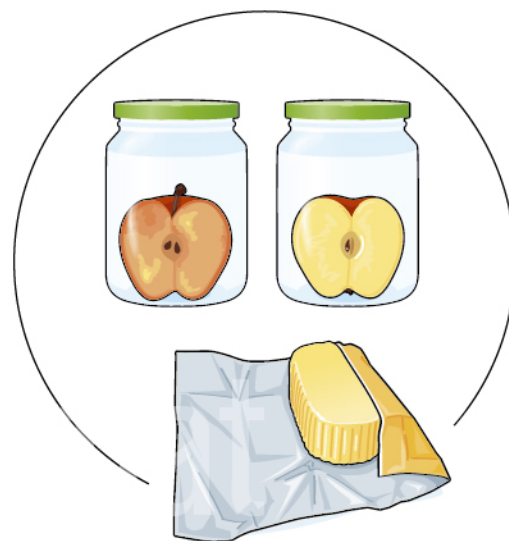
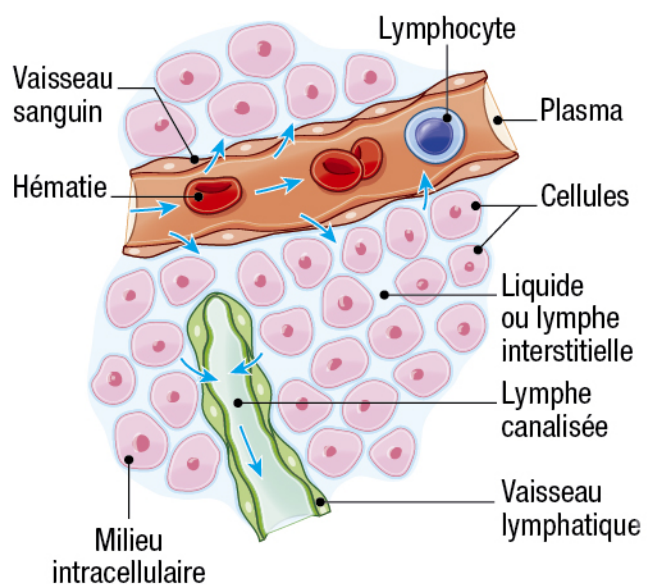




#### Technique de pose du ballonnet de dilatation cervicale

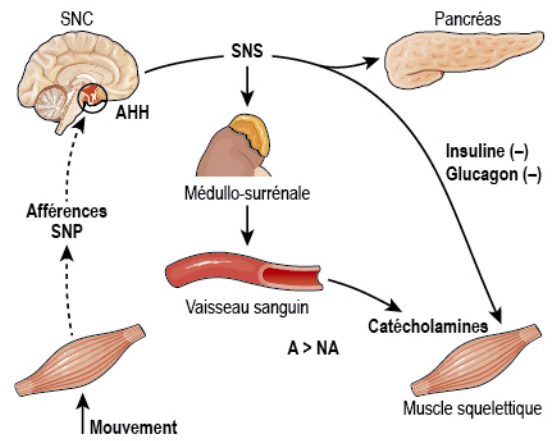
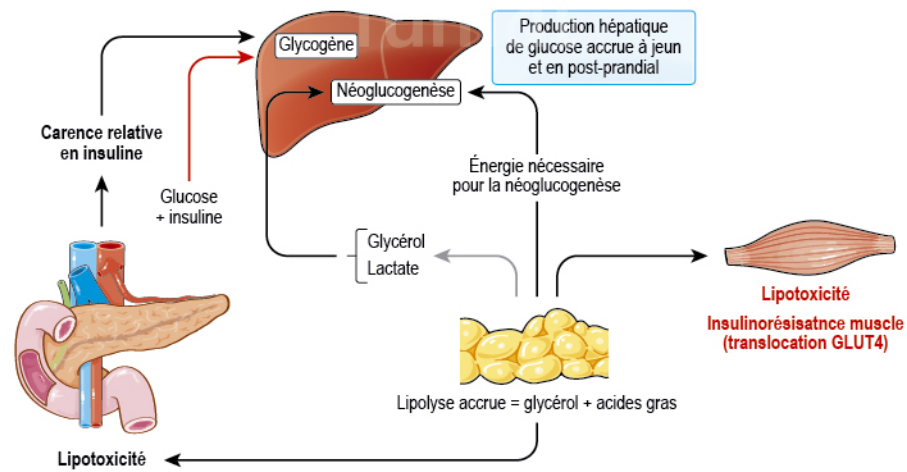




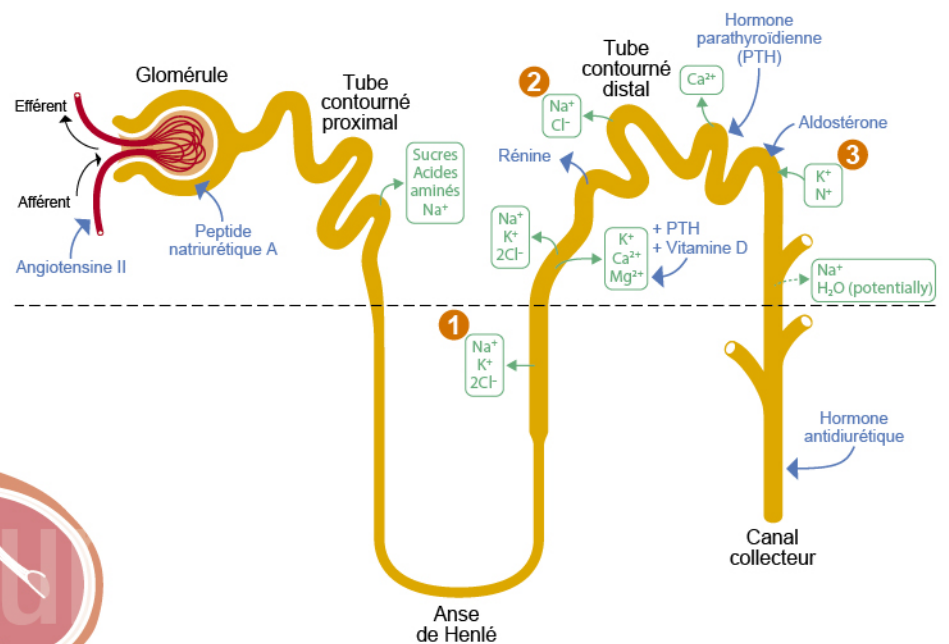
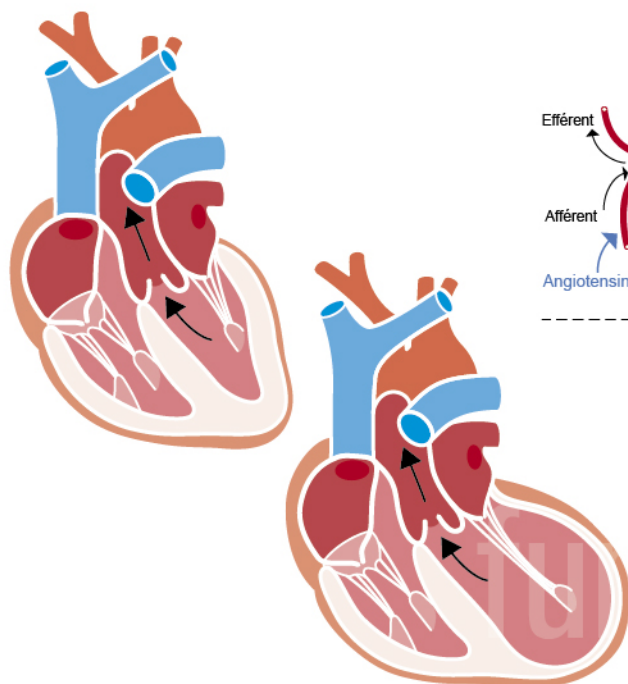
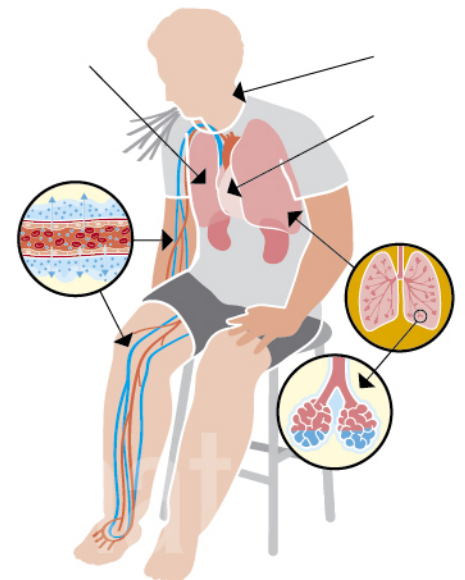
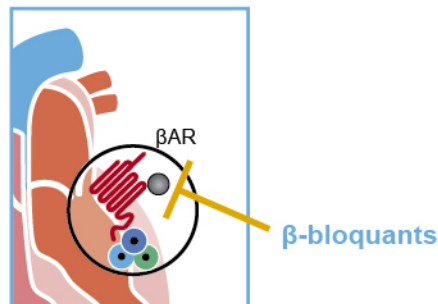
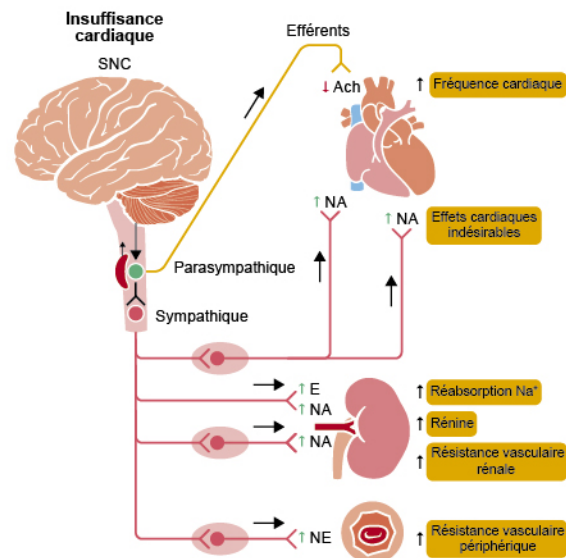




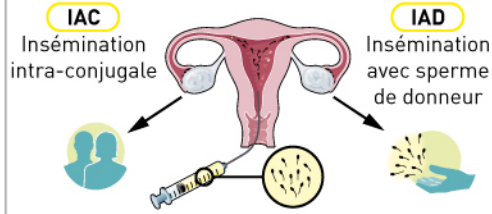




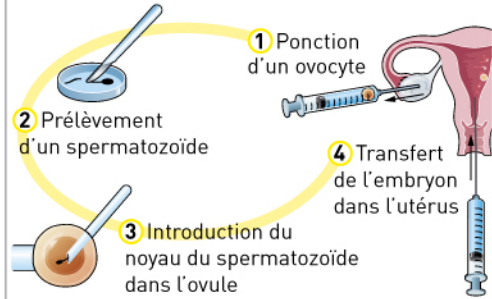
Elsevier Masson



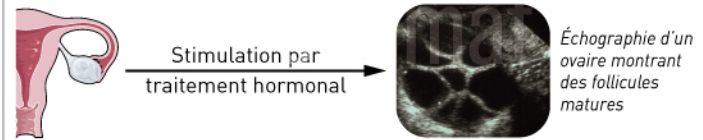### L'insémination artificielle (quand les spermatozoïdes sont anormaux et/ou peu mobiles)



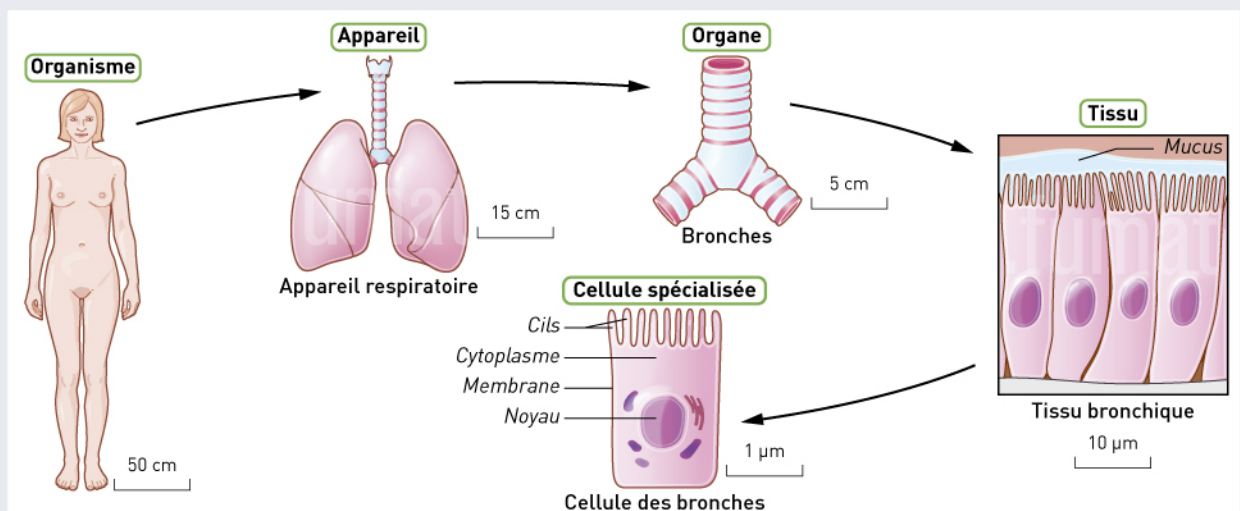
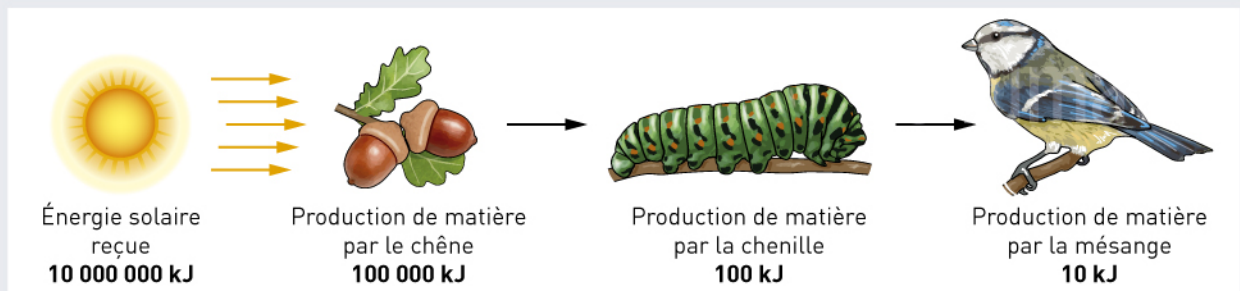
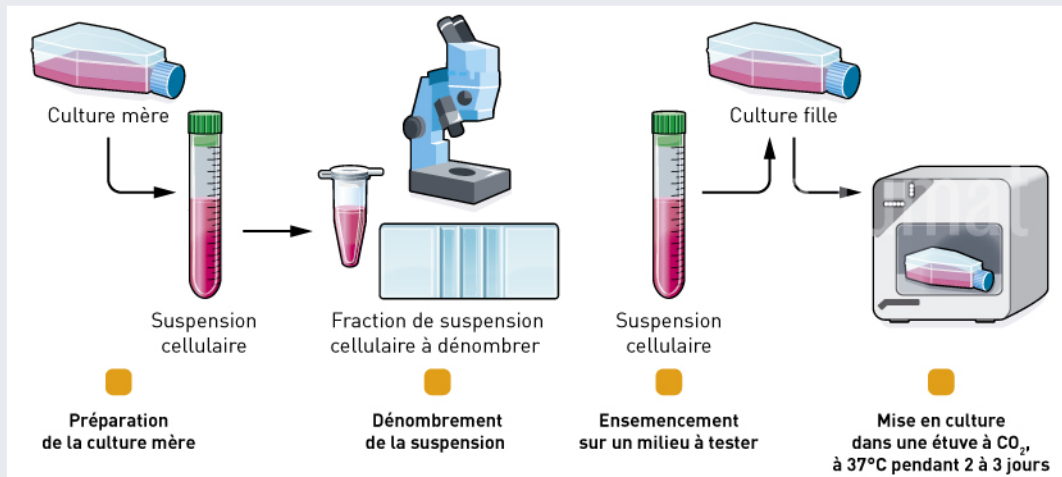
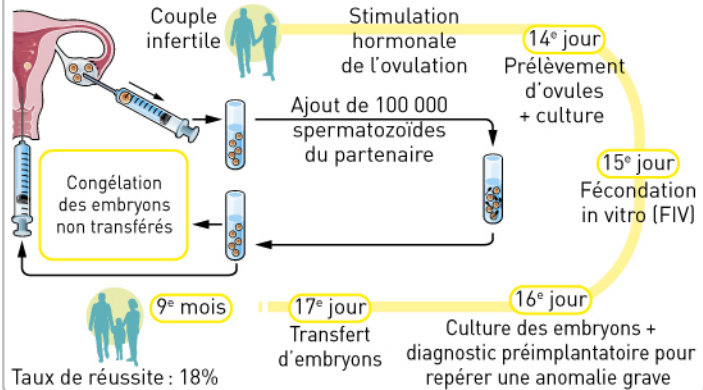
### La fécondation in vitro avec ICSI (injection intra-cytoplasmique de spermatozoïde)




### La stimulation ovarienne (permet de rétablir l'ovulation)

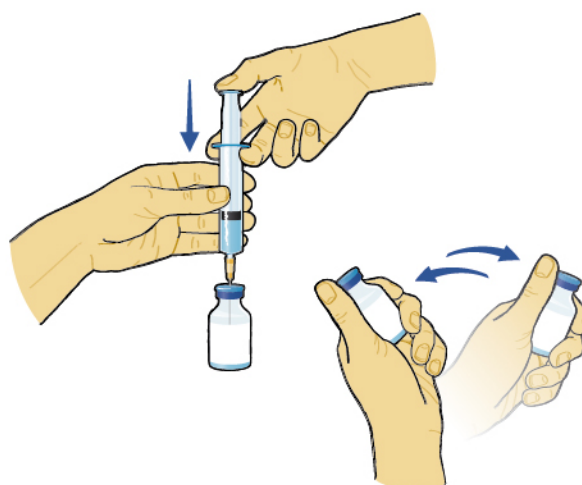
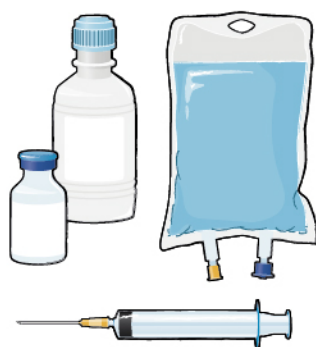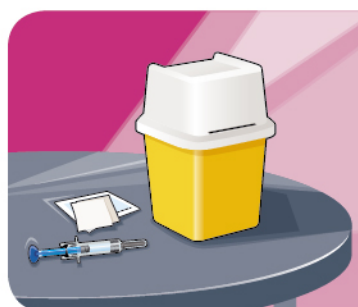
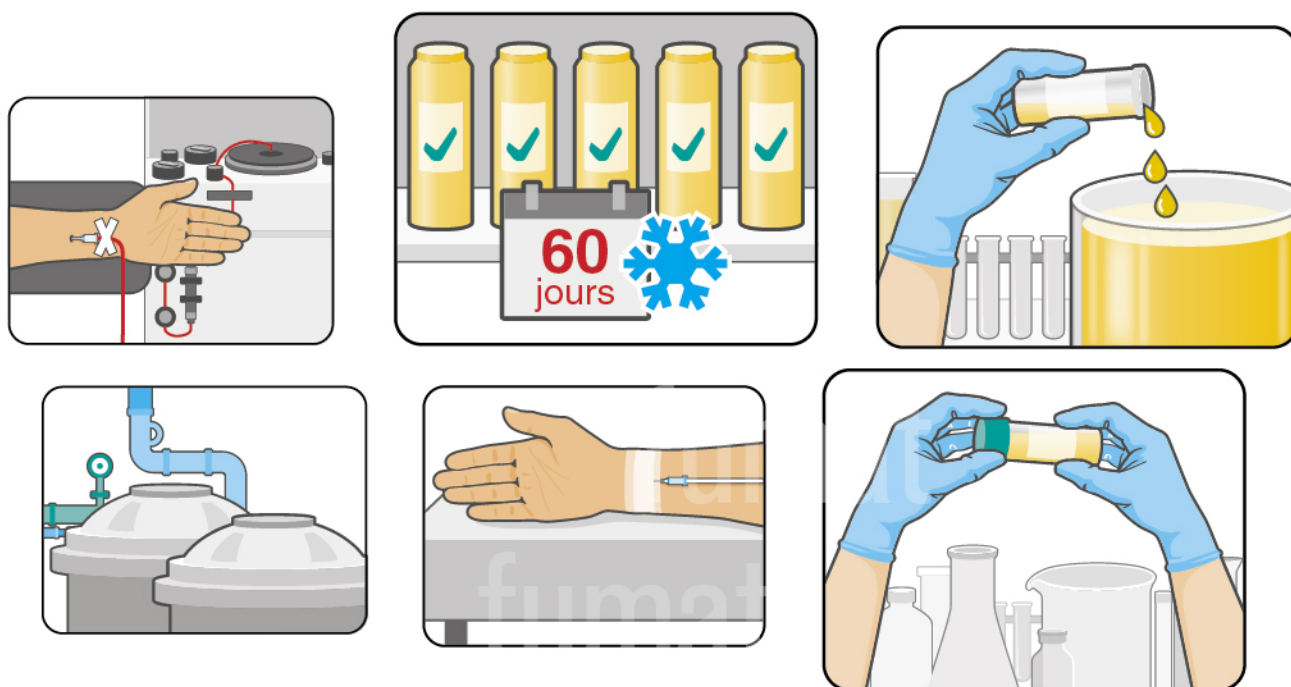
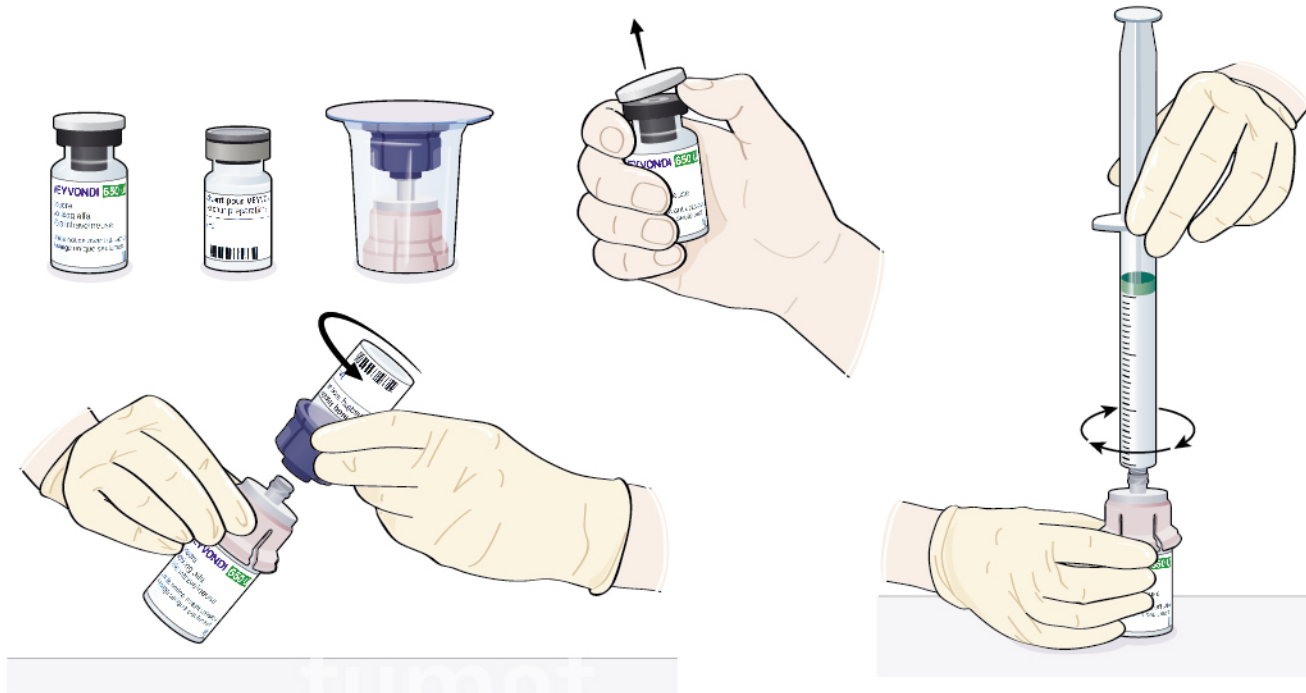


### La FIVETE (fécondation in vitro et transfert d'embryon(s))

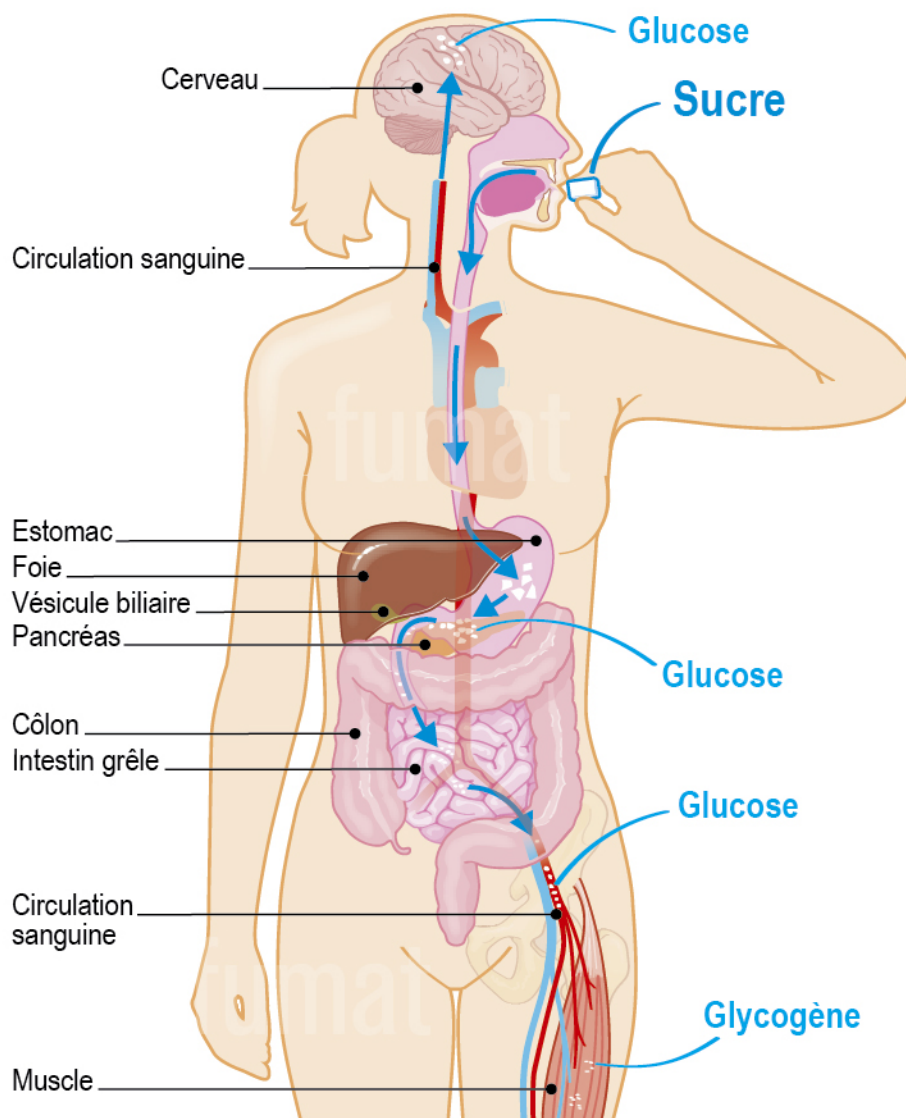




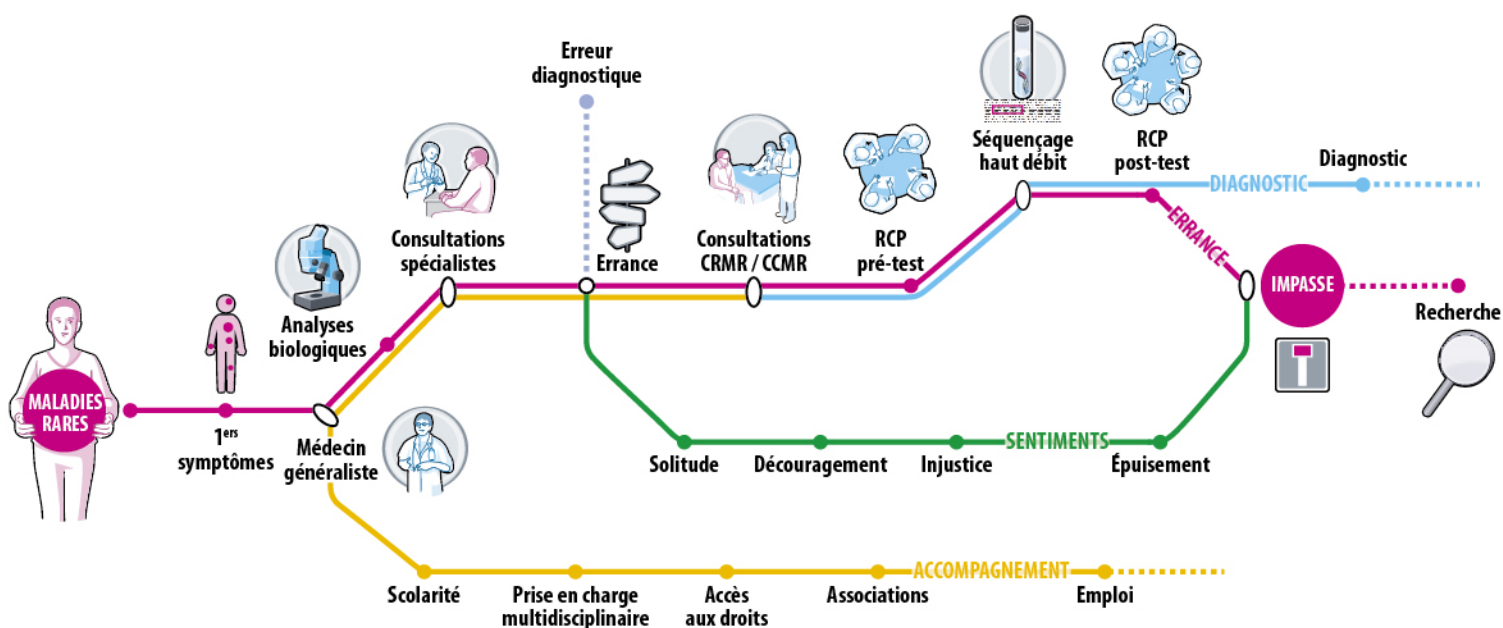








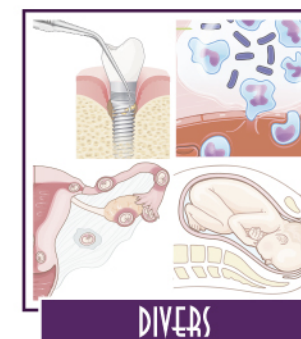
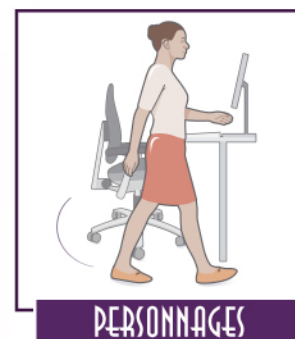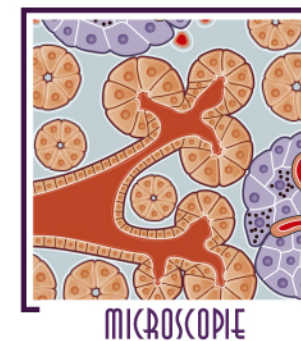
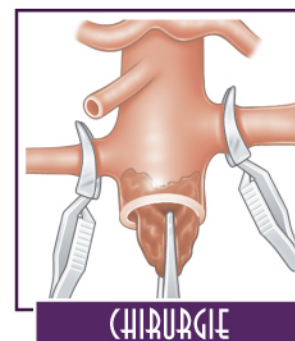
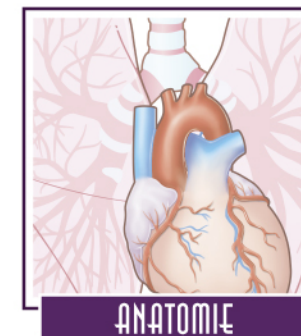

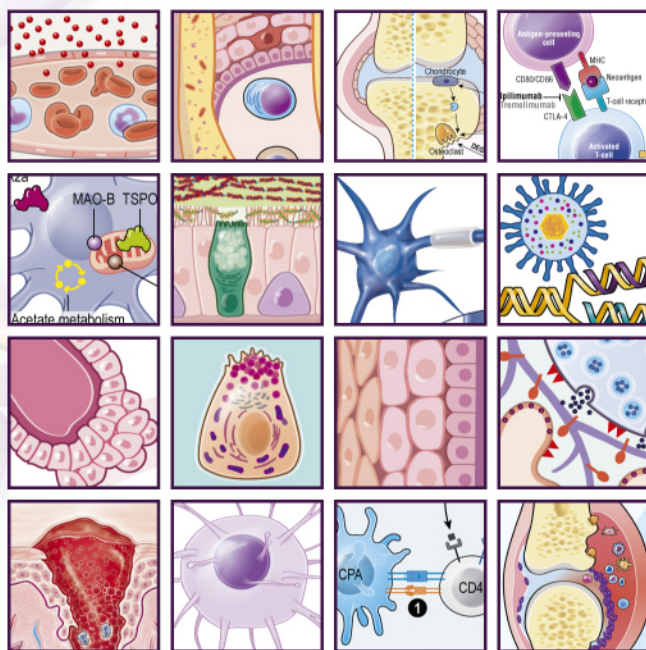
Larousse



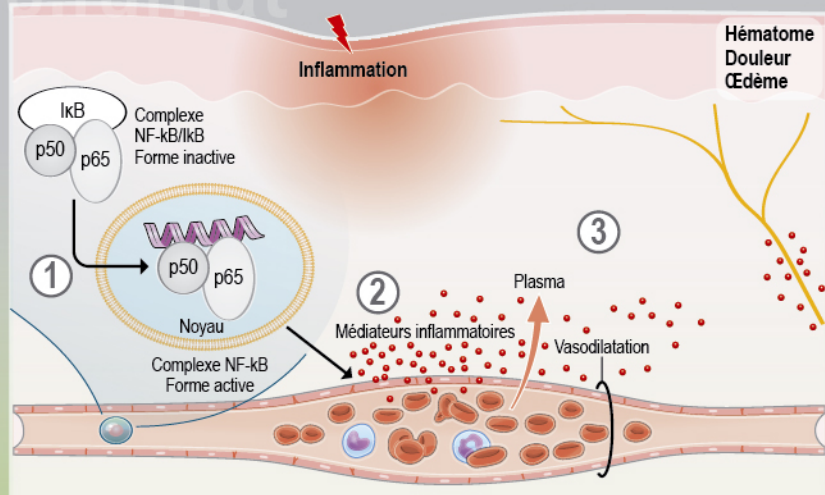




# MICROSCOPIE



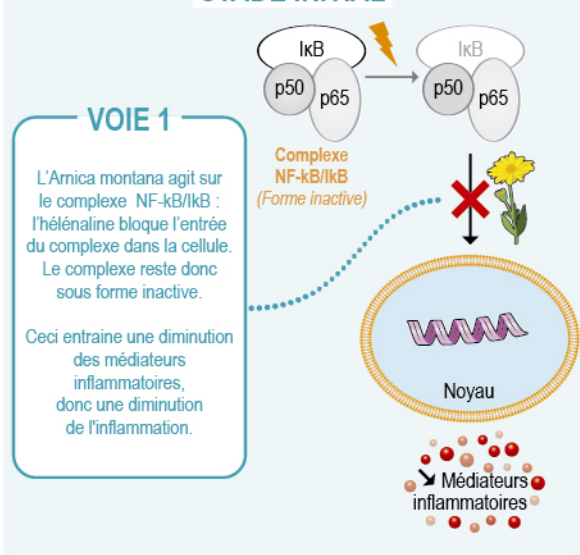
## Le processus inflammatoire



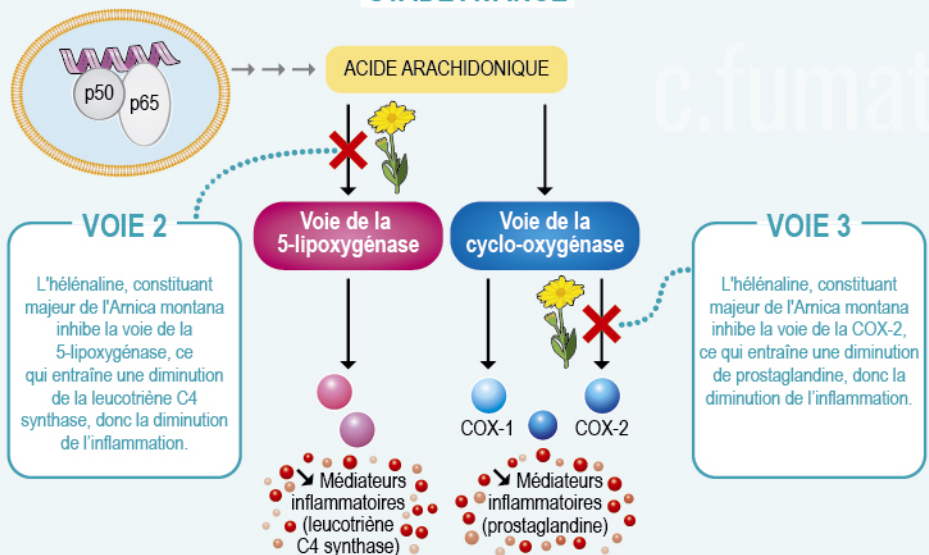
- 1 En cas d'inflammation, l'unité inhibitrice IkB est dégradée, le complexe NF-kB entre dans le noyau et se fixe à l'ADN
- 2 Production de différents médiateurs inflammatoires (IL-1,2,6,8 et TNF $\alpha$ )
- 3 Les symptômes de l'inflammation :
  - Vasodilatation = ŒDÈME
  - Atteinte des terminaisons nerveuses = DOULEUR
  - En cas d'atteintes des vaisseaux sanguins = HÉMATOME

## Rôle de l'*Arnica montana* dans le mécanisme d'action inflammatoire

### STADE INITIAL

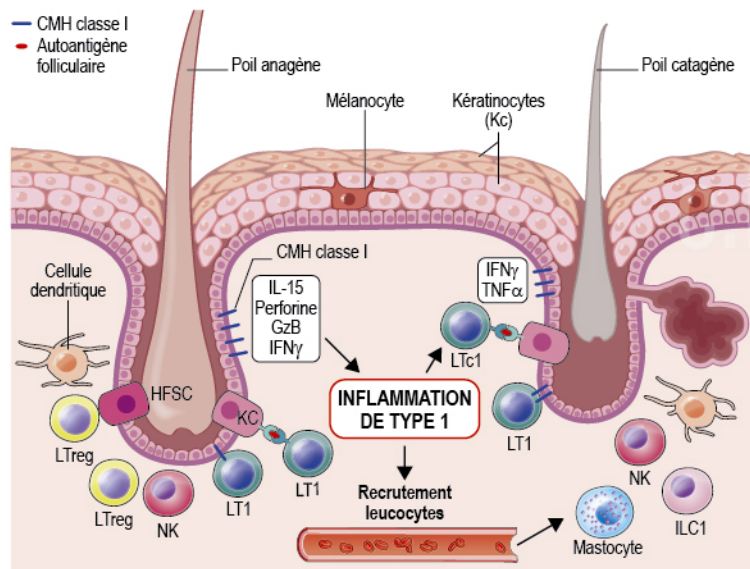


### STADE AVANCÉ

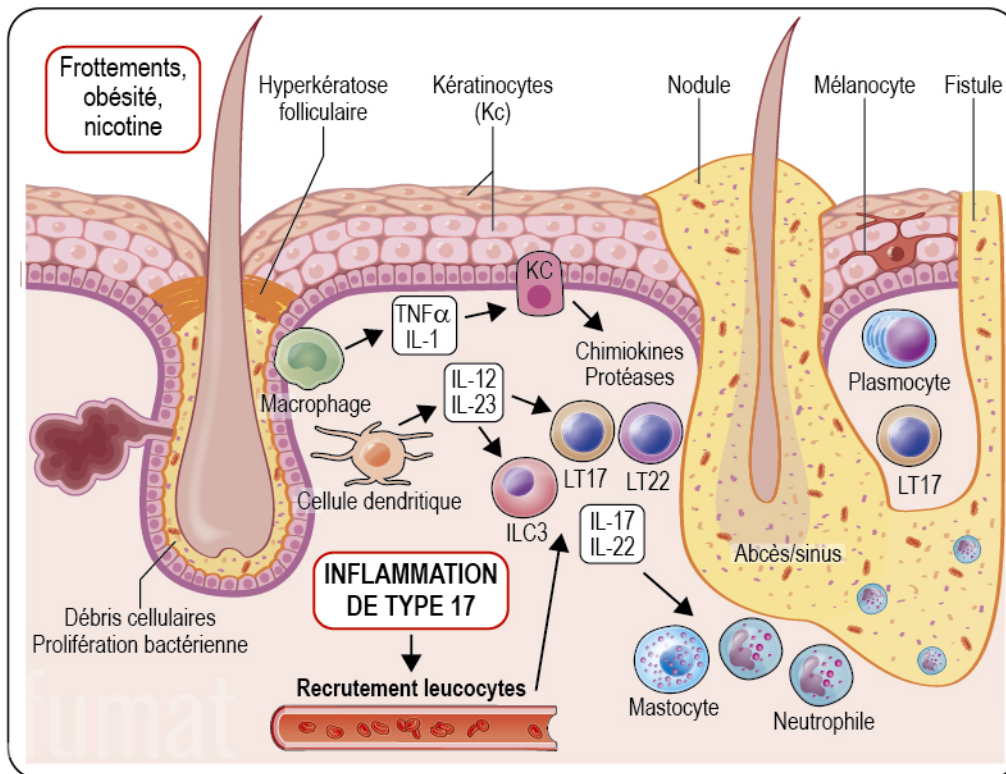


Diminution des symptômes de l'inflammation (douleur, œdème) et de l'hématome

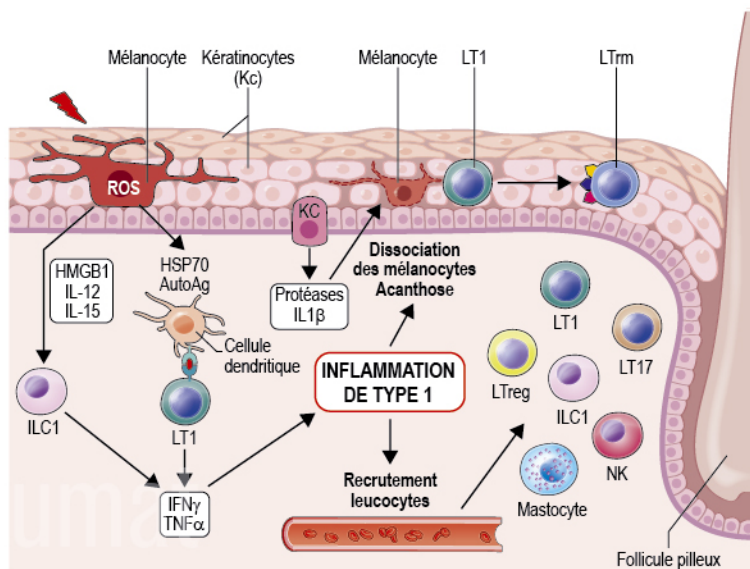




**Pelade**



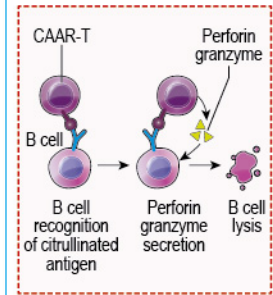
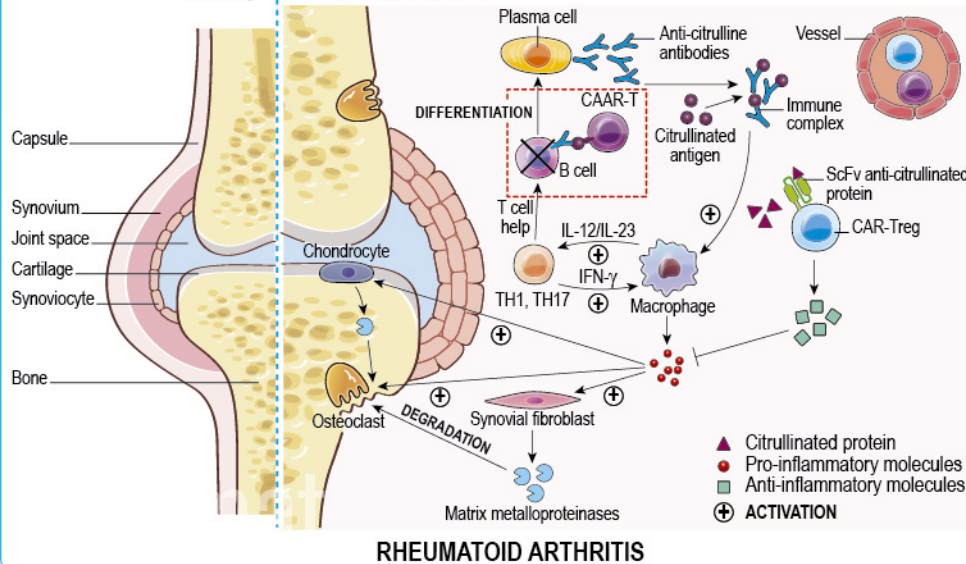
**Verneuil**



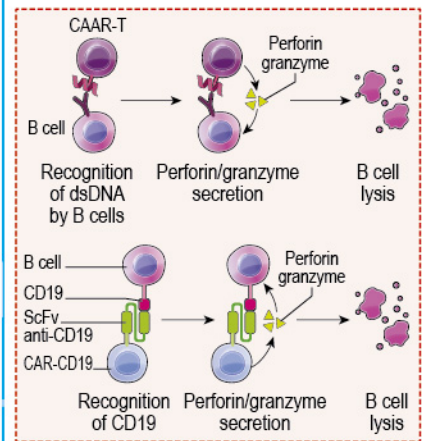
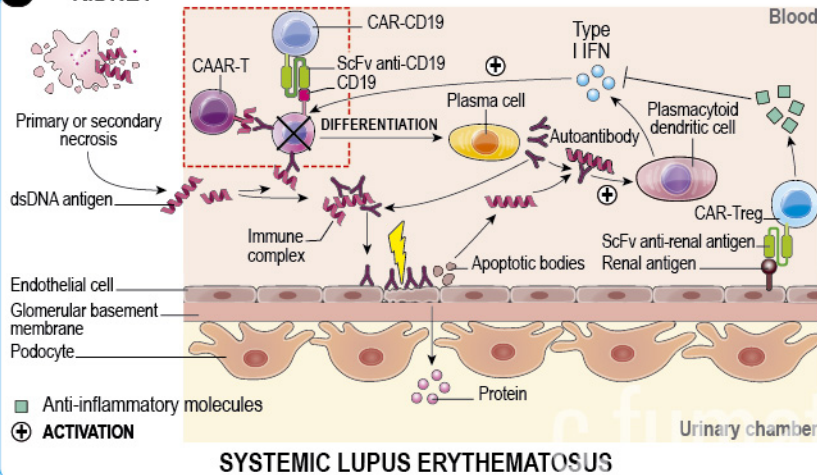
**Vitiligo**

## A — JOINT

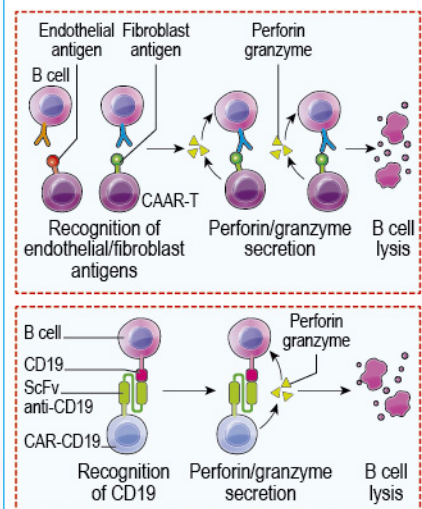
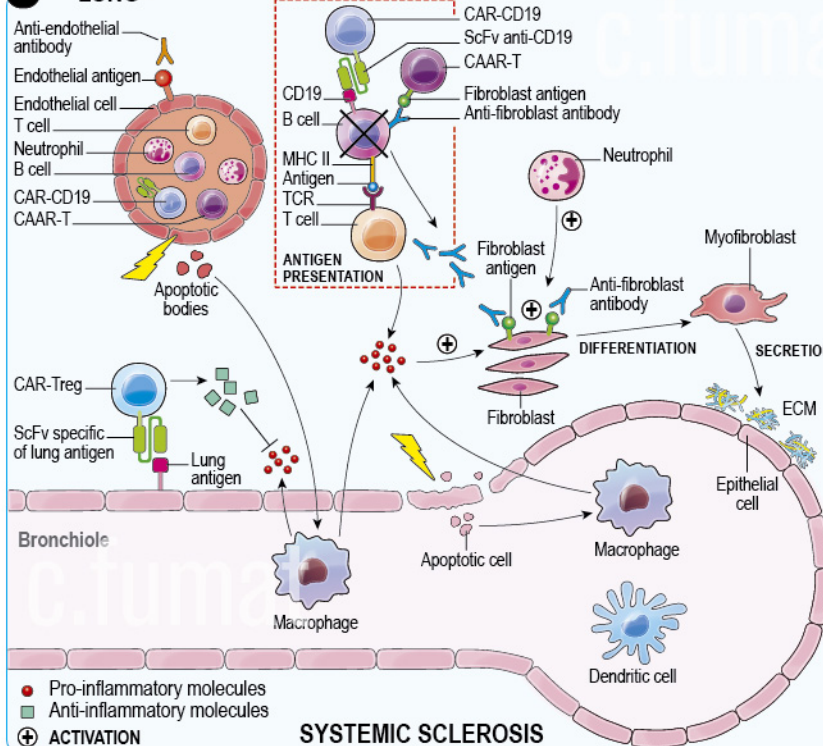
### Healthy Rheumatoid arthritis



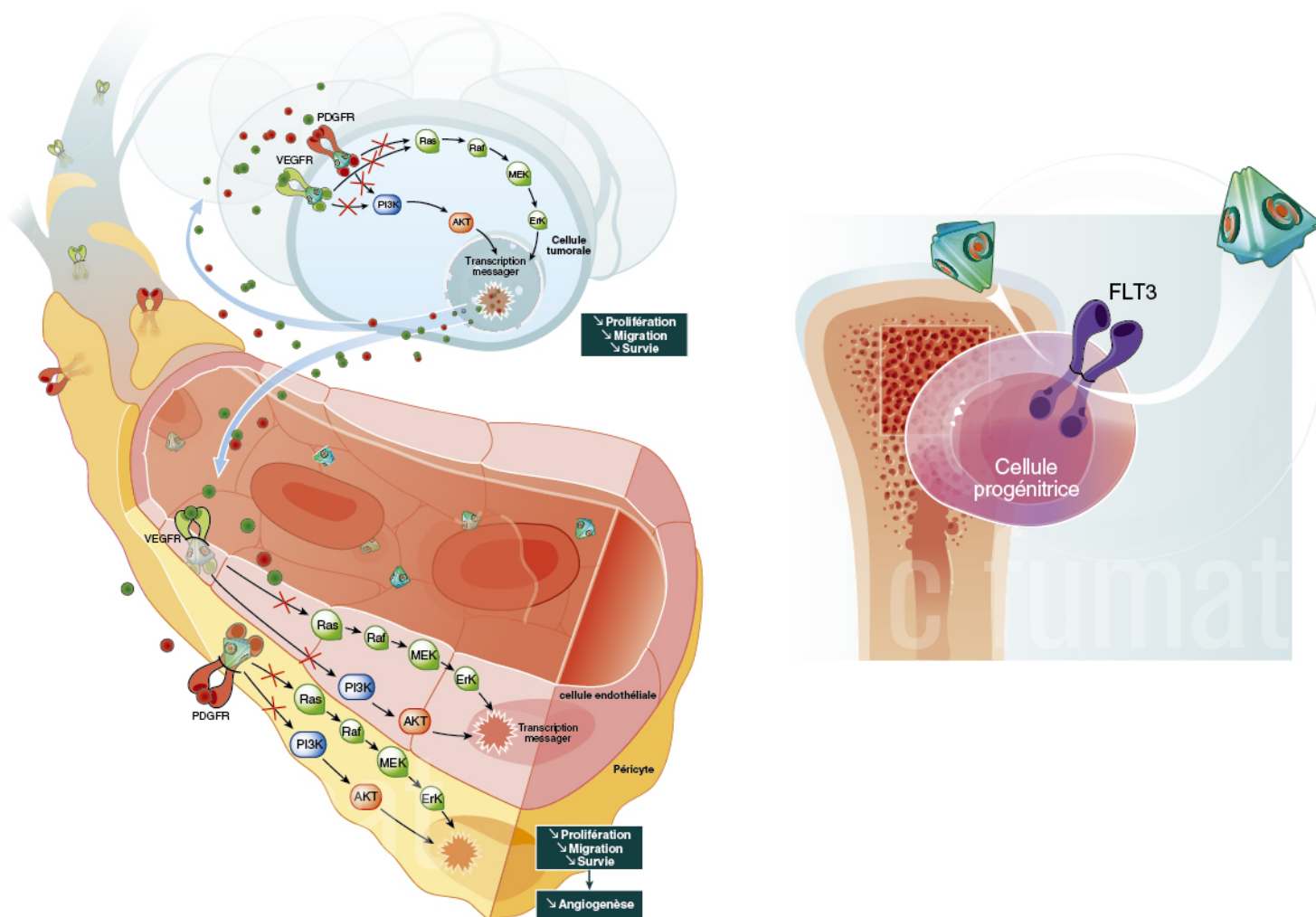
## B — KIDNEY



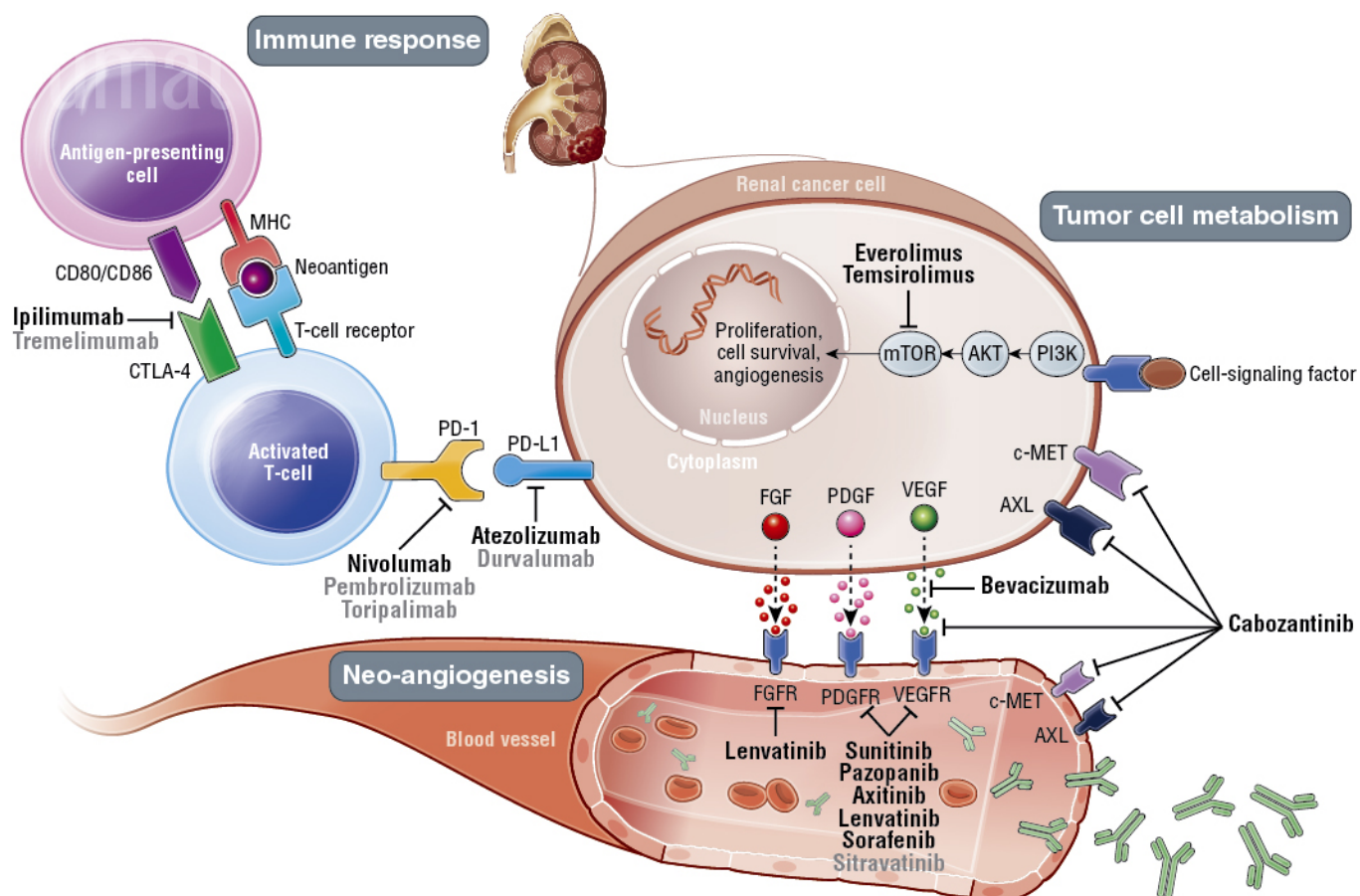
## C — LUNG



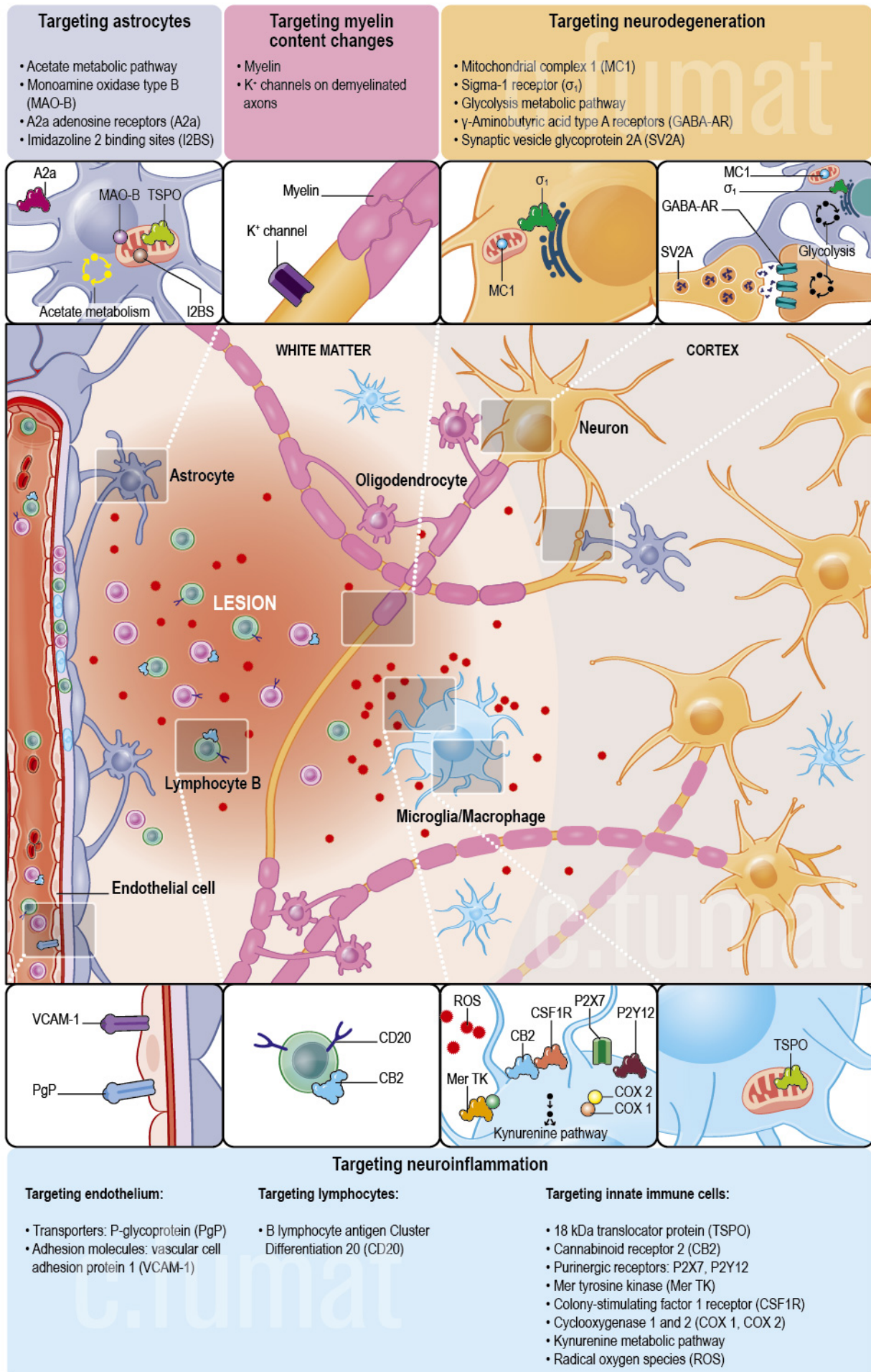




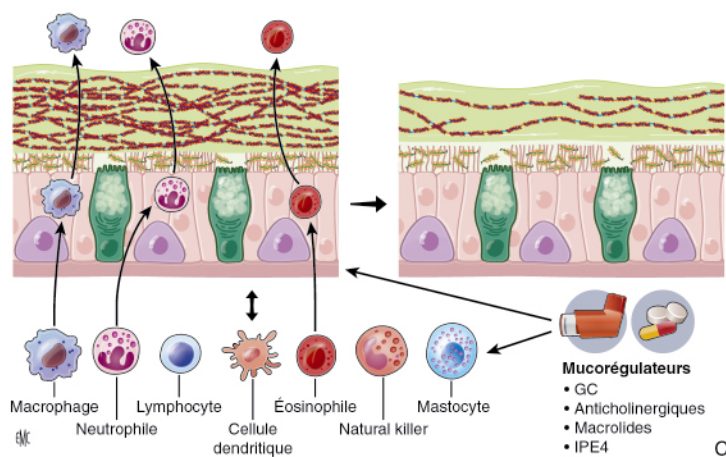
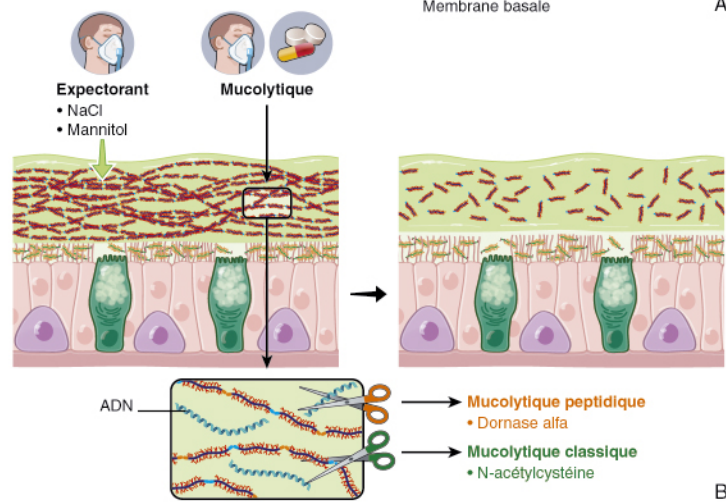
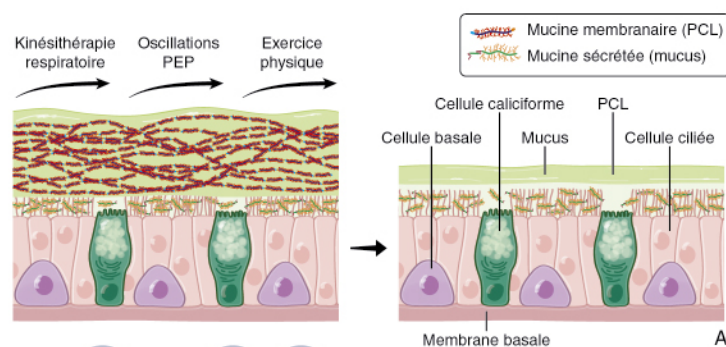
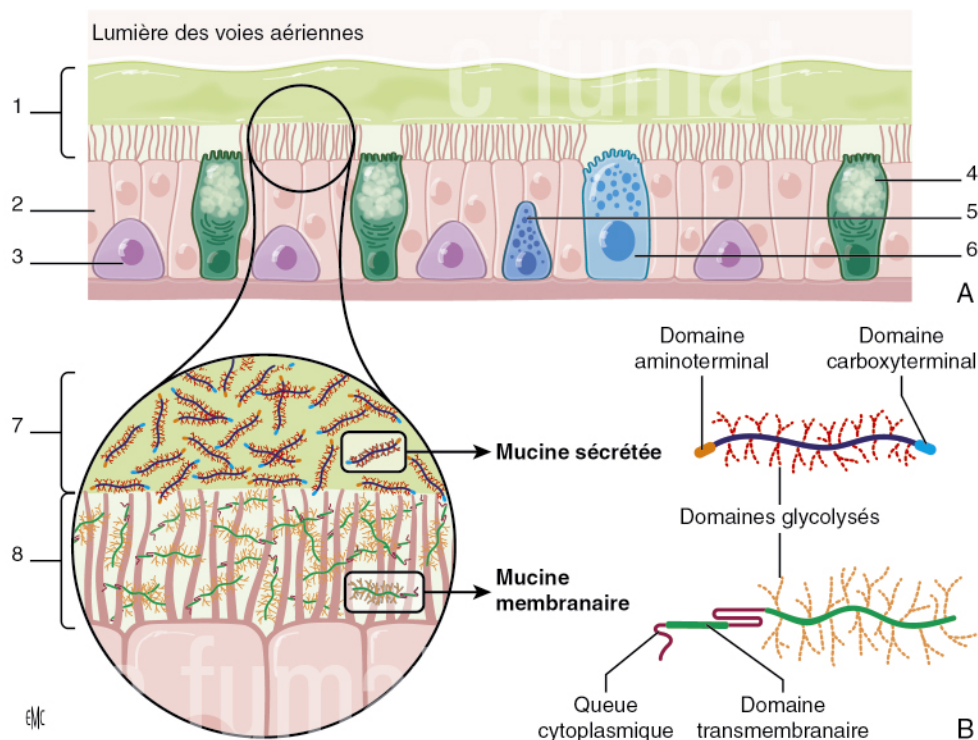
Agence communication santé

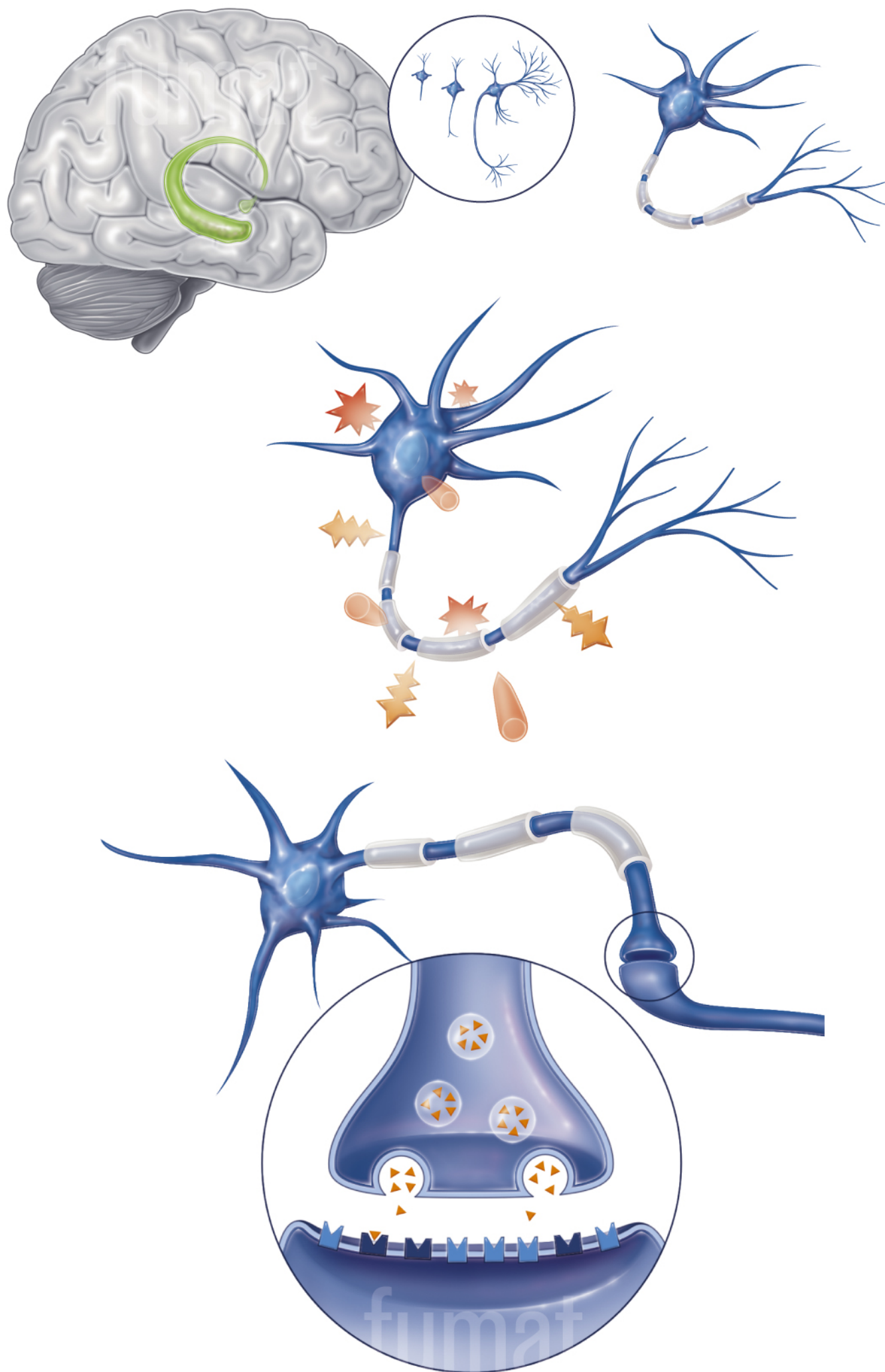


GH A.Chenevriér - H. Mondor











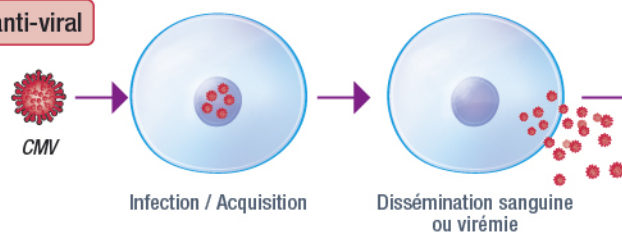
→ Mise en place d'un traitement :  
**AGENT ANTI-VIRAL**

2 stratégies :

- Préventive / Prophylaxie
- Curative anticipée / Pré-emptive

Le + tôt possible après la greffe

**SANS agent anti-viral**



**CIBLE**

- organes cibles,
- cellules endothéliales des vaisseaux,
- cellules épithéliales,
- cellules fibroblastiques,
- cellules du système immunitaire,
- moelle osseuse,
- cellules du système nerveux central.

**AVEC agent anti-viral**



**1**

**FUSION OU  
ENDOCYTOSE  
DU CMV**

**2**

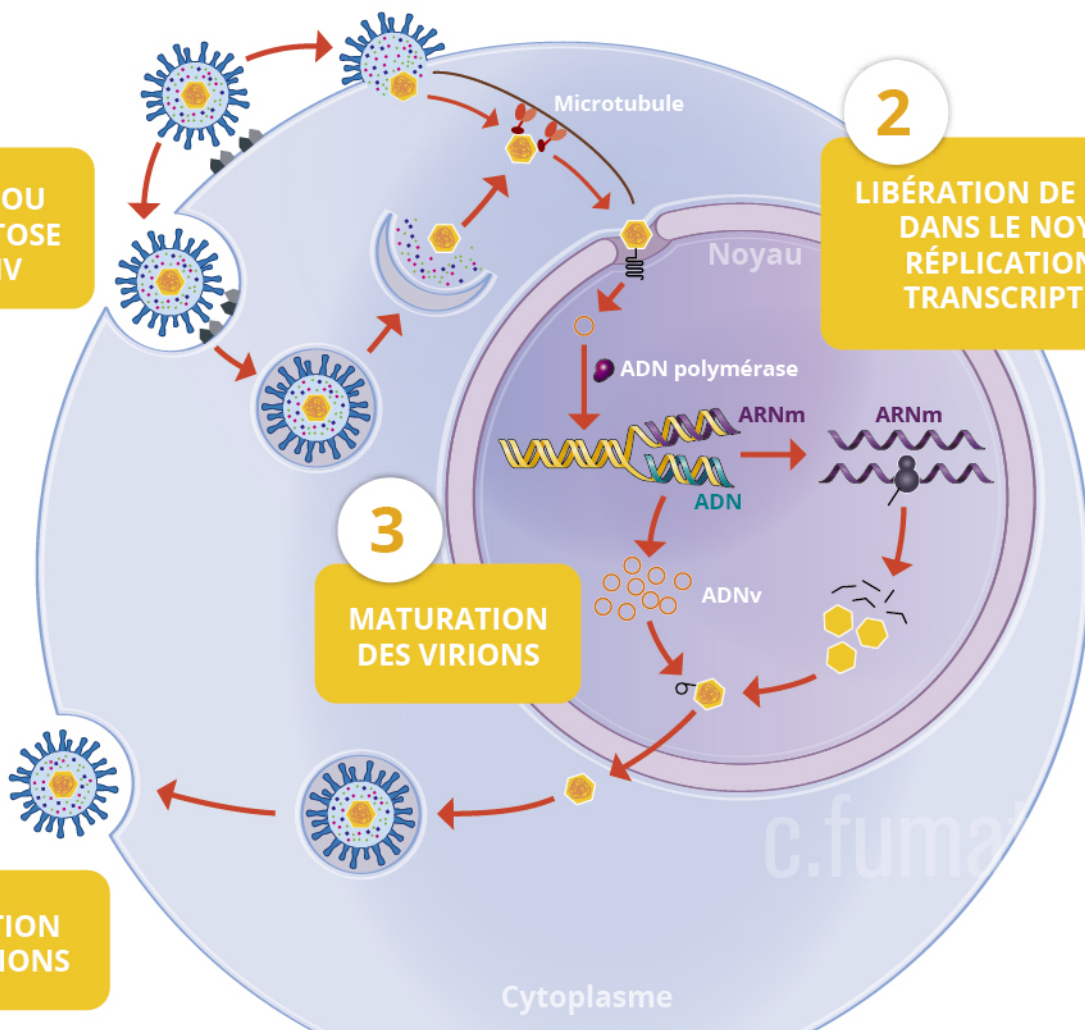
**LIBÉRATION DE L'ADNv  
DANS LE NOYAU,  
RÉPLICATION ET  
TRANSCRIPTION**

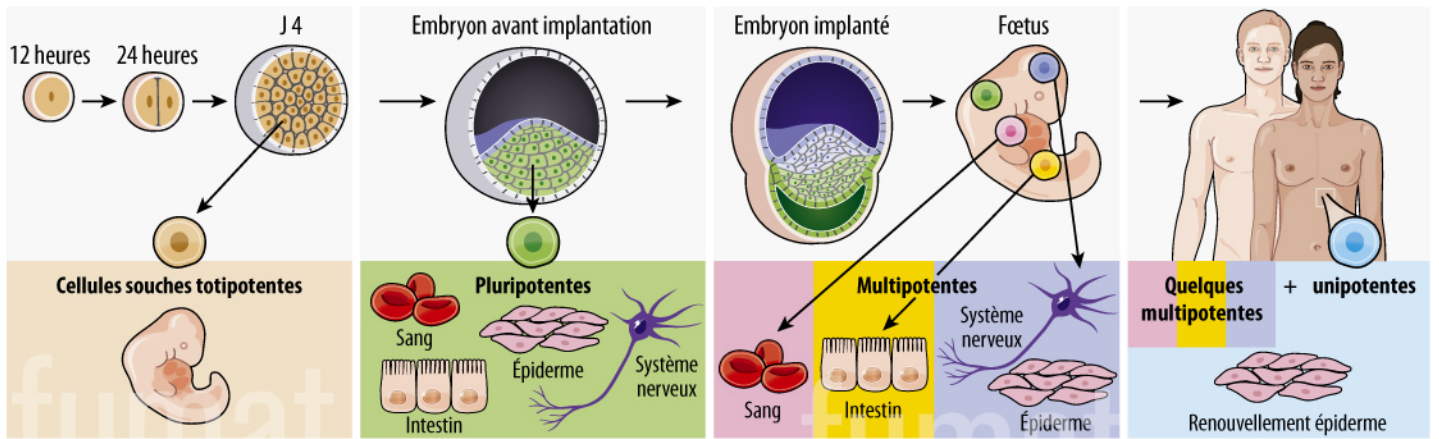
**3**

**MATURATION  
DES VIRIONS**

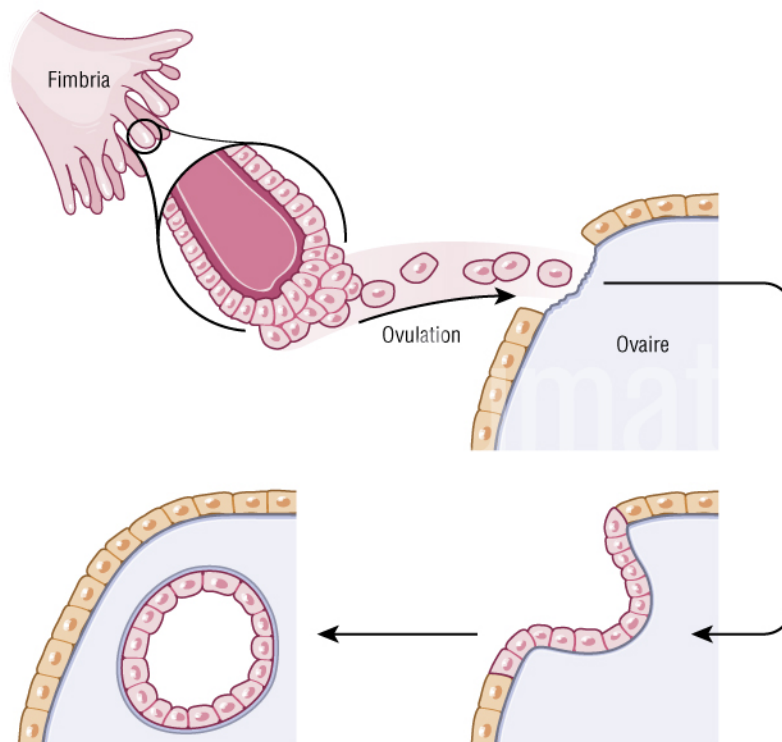
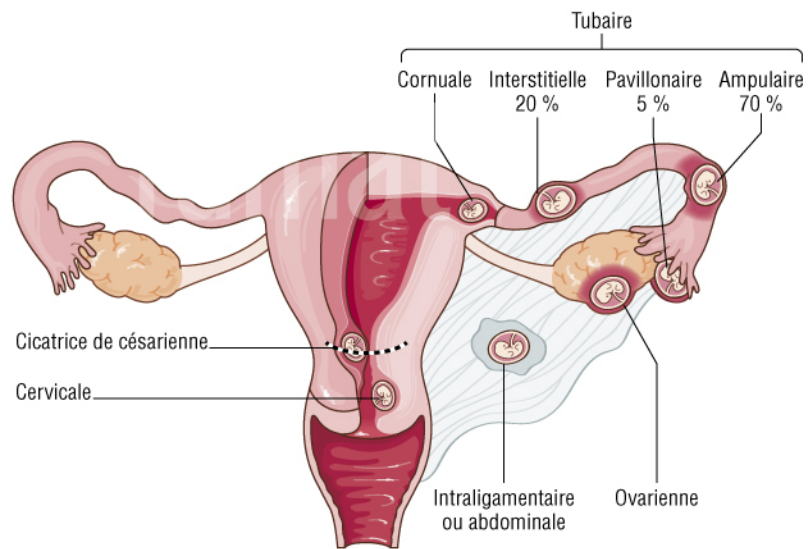
**4**

**EXCRÉTION  
DES VIRIONS**



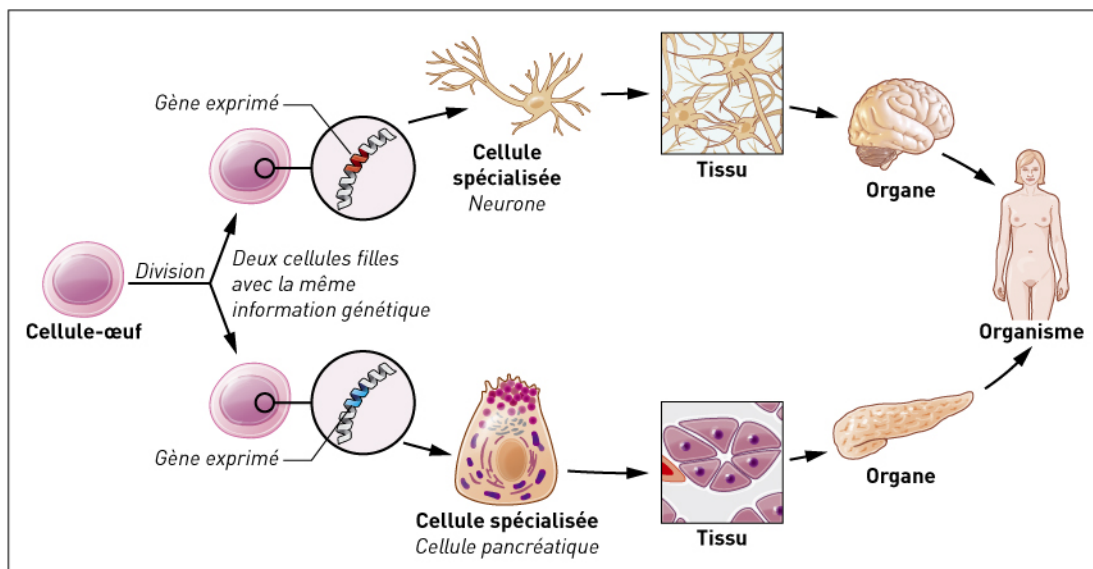
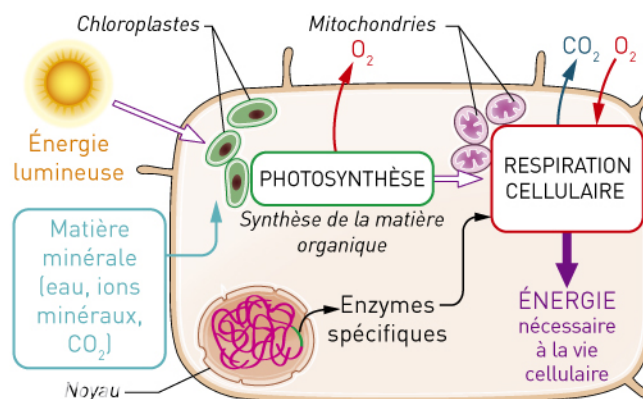
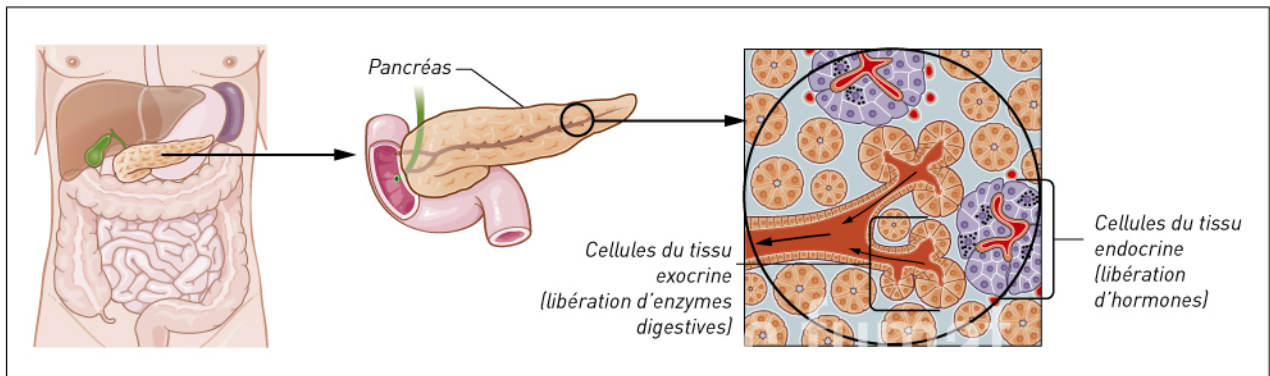
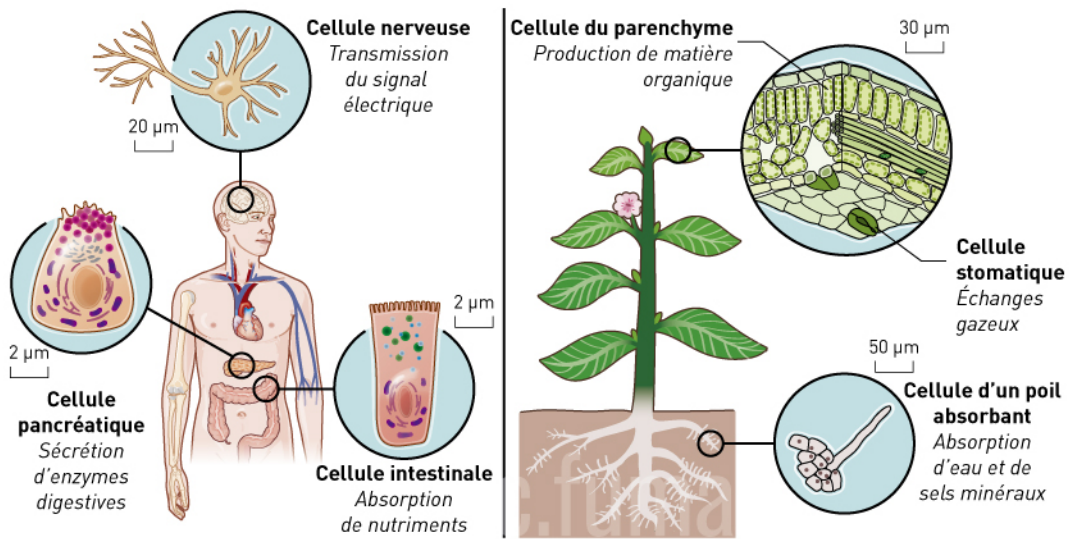


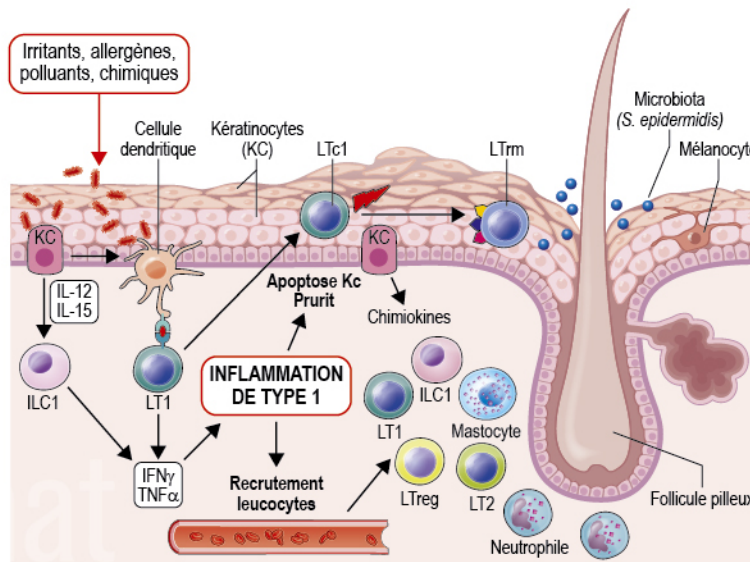
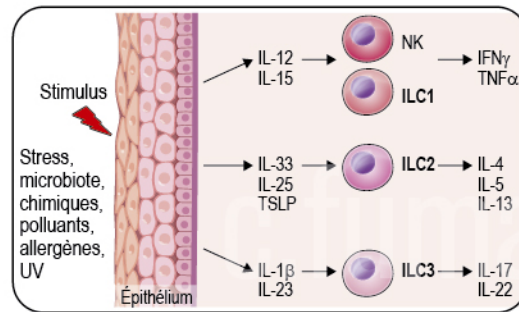
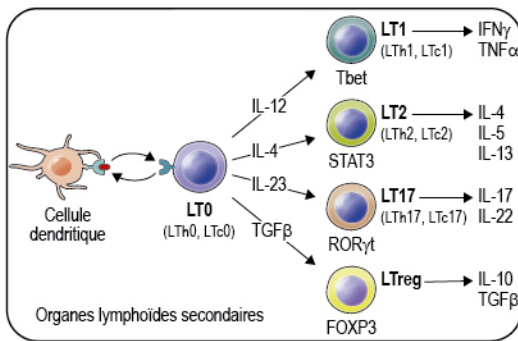
Éditions Didier



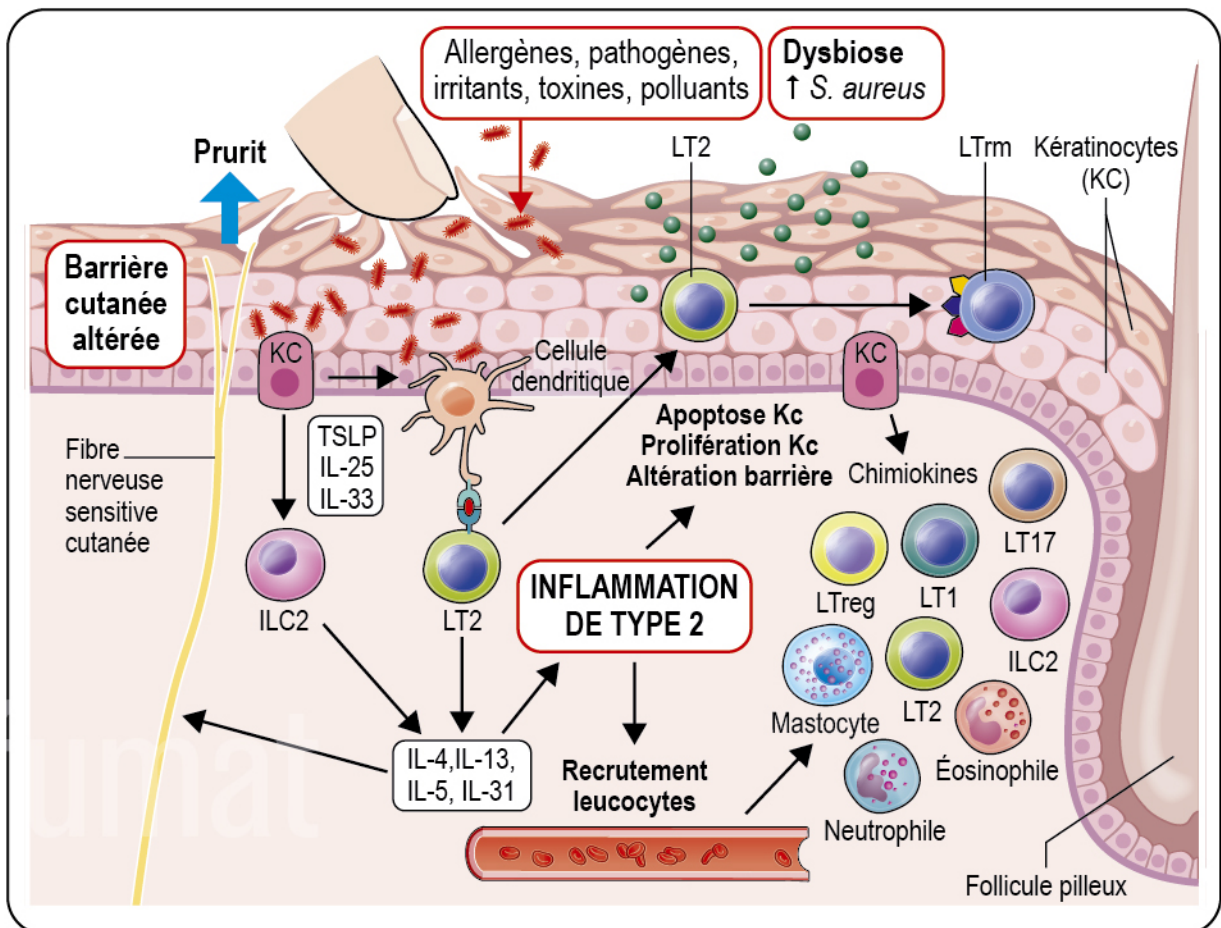
Elsevier Masson





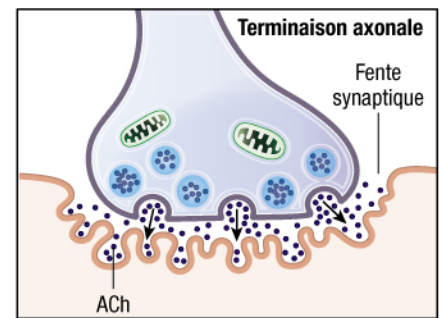
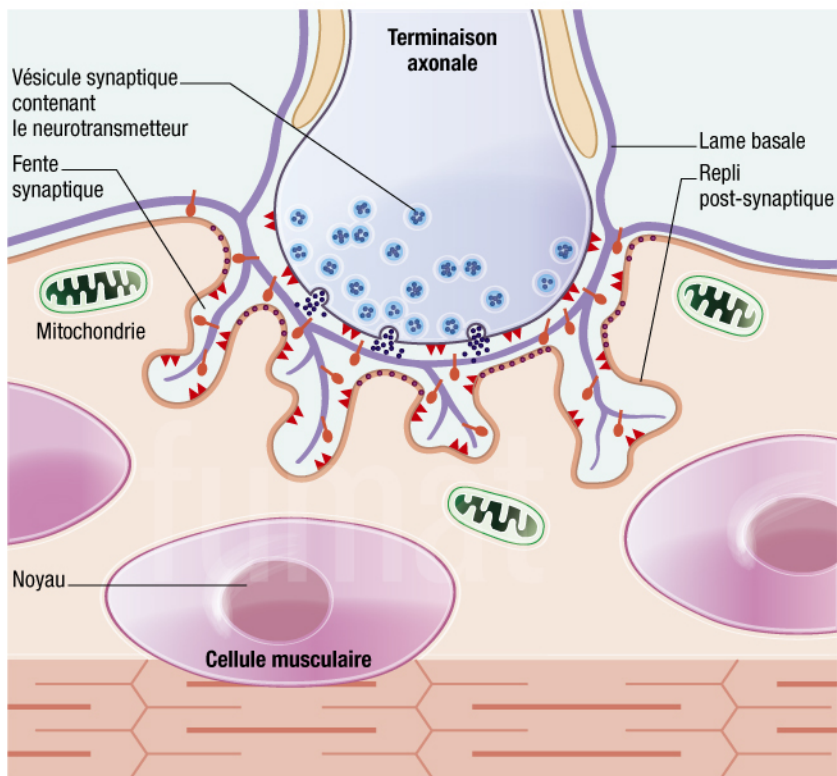


Eczéma de contact

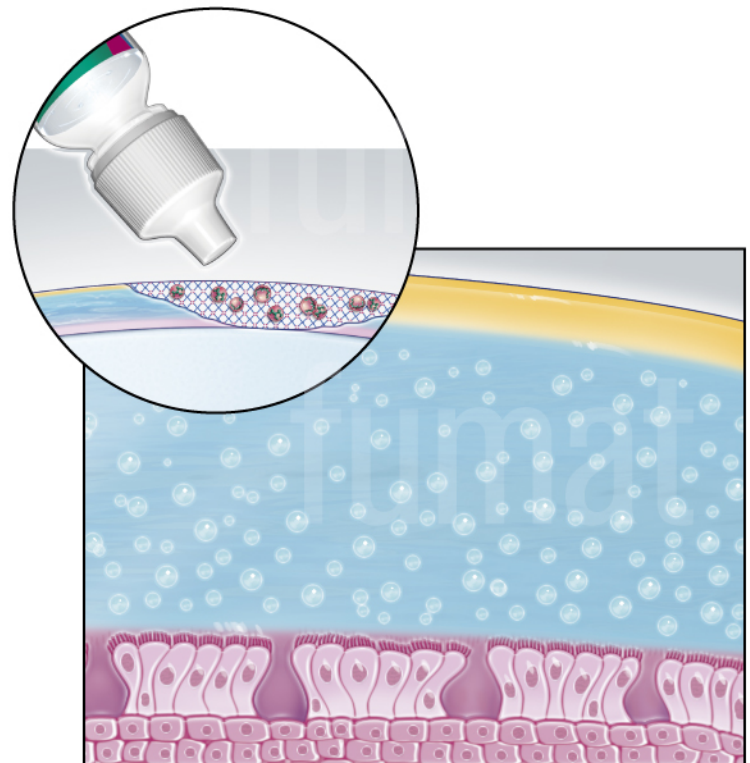
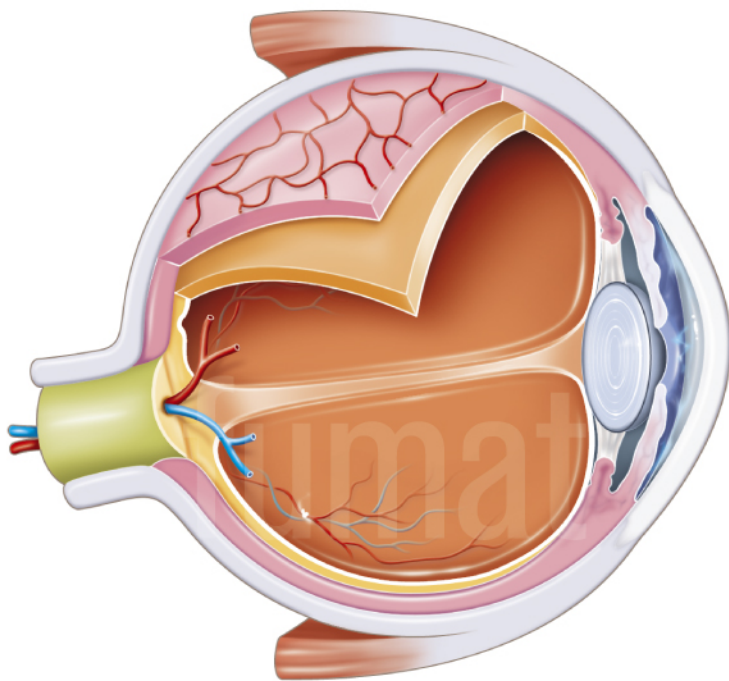


Dermatite atopique

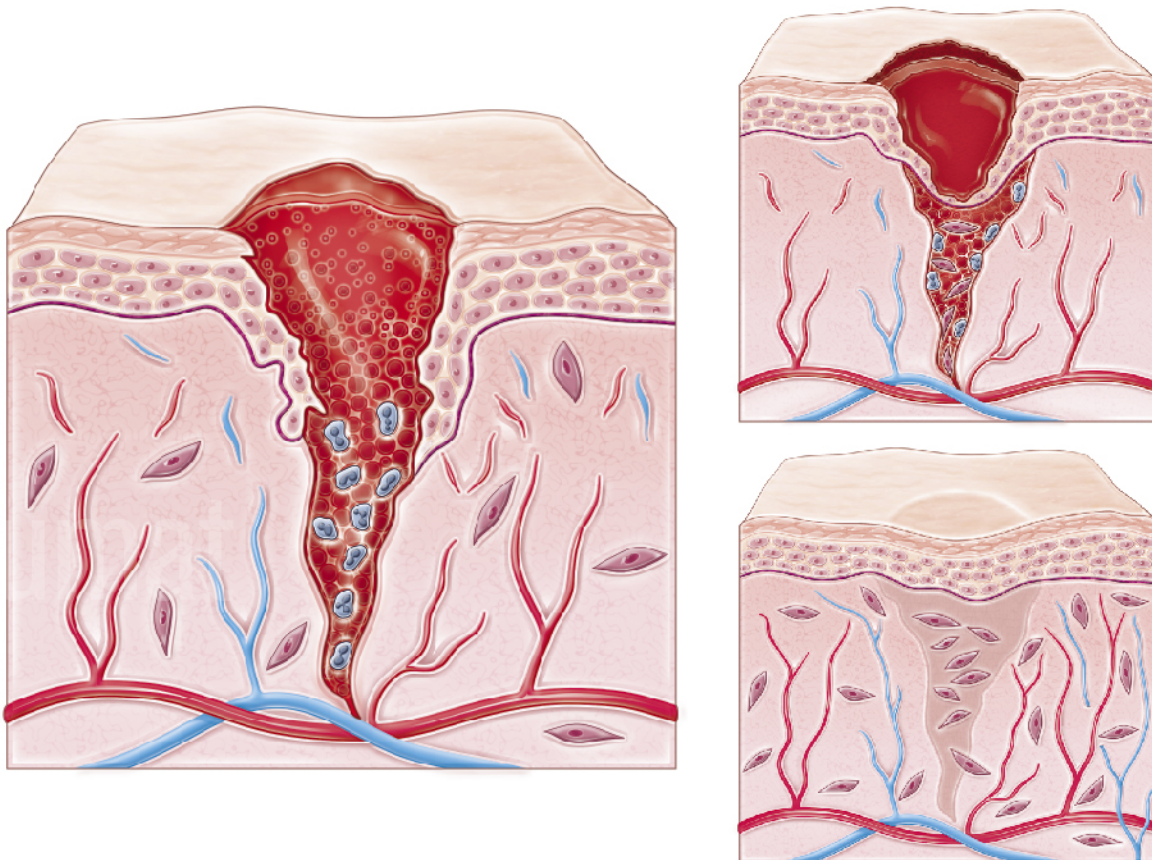




Elsevier Masson

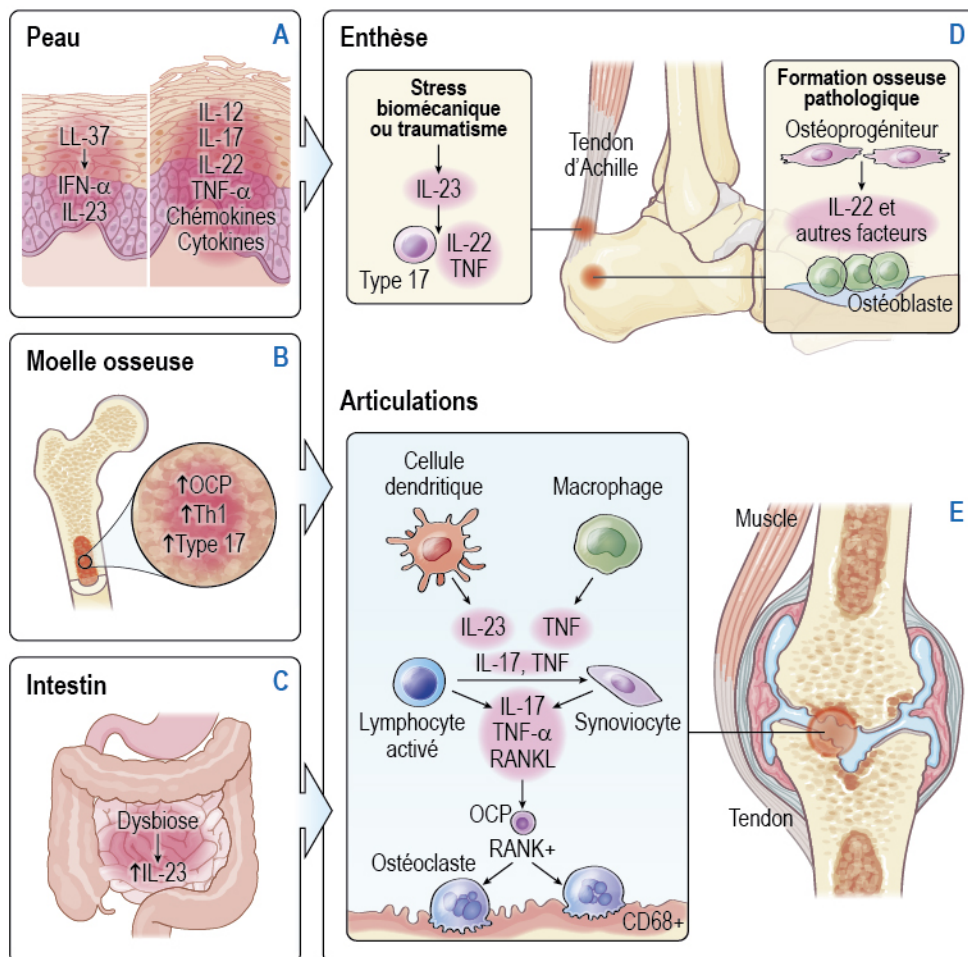


Agences communication santé



Agence communication santé

### Voie de signalisation physiopathogénique dans le RPso





## Les principaux organes et tissus lymphoïdes

**Amygdales et végétations**  
Activation des lymphocytes T et B

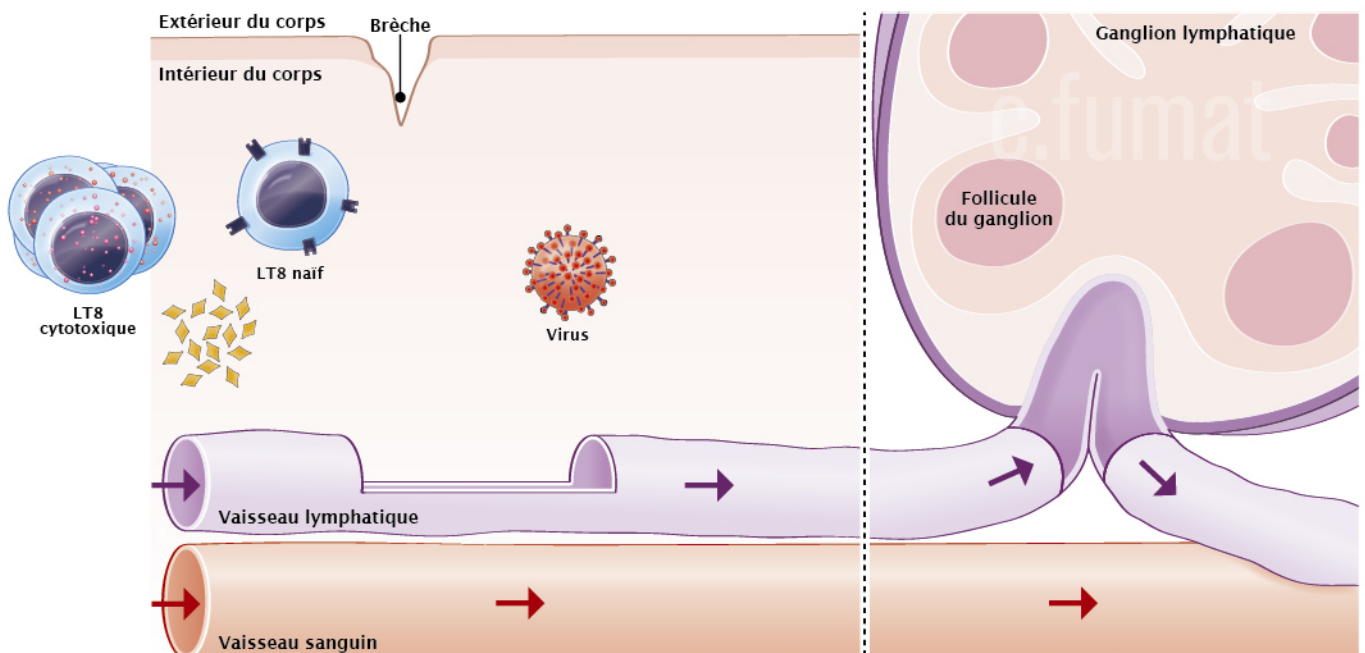
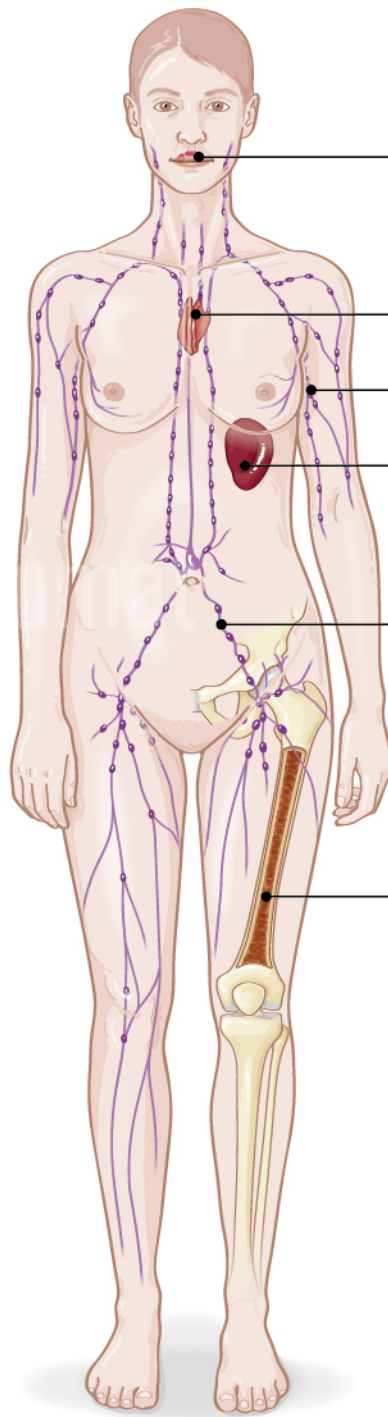
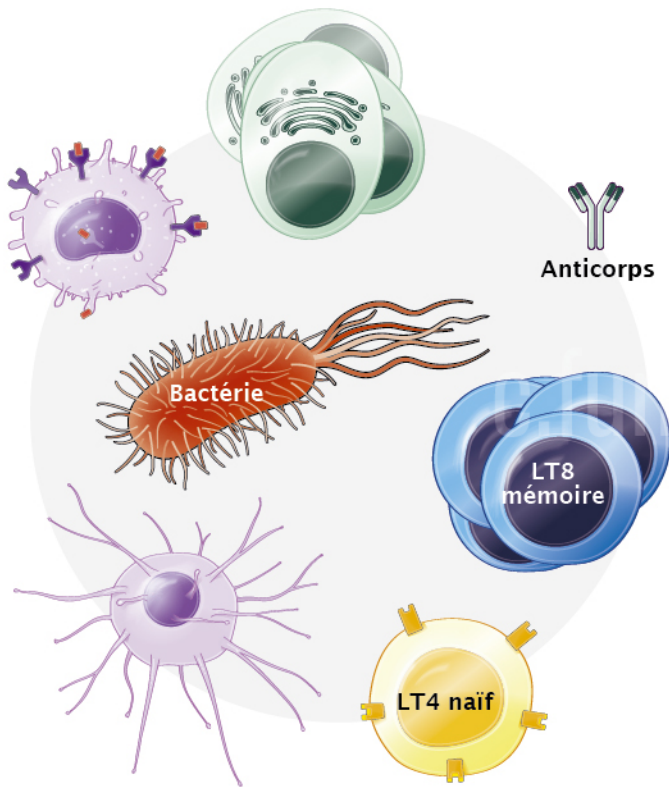
**Thymus**  
Maturation des lymphocytes T

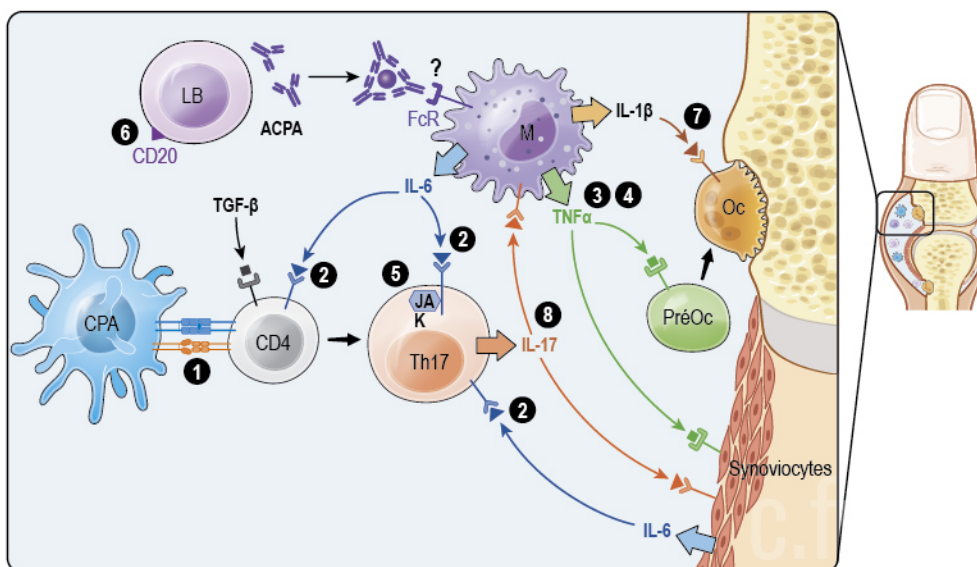
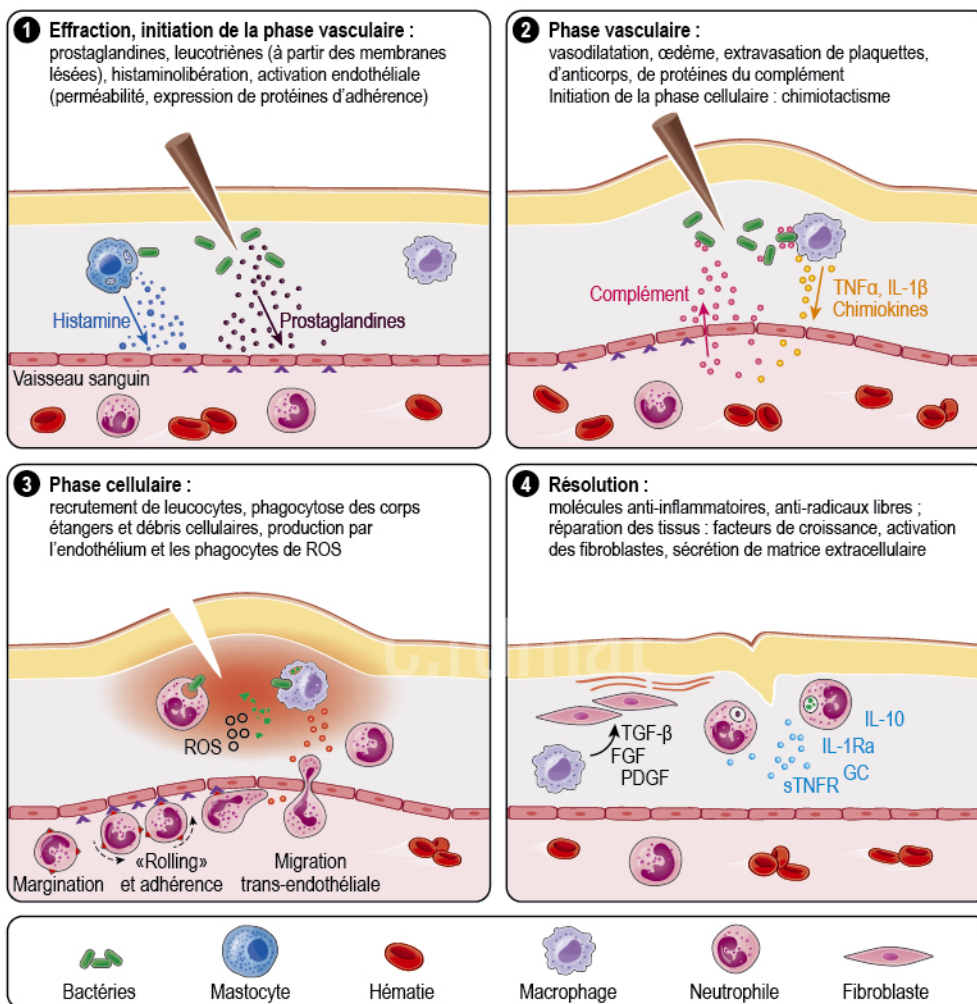
**Ganglions lymphatiques**  
Activation des lymphocytes T et B

**Rate**  
Activation des lymphocytes T et B

**Vaisseaux lymphatiques**  
Circulation des cellules du système immunitaire

**Moelle osseuse**  
Production des progéniteurs des cellules du système immunitaire  
Développement et maturation des lymphocytes B





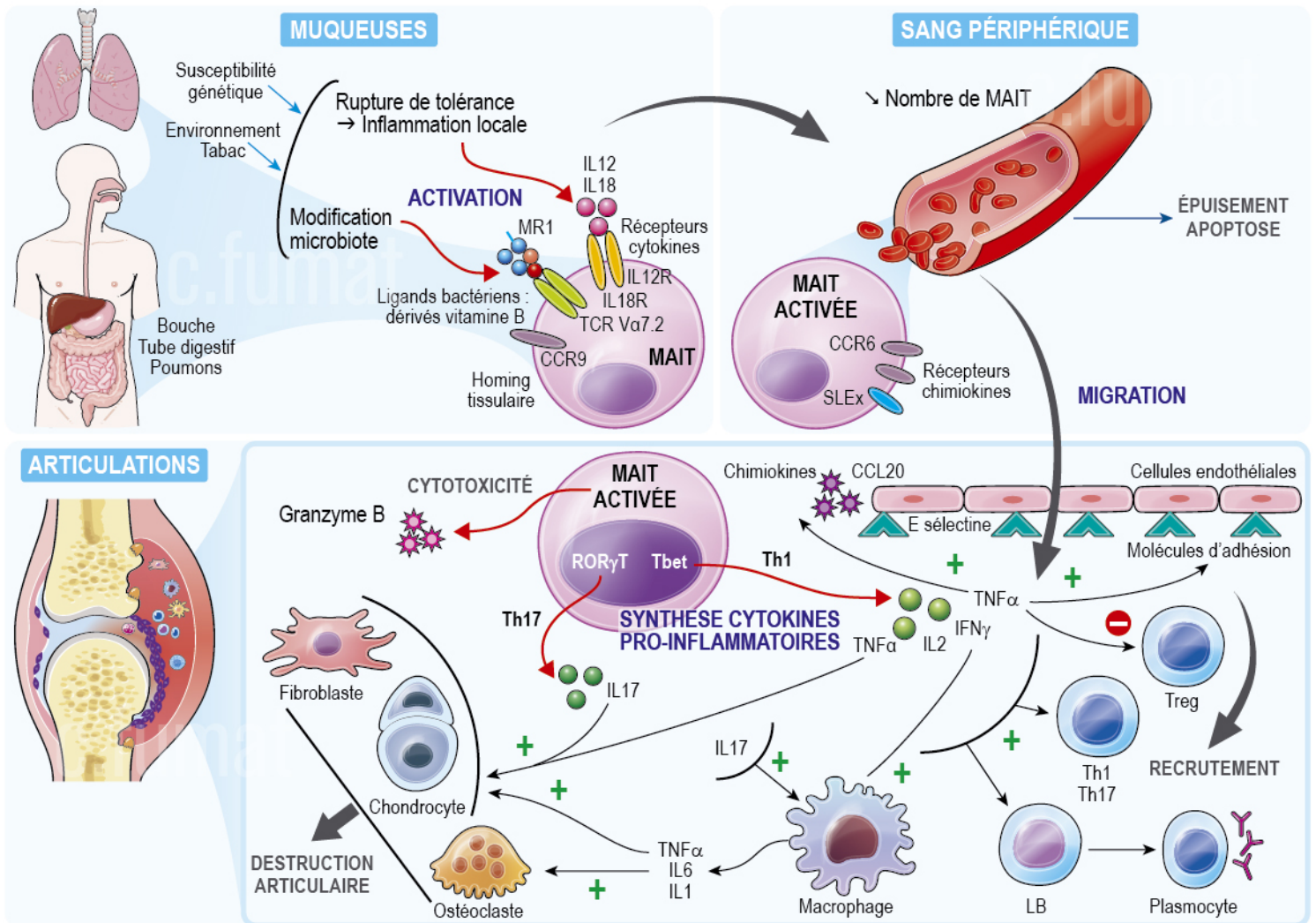
#### Biothérapies actuellement indiquées dans la PR

- |   |   |  |
|---|---|--|
| <b>1 Abatacept</b><br>Protéine de fusion (CTLA-4-Ig), inhibiteur de l'interaction entre CD80/86 et CD28 (2 $^{\circ}$ signal) | <b>3 Adalimumab</b><br><b>Certolizumab</b><br><b>Golimumab</b><br><b>Infliximab</b><br>Ac anti-TNF $\alpha$ | <b>5 Baricitinib</b><br><b>Tofacitinib</b><br><b>Upadacitinib</b><br><b>Filgotinib</b><br>Inhibiteurs de JAK |
| <b>2 Tocilizumab</b><br><b>Sarilumab</b><br>Ac anti-IL-6R   | <b>4 Étanercept</b><br>Protéine de fusion (TNFR2-Ig) anti-TNF $\alpha$                                      | <b>6 Rituximab</b><br>Ac anti-CD20   |

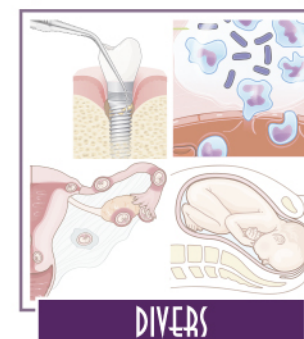


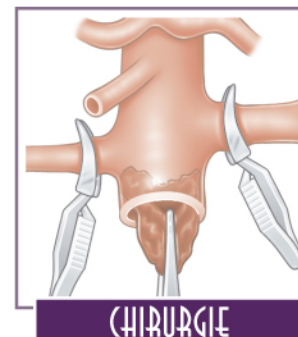
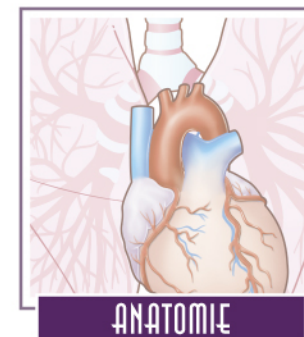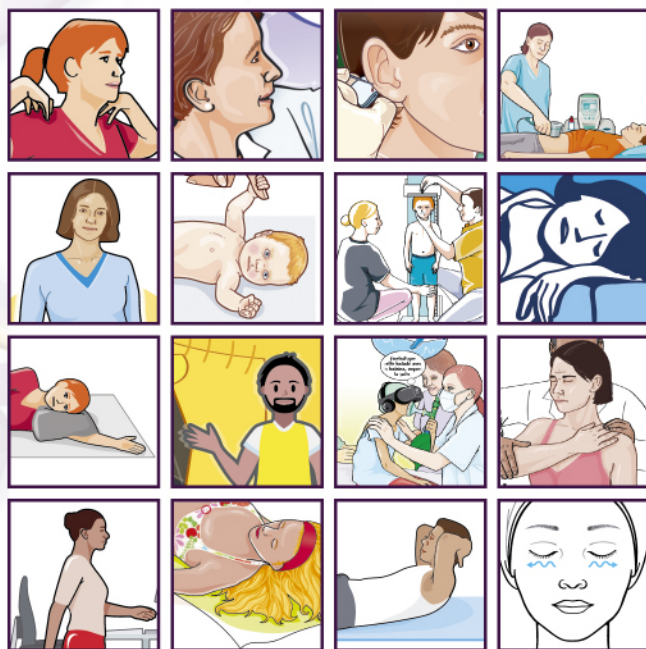
#### Biothérapies non utilisées dans la PR

- |  |  |
|--|--|
| <b>7 Anakinra</b> , inhibiteur compétitif de IL-1R (de dernière ligne) | <b>Dénosumab</b><br>Ac anti-RANKL (en développement) |
| <b>8 Séculinumab</b><br>Ac anti-IL-17A (peu efficace)                  |  |






# PERSONNAGES

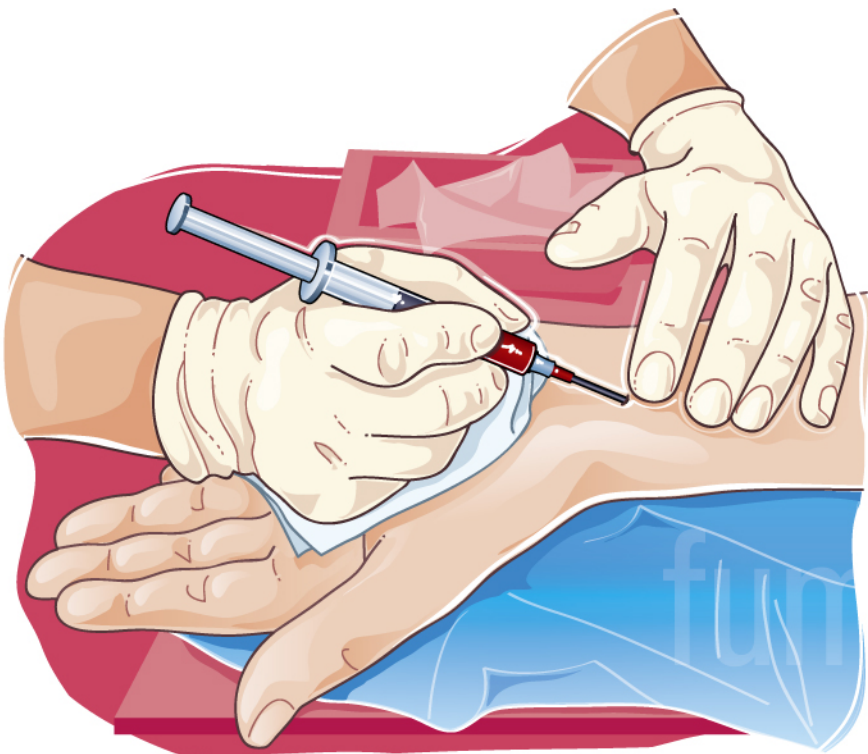
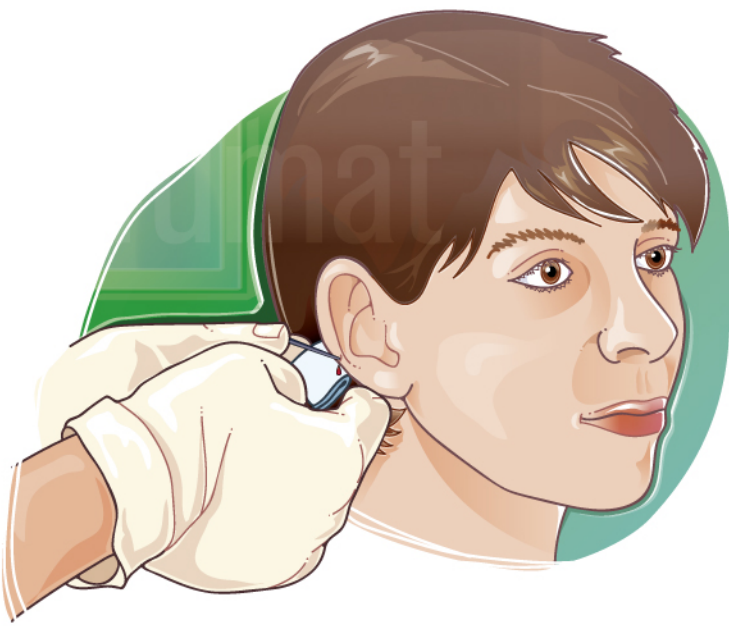


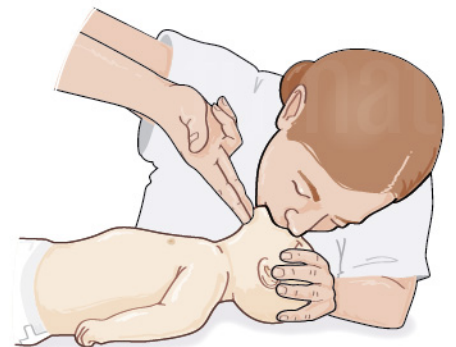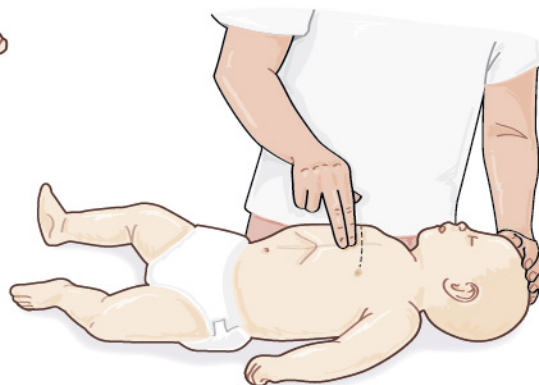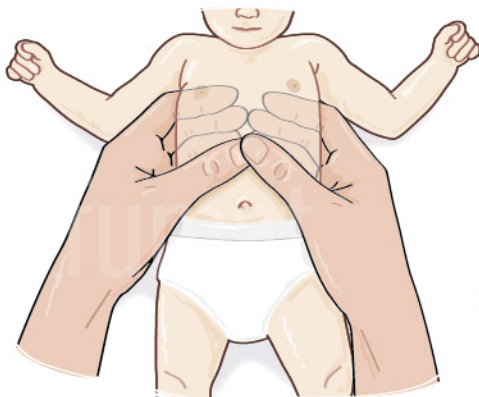


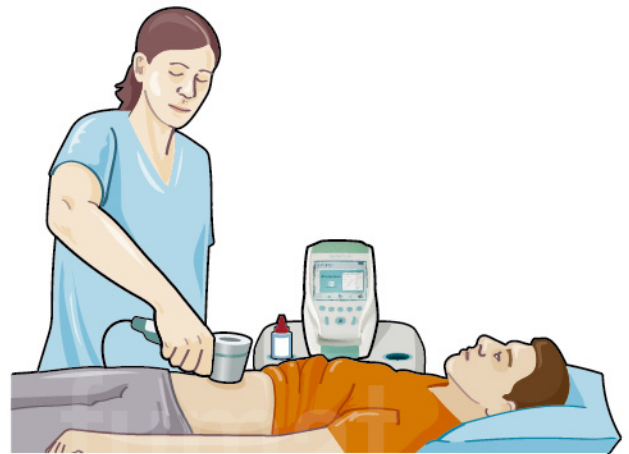
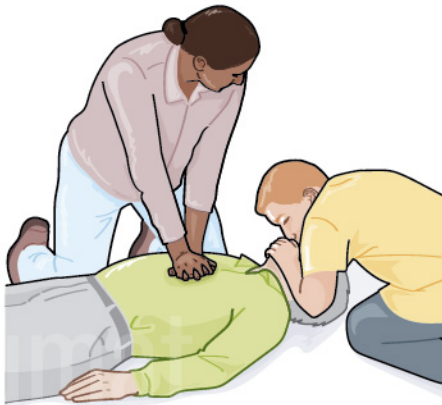
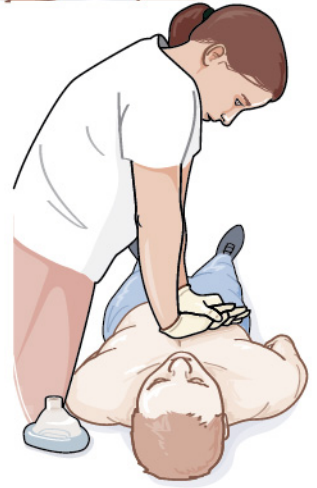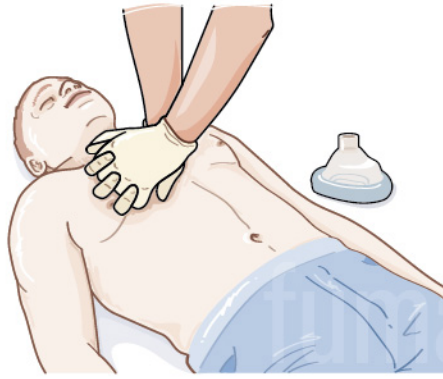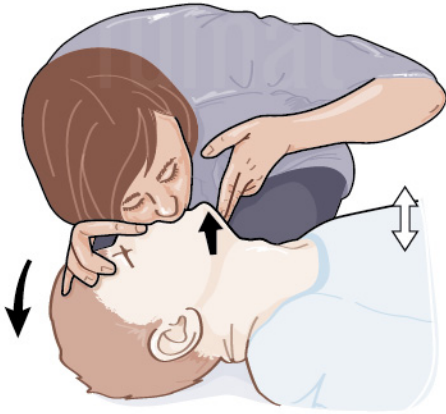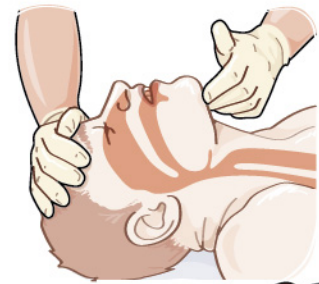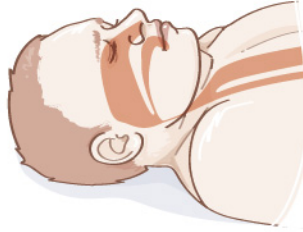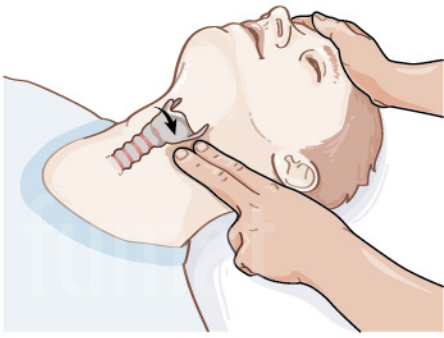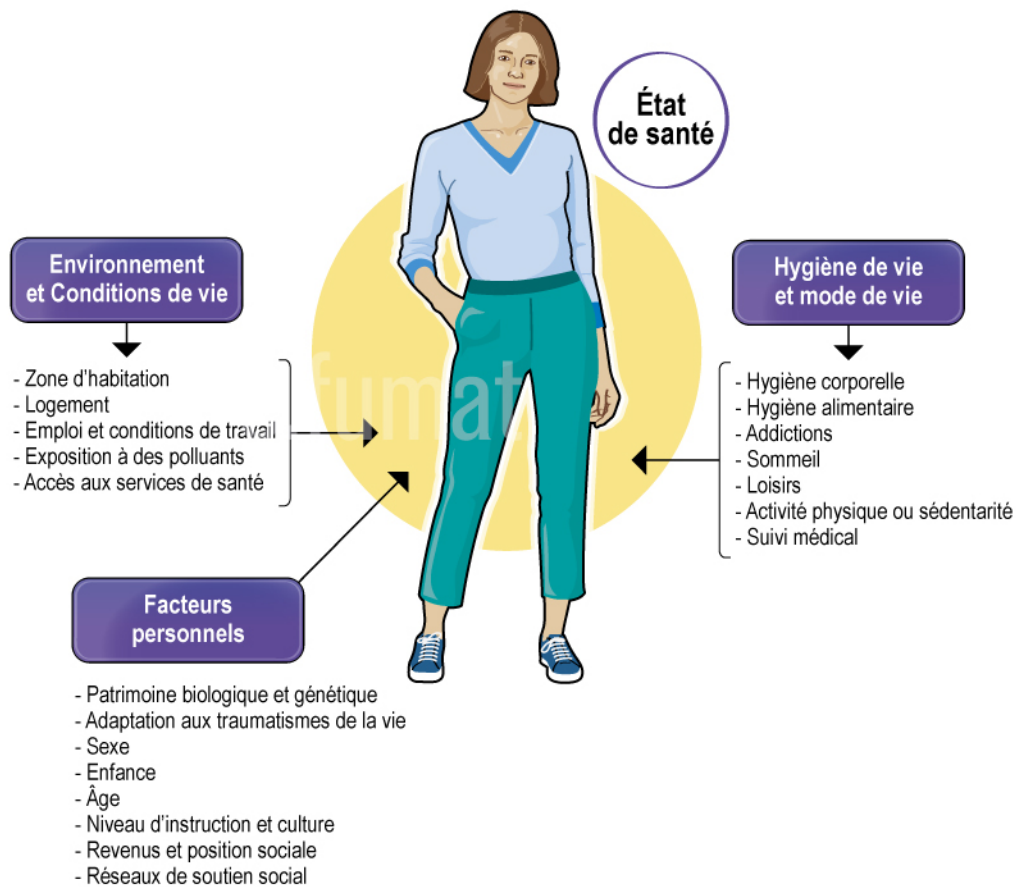




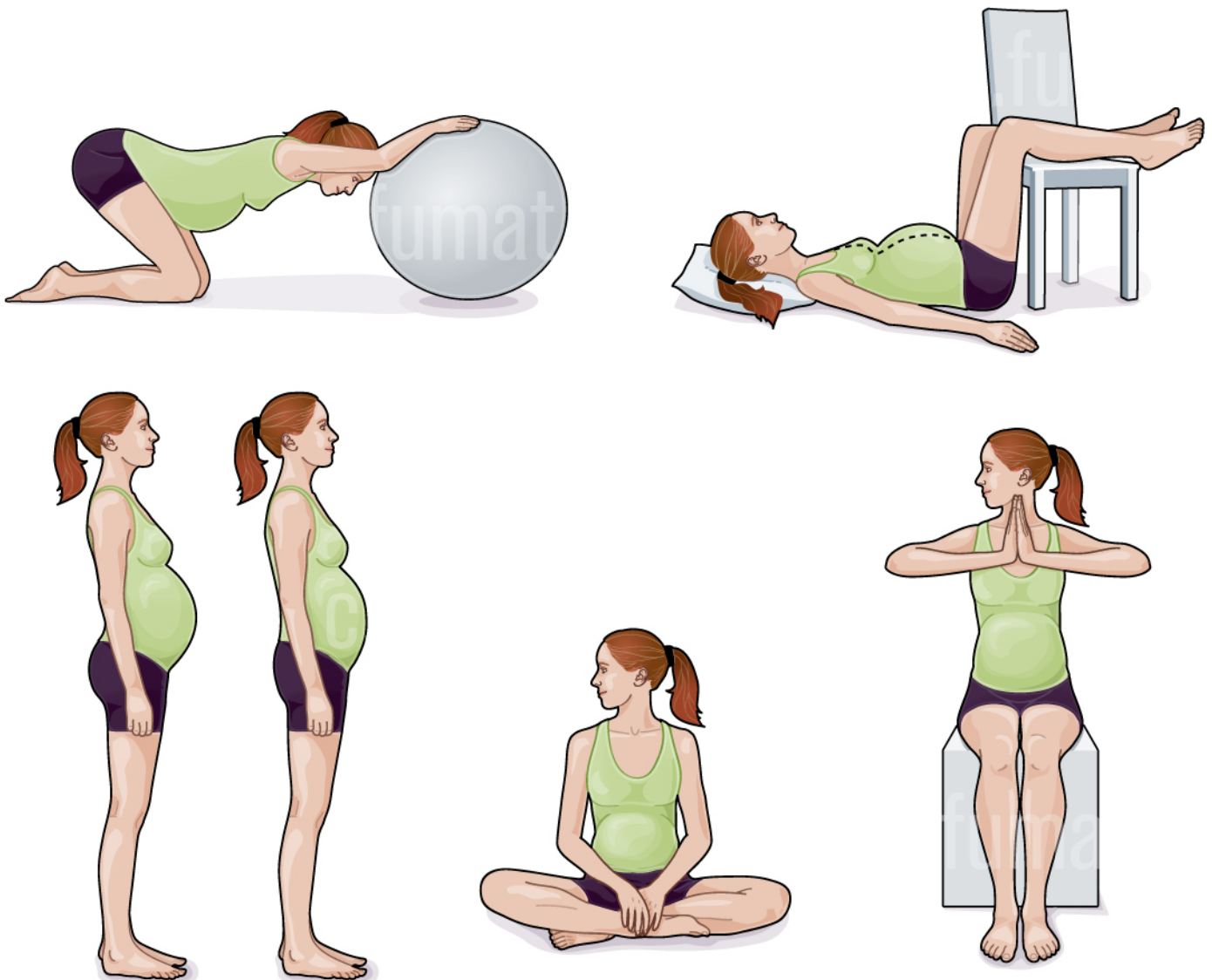





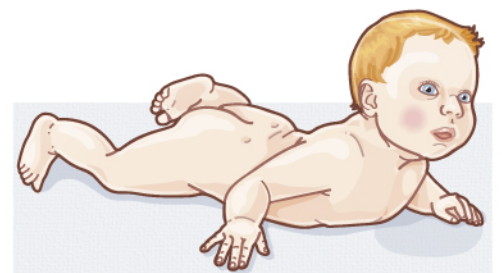
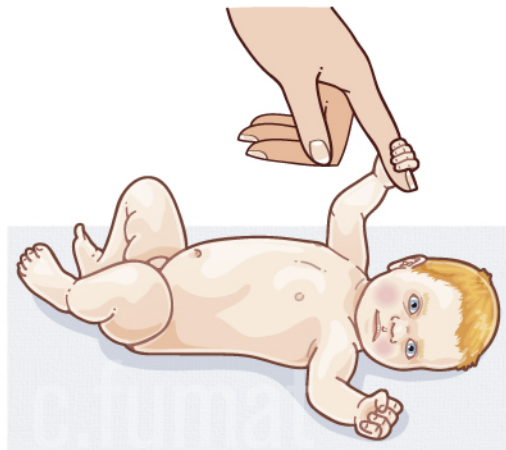
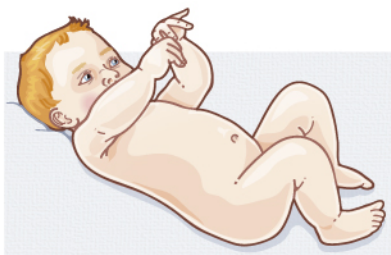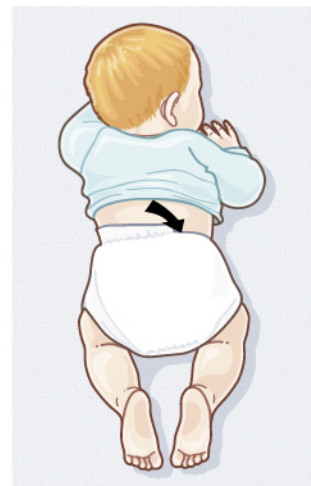




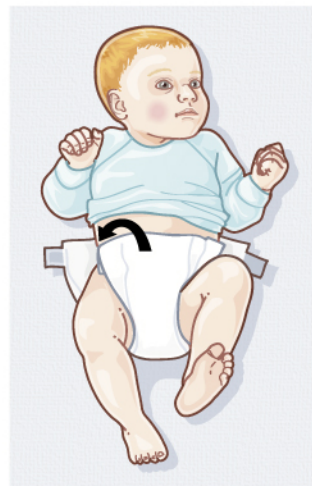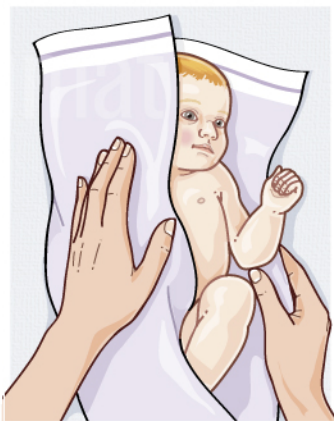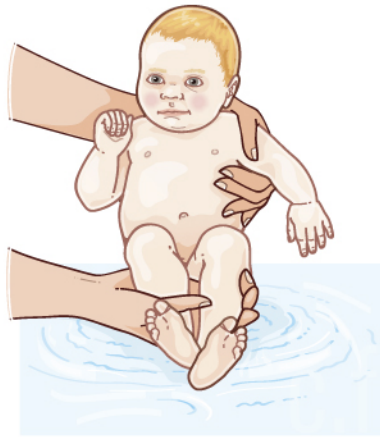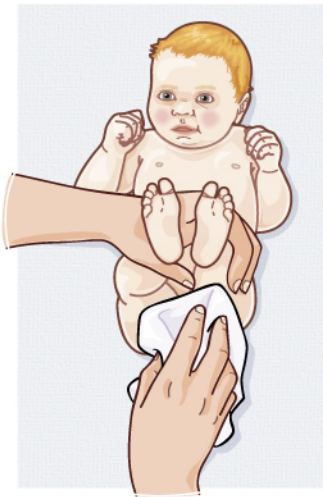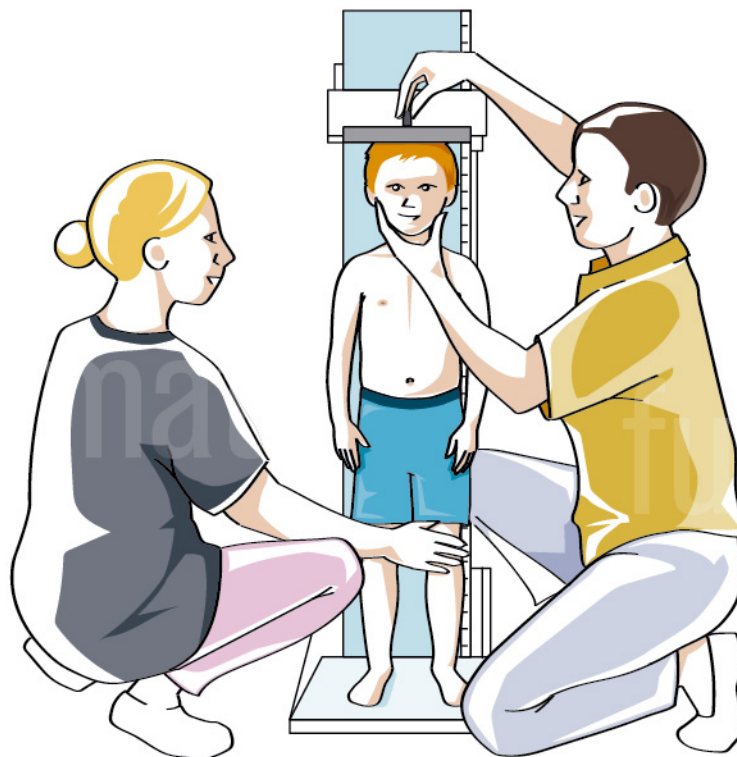
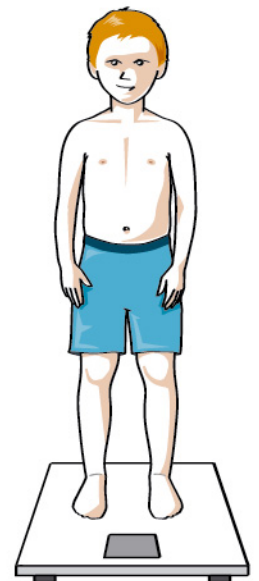
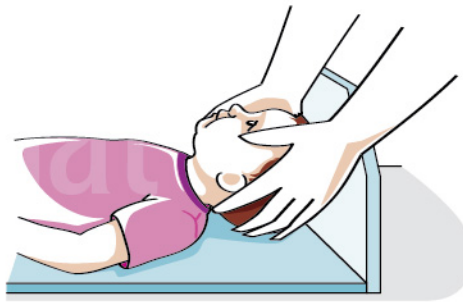

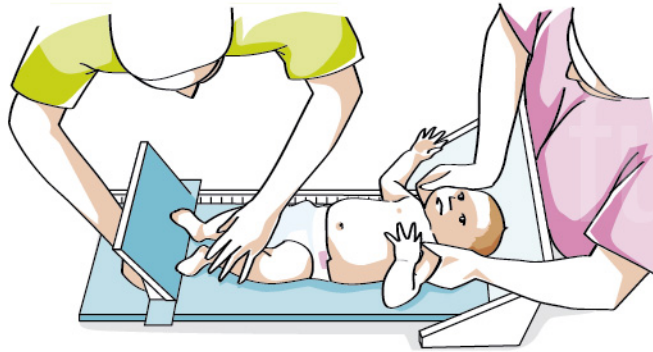Elsevier Masson

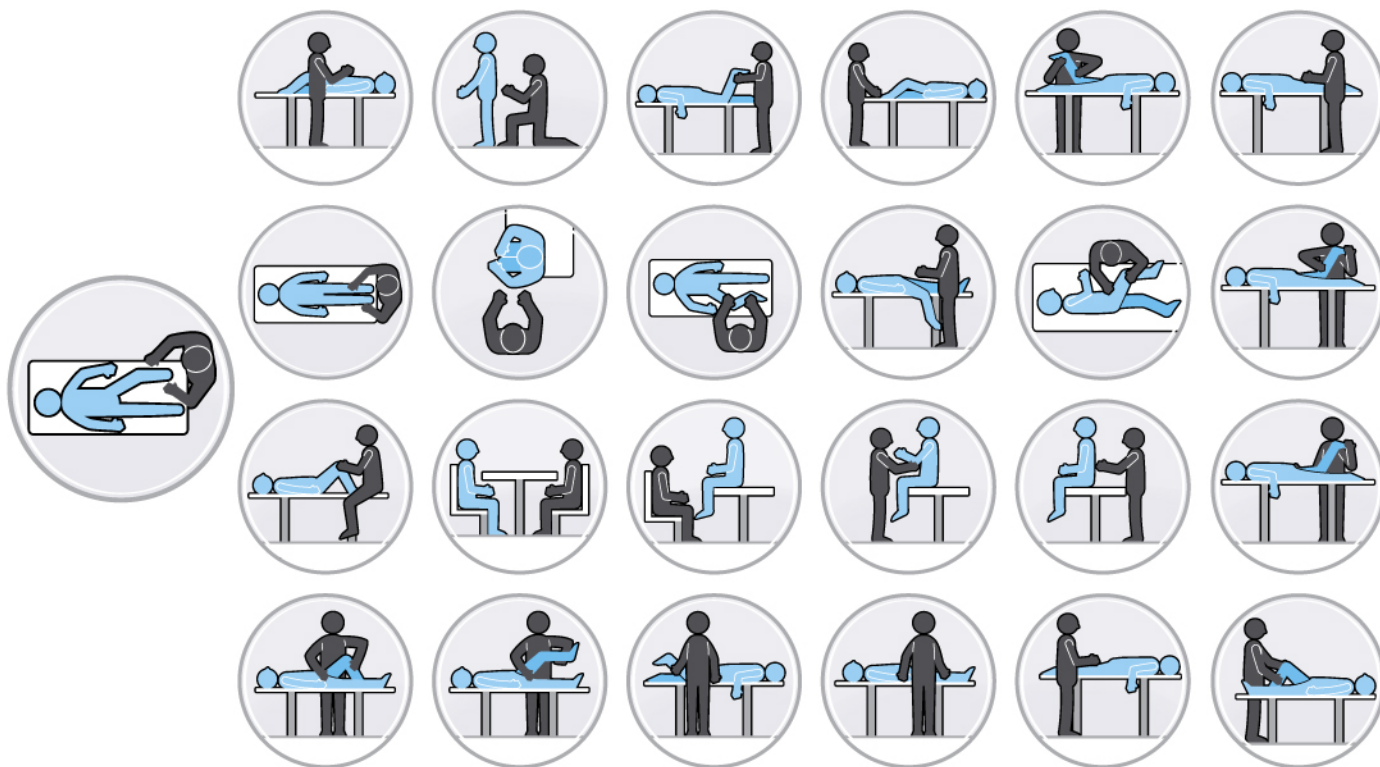

Éditions Horay







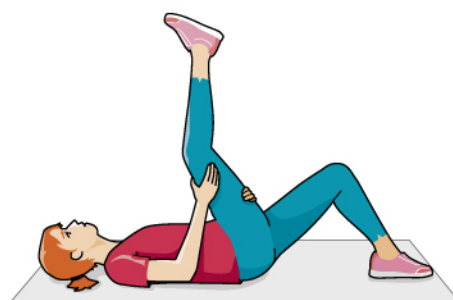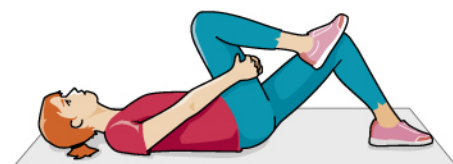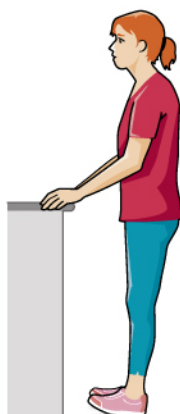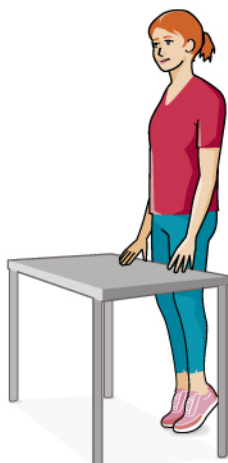

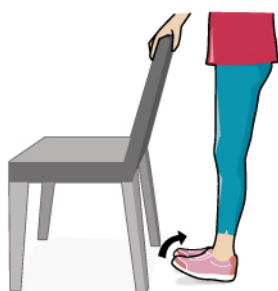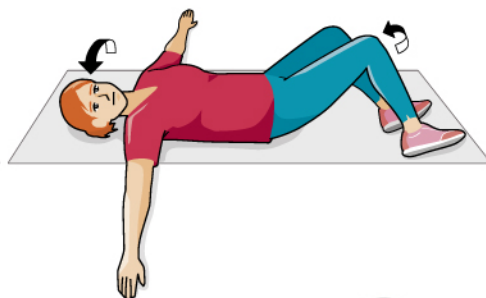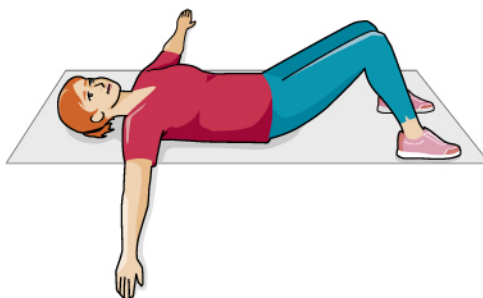
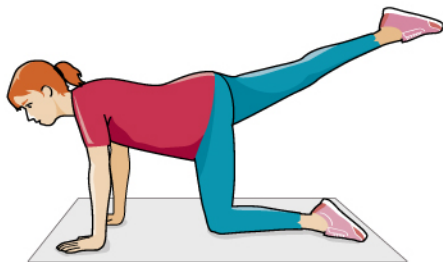
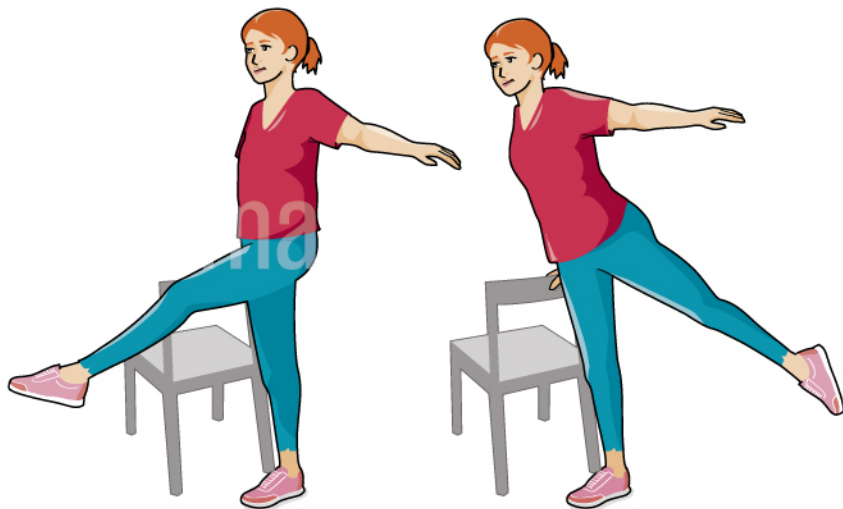


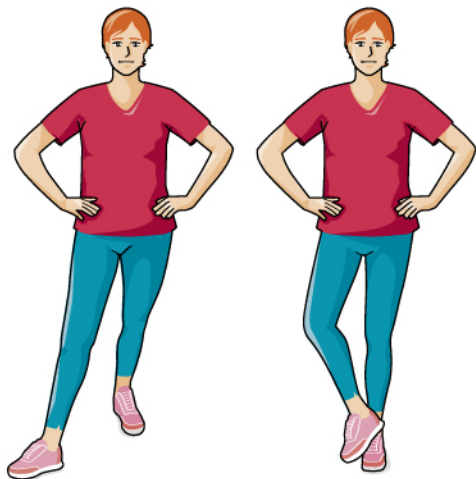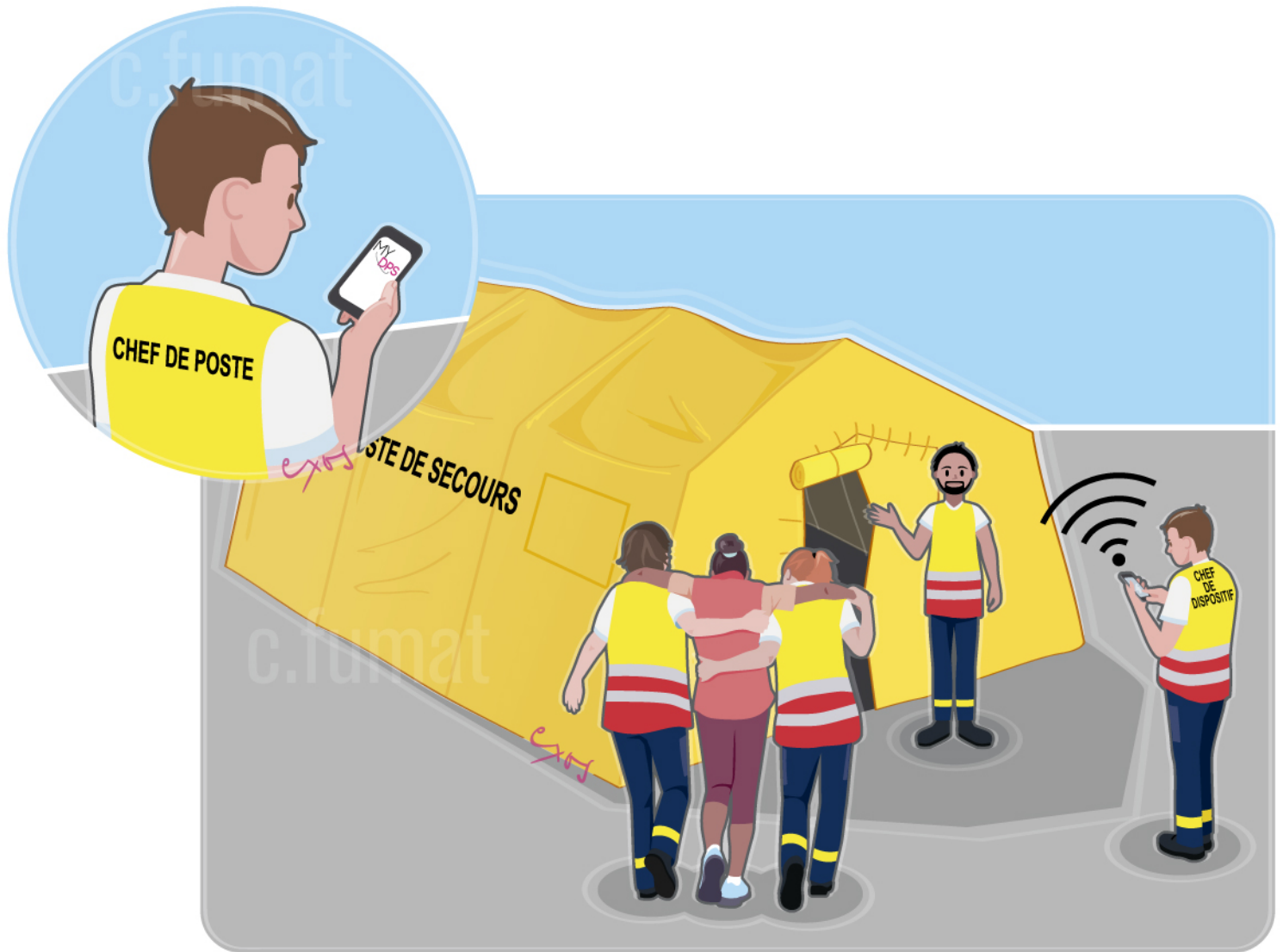Elsevier Masson



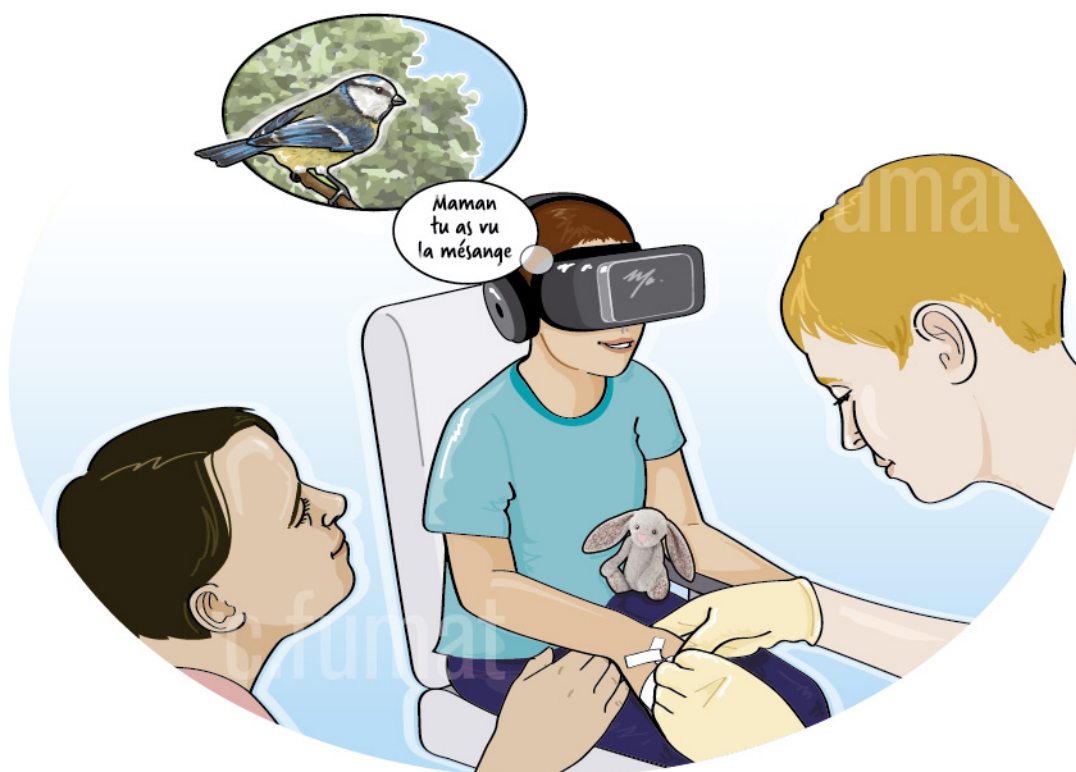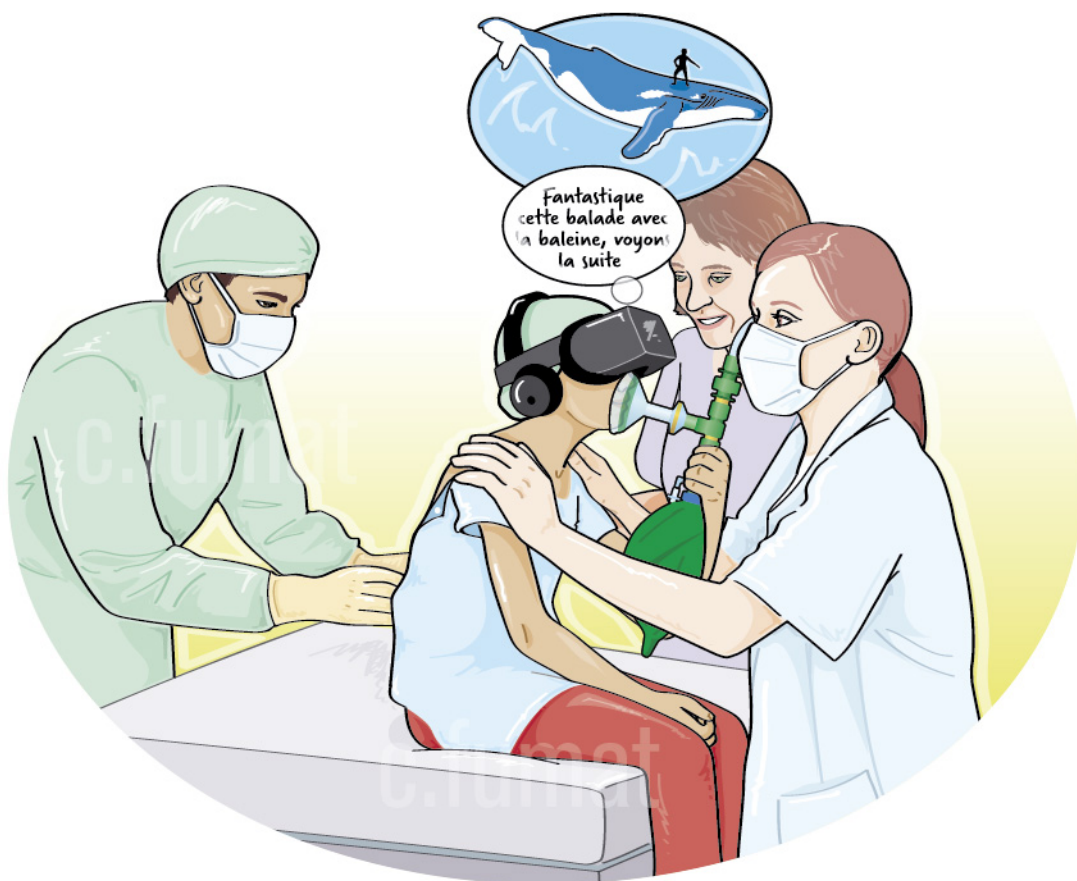Laboratoire pharmaceutique

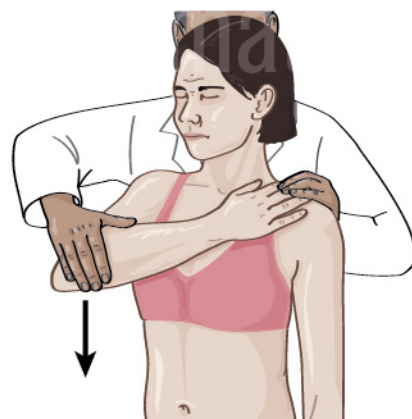
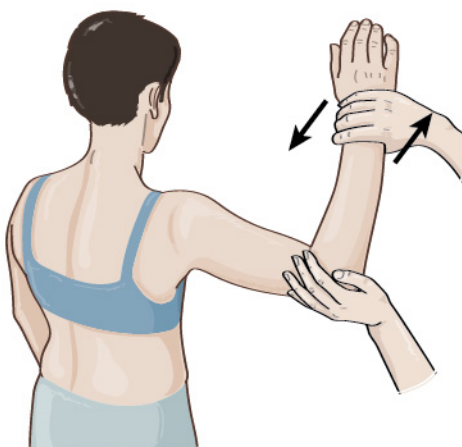
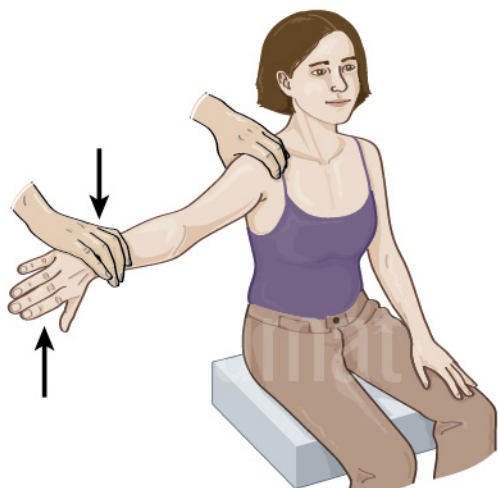
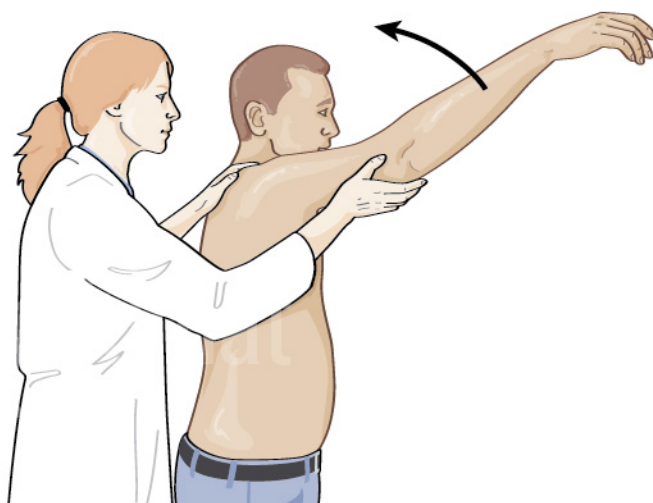
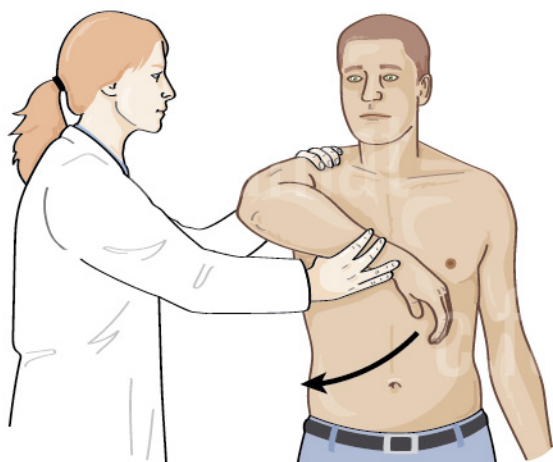
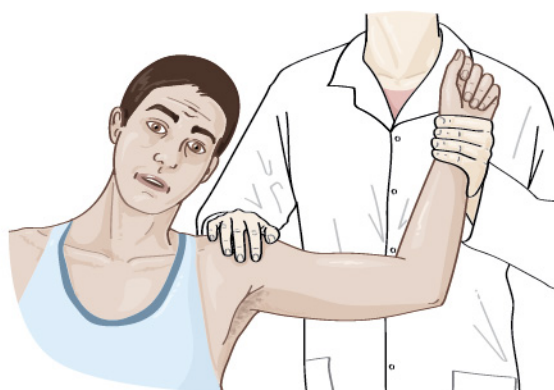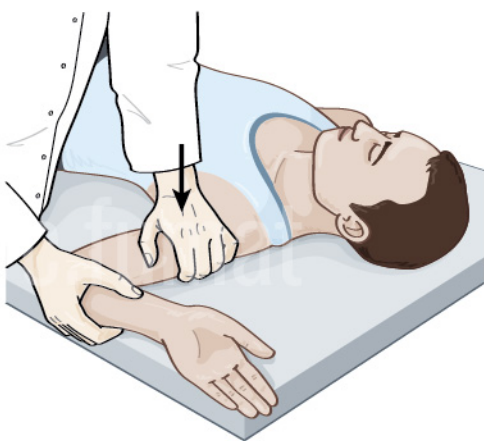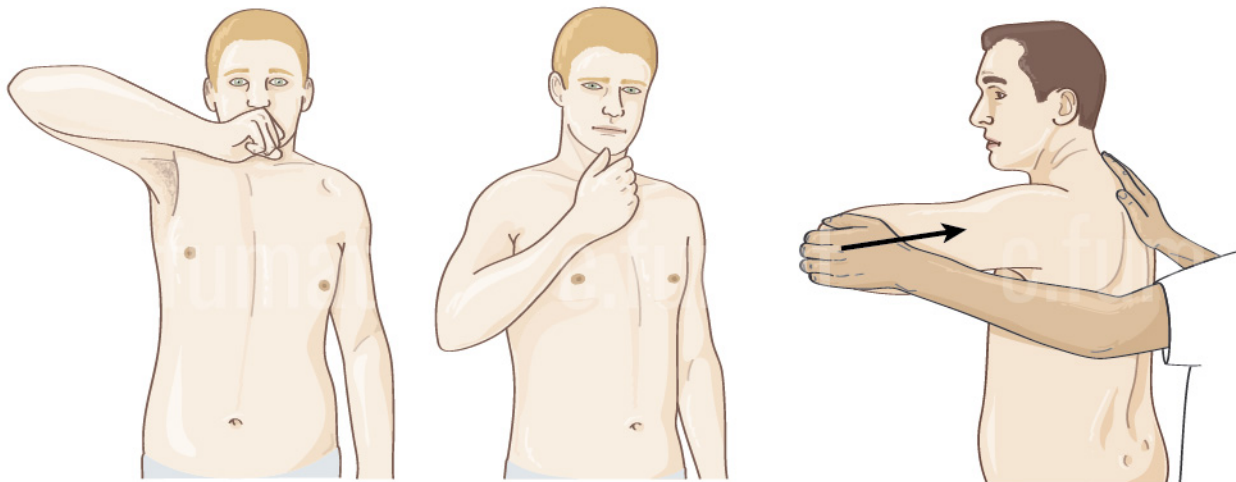





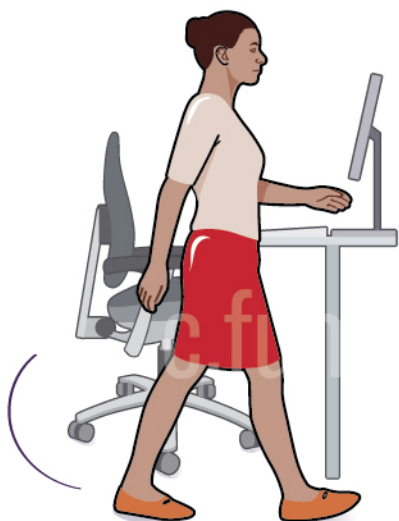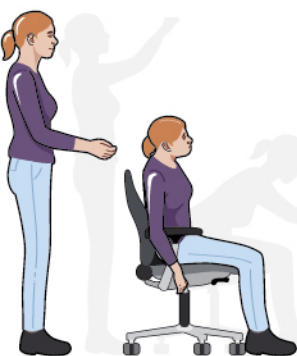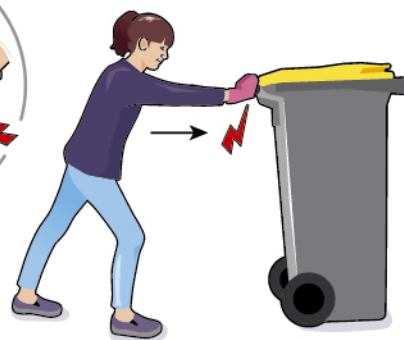
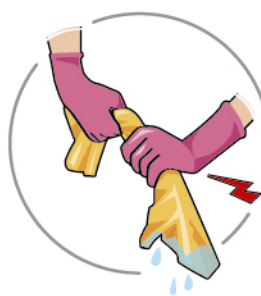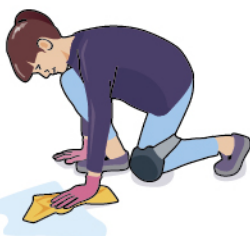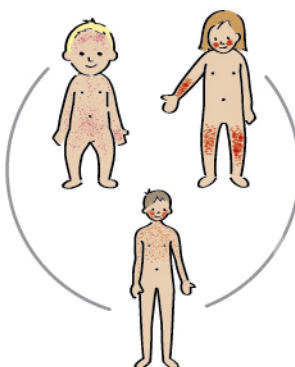
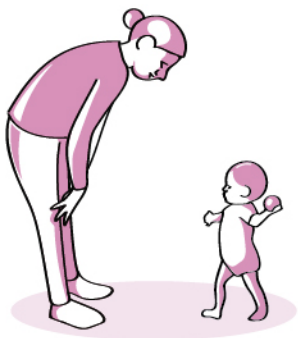
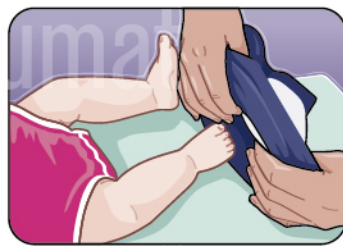
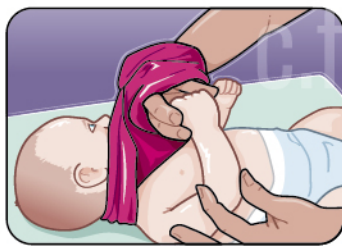
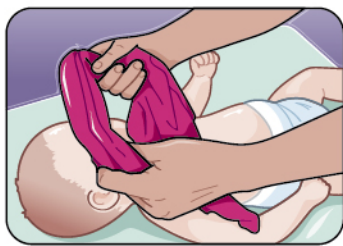





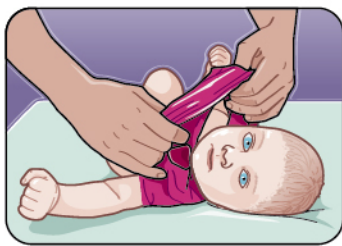





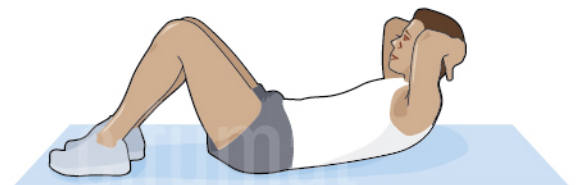
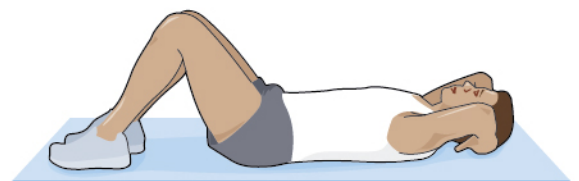
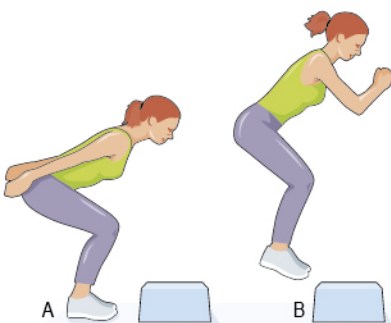
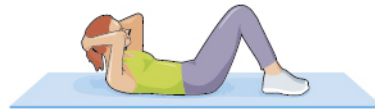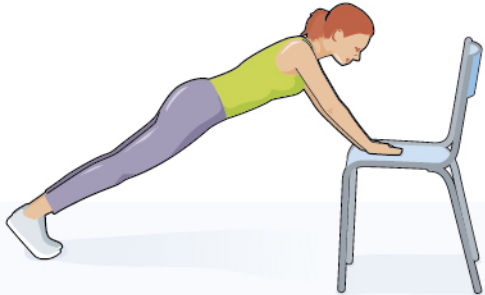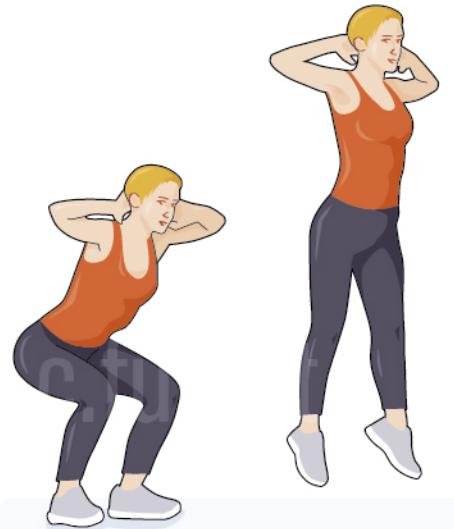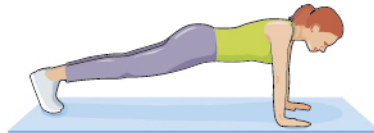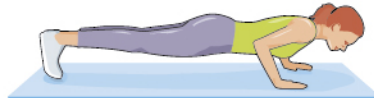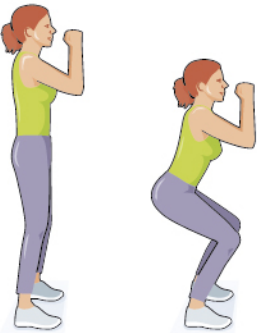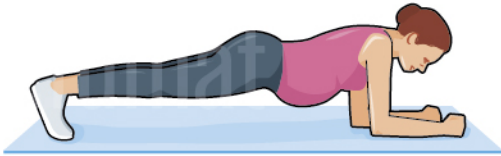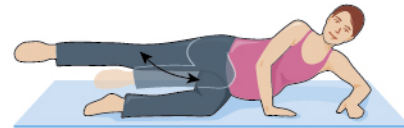
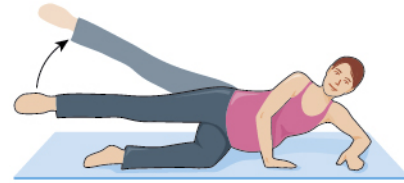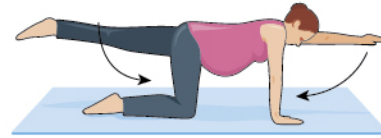

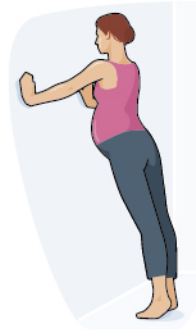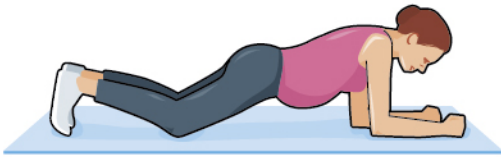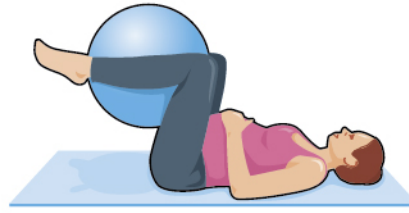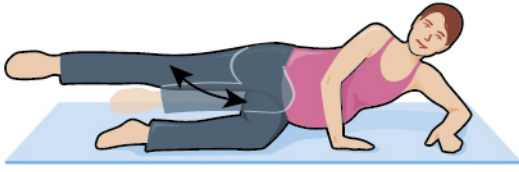




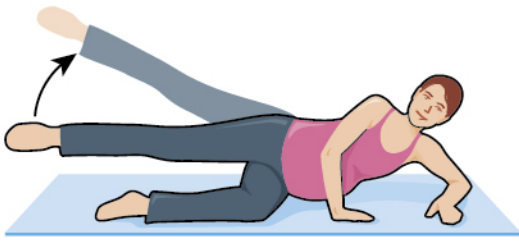Diverses commandes







A

B

C

